

3

Section

CERVICAL SPINE

Fessler RG



Introduction:

3a

ENDOSCOPIC ASSISTED TRANS ORAL ODONTOIDECTOMY

Larry T Khoo MD, Frempong AT MD

3b

ANTERIOR MICROENDOSCOPIC DISCECTOMY AND FUSION FOR THE CERVICAL SPINE

Luiz Pimenta MD, Larry T Khoo MD

1. Introduction:

Minimally invasive spine surgery by means of an endoscopic technique has gained preference with surgeons over the last several years. Initially, the technique was used for lumbar discectomy with the MED™ system (Medtronic®).^(3,4) Nevertheless, with recent improvements in optics and endoscopic equipment (METRx™, Medtronic®), and with surgeons now having greater experience with endoscopy, it has been possible to develop new microendoscopic techniques for other parts of the spine, including the cervical region.^(1, 2, 6, 8)

With the use of the muscle-fiber dilators of the system METRx, in which progressively larger tubes are used to spread muscle fibers without producing lesions, it is possible to now use an endoscopic procedure to treat the cervical spine. This technique causes very little trauma to the paraspinal tissues of the cervical region, which is the portion of the spine that is most mobile and delicate. This technique has been described for discectomy and fusion by an anterior approach, and for a cervical foraminotomy via a posterior approach.^(5,7)

2. Indications

When the patient has a disc hernia or any other cervical pathological process that causes anterior or medial compression of the medulla, with myelopathy or bilateral radicular compression, then discectomy and arthrodesis of the cervical spine via an anterior approach is indicated. For these cases we have developed an intersomatic discectomy and fusion technique with cages and bone inserts by means of an

endoscopic approach, using also the METRx system. With this technique we can apply the principles of minimally invasive surgery to the cervical spine.

3. Surgical Procedures

3.a. Surgical Instruments

To accomplish an anterior video-endoscopic approach to the cervical spine, the following surgical instruments are required:

- 1) Radiotransparent surgical table
- 2) METRx system of tubular dilators with camera and light source
- 3) Video monitor
- 4) Image magnifier
- 5) Micro curettes, Penfield dissectors of different sizes, Kerrison rongeurs ranging from 1 to 3 mm
- 6) Micro drill
- 7) Surgical equipment of endoscopic procedures (Figure 1a, 1b, 1c, 1d, 1e).

3.b. Patient Positioning

Patients are under general anesthesia, and are positioned in a dorsal decubitus position on the surgical table. A roll is placed under the shoulder to extend the neck. Next, the fluoroscope is set in place and used to identify the target disc. The location of the video monitors is important, these should be in front of the surgeon.

3.c. Surgical Technique

The procedure begins with the use of Kirshner wire, which is placed on the skin in conjunction with the fluoroscope to locate the target disc.




Figure 1a, 1b, 1c, 1d, 1e

Along the medial border of the sternocleidomastoid muscle, a 1.8 cm anterior-posterior incision is made.

After making the incision, a careful subcutaneous incision/dissection is done exposing the platysma and the superficial fascia, which is then opened 1.5 cm longitudinally.

With help of the index finger, a roma dissection of the layers of the cervical region is done in such a way that the vascular-nervous bundle (easily identified by tactile feel) remains lateral, while the esophagus and trachea remain medial. Dilators are then placed through this opening following the length of the index finger, which is already in the neck, until the last METRx retractor is correctly positioned at the disc level that is to be operated. The entirety of this procedure is confirmed through fluoroscopy (Figure 2a, 2b).

Because this region is less muscular than the posterior cervical and lumbar regions, the retractors can be easily moved, potentially resulting in their displacement relative to the disc space that is being operated. For this reason, fluoroscopic imaging is used frequently to verify the positioning of the instrumentation.

The canal through which the procedure is being done is cleaned, and optics are introduced to visualize the disc space after retraction of the *longus colli* muscle. A bistoury is used to open the anulus fibrosus, and with pituitary rongeurs, the disc is removed.

It is important to use a micro drill to remove the osteophytes and the posterior longitudinal ligament that may be calcified. The decompression continues until visualization of the dural sack and liberation of the foraminae, a process that should be monitored by the fluoroscope (Figure 3a, 3b).

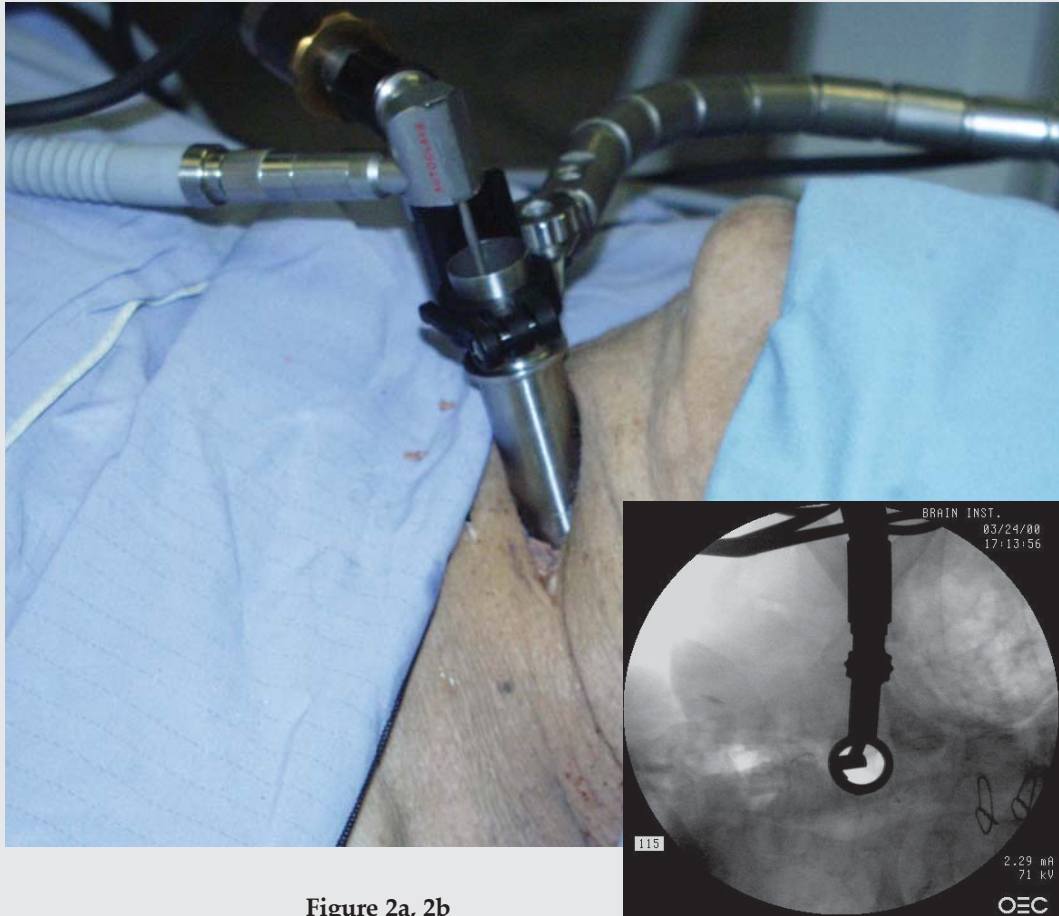


Figure 2a, 2b

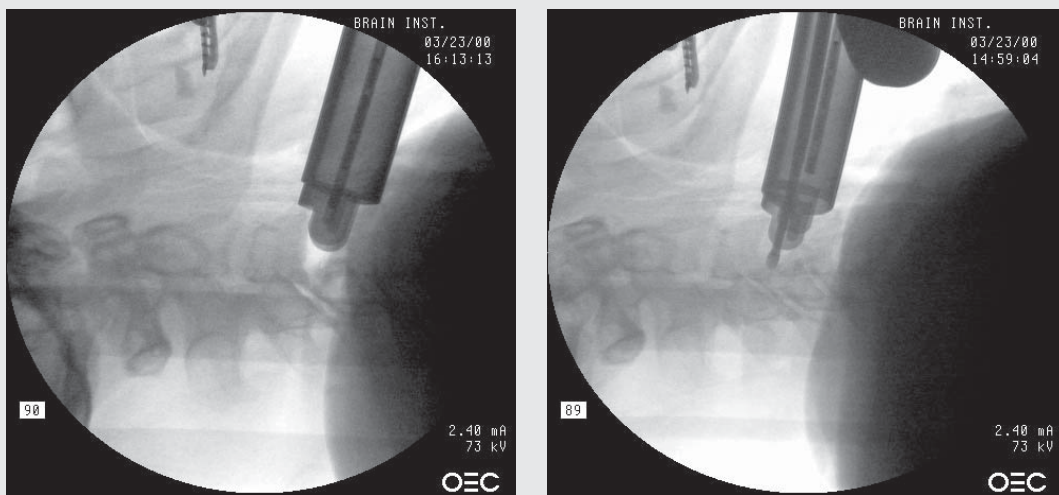


Figure 3a, 3b

After decompression, one or two cages are placed in the disc space, and filled with bone chips from the iliac crest (Figure 4). Anterior plating may be used

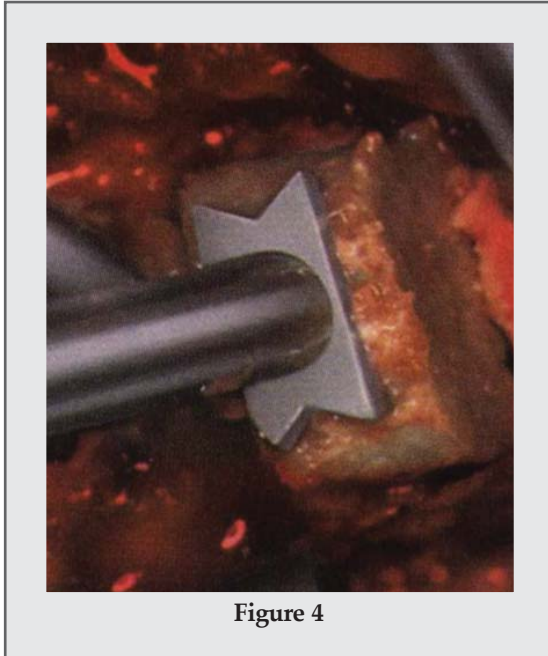


Figure 4

over the bone graft (Figure 5a, 5b, 5c). Threaded trapezoidal cages should be used to preserve lordosis in the cervical spine and help maintain contact between the cages and the endplates (Figure 6a, 6b, 6c, 6d).

3.c. Closure

After retracting the METRx tubes, confirm that the muscular layers and aponeurotic tissues return to their original position, without bleeding or lesions. A continuous monocryl suture is used to close the platysma. Either single stitches or one continuous intradermal suture can be used in conjunction with steri-strips or skin glue such as Dermabond.

3.d. Technical Aspects

- 1) The skin incision should be guided by the fluoroscope since the inclination of the tubes should be the same as that of the disc.
- 2) A good retraction of the *longus colli* muscles, with a monopolar bistoury, should be done before beginning the discectomy.
- 3) The extraction of the disc material is more efficient with a high rotation drill, oriented by a ra-

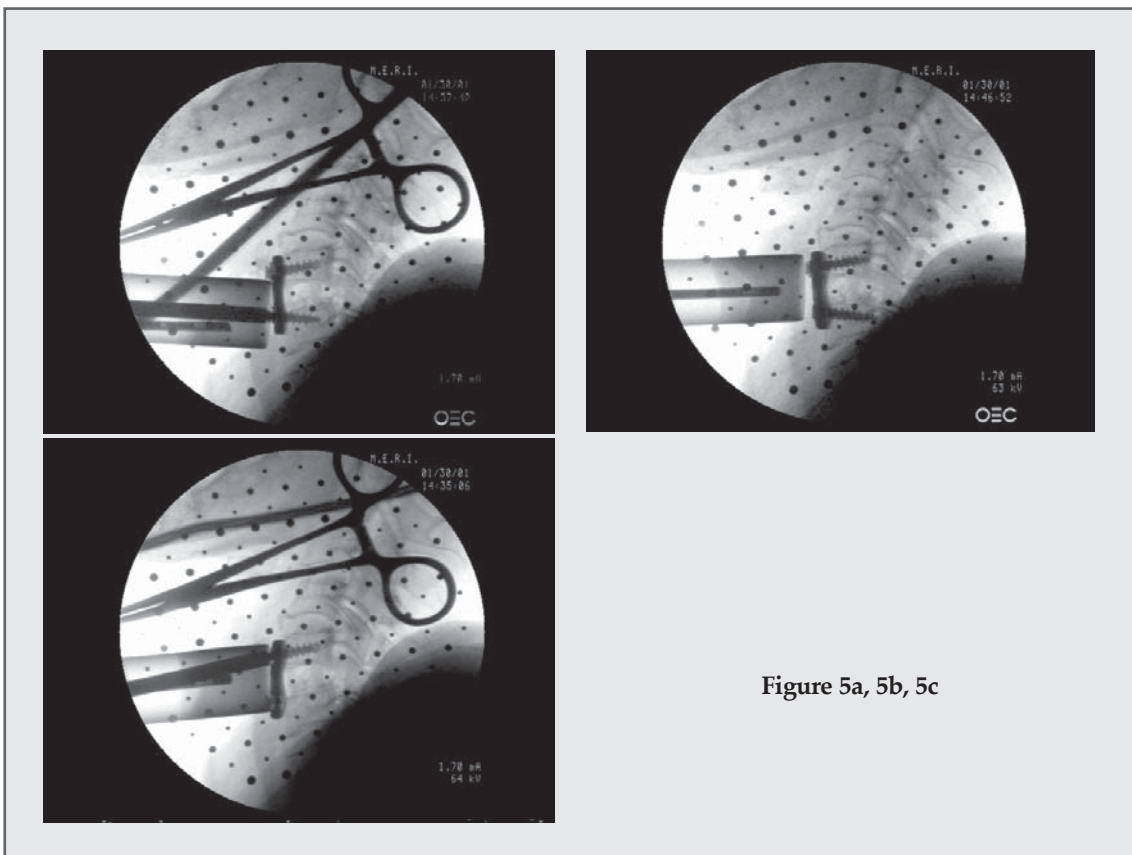


Figure 5a, 5b, 5c



Figure 6a, 6b, 6c, 6d.

diroscope and with some type of microendoscopic visualization.

- 4) Harvest of iliac bone should be done by a minimally invasive procedure through small 0.5 mm openings.
- 5) When implanting two cages, the first cage is partially inserted in the disc, and is not completely inserted until the second cage is introduced. Both are implanted in such a way that their treads mesh together to maximize stability.
- 6) Presently, we are developing a cervical plate for introduction by endoscopic means, but at this point we have no clinical experience with these.

4. Avoiding Complications

The patient should undergo a full cardiovascular evaluation, since in this surgery there is manipulation of the carotid arteries and complications are possible. It is specially necessary in patients with carotid pathologies, (soplo) due to the possibility of embolism that may be brought about the manipulation of the vessels. For these we use eco Doppler.

Always respect the lateral margins of the discectomy to prevent lesion of the vertebral arteries, and though not common, always be on the lookout for anatomical anomalies, which may visible in a pre-operative tomography.

When dissecting through the posterior longitudinal ligament, it should be done with a 1 mm Kerrison rongeur to avoid possible damage to the dura, and when treating patients with myelopathy, manipulate more delicately the posterior region, since tissues can adhere to the medulla and may result in a lesion to the dura mater. Incases with lesions to a vein, begin hemostasis using biological substances such as gelfoam.

5. Clinical Experiences

Between July 1999 and April of 2002, 42 patients where treated with this technique, and a total of 51 discs were accessed. The disc most frequently operated was C5-C6 (26 patients, 51%), followed by C4-C5 (12 patients, 6%), C6-C7; (10 patients; 19.6%) and C3-C4 (4 patients; 7.8%). In 33 patients only one disc level was operated (78.6%), and in 9 patients two levels were operated (21.4%). In 62.8% of the levels, 2

threaded titanium cages were implanted for fusion. In the remaining 37.2% of discs, only 1 cage was implanted due to the disc size.

In the first 36 patients with more than six months post-operative follow-up, bone fusion occurred on 83.3% of the cases. Within 30 days after the procedure, 75% of the patients returned to work. Each surgical procedure took approximately 2 hours. The patients were discharged on the same day, without the need for pain medication or cervical collars. Compared to the traditional method of microsurgery, we had fewer lesions of the paraspinal structures and immediately better post-operative results.

6. Conclusions

This technique is more complex than the standard endoscopic procedure for cervical foraminotomy, and is also less invasive than a lumbar microendoscopic discectomy. It needs a steeper learning curve to the surgeon. Recent improvements in optic systems for endoscopes and new retractors will make this technique easier. The anterior access requires more fluoroscopy than the other endoscopic approaches. It is a minimally invasive technique, which allows discectomy, removal of osteophytes, and fusion at the degenerated disc level. It offers quicker postoperative recuperation with less pain, in such a way that it diminishes the hospital stay and the amount of analgesic medication that must be prescribed. Patients also return to work more quickly. Since the size of the incision is small, it yields good aesthetic results. We just now started the implantation of the Link-Charité cervical disc for non-fusion technique through this endoscopic technique. We are also on the way with the anterior plates under this procedure.

7. References:

1. Adamson T, Broome RN. Initial Experience with endoscopic posterior cervical laminoforaminotomy for the treatment of cervical radiculopathy (abstract). Sixth Annual International course on Total Spine, paper 38, February 2000.
2. Fessler RG. Personal Communication
3. Folley K, Smith MM. Microendoscopic discectomy. *Techniq Neurosurg.* 3: 301-7, 1997.
4. Folley K, Smith MM. Microendoscopic discectomy(MED): surgical technique and initial clinical results (abstract). Presented at the North American Spine Society 12th Annual Meeting, New York, 1997.
5. Pimenta LH. Endoscopic approach to the cervical spine. *Spineuniverse* (Web Publication). 2001.
6. Pimenta LHM. Microendoscopic cervical foraminotomy (abstract). IV International Congress on Minimally Invasive Neurosurgery. Barcelona, Spain. *Minim Invas Neurosurg.* 42, 1999.
7. Pimenta LH, Prandini MN, Tella OI. Endoscopic approach to the cervical spine. 7th World Congress of Endoscopic Surgery, Singapore, June, 2000.
8. Roh SW, Kim DH, Cardoso AC. Endoscopic foraminotomy using a microendoscopic discectomy system in cadaveric specimens. *Neurosurg Focus.* 4(2): Article 2, 1998.

3c

POSTERIOR CERVICAL MICROENDOSCOPIC DISCECTOMY AND LAMINOFORAMINOTOMY

Larry T Khoo MD, Murat Cosar MD PhD

25

Minimally Invasive Procedures In Spine Surgery

1. Introduction:

Posterolateral cervical foraminotomy was commonplace for many years in treatment of cervical disc herniations and foraminal stenosis^(1,2) until the description of anterior approaches to the cervical spine^(3,4). By the time, the anterior approaches have come popular because of safer and easier to perform. The patients had less muscle spasm and postoperative pain as compared to open posterior cervical foraminotomy. However, these anterior approach techniques carried additional disadvantages such as increased risk of injury to the trachea, esophagus, carotid artery, and recurrent laryngeal nerve⁽⁵⁻⁸⁾. Additionally, anterior decompression generally necessitates fusion at that level thereby resulting in an unavoidable loss of mobility and increased risk of adjacent level degenerative changes over time^(9,10).

Posterior approach via a “key hole” type osteotomy may provide better exposure for decompression of the exiting root and for removal of lateral osteophytes and discs^(6,11,12). Generally, less than 50% of the facets are removed, and rests of facets are enough to sheer the biomechanical strength of the cervical spine^(6,13). Previous literatures have also documented that adequate foraminal exposure can be accomplished without necessarily destroying the facet joint or causing iatrogenic instability with posterior cervical laminoforaminotomy. So, the posterior approach treats the offending pathology without necessitating a fusion process^(6,14,15). Additionally, the risks of injury to the anterior structures of the neck including the trachea, esophagus, thyroid, thymus, carotid arteries, jugular veins, vagus nerve, recurrent laryngeal nerve, superior laryngeal nerve, ansa

cervicalis, and thoracic duct are avoided with posterior approach⁽⁶⁾. The limited surgical view, difficulty in resecting osteophytes, limited visualization of the distal foramen, excessive blood loss via epidural veins, increased post-operative muscle spasm, neck pain, and recovery time were the disadvantages of the posterior approaches^(6,16,17).

The recent developments in surgical technologies have allowed the surgeons to revisit the posterior cervical approaches again. The new developments in surgical techniques such as atraumatic tissue dilation, endoscopic visualization, improved neuroanesthetic techniques, and improved non-invasive imaging modalities have repopularized the posterior cervical approaches again. The posterior cervical microendoscopic laminoforaminotomy (MELF) operation is the synthesis of old and new surgical techniques. MELF techniques through a minimally invasive approach combine with significant reductions in operative blood loss and postoperative disability. This novel technique also preserves the spinal motion segment while avoiding fusion. Additionally, this MELF technique results in a shortened operation time, hospital stay and an improved post-operative recovery time as compared to open techniques⁽⁶⁾. Beside the cervical stenosis, cervical lateral soft disc herniations can be comfortably extricated with MELF⁽¹⁴⁾.

We think that MELF is the modern view of the posterior procedures with a minimally invasive approach and high-magnification direct endoscopic visualization. Additionally, it is a safe, reasonable, and efficacious alternative to anterior surgical procedures for posterolateral cervical stenosis and soft lateral disc herniations. It can accomplish the direct decompression of the stenotic foramen and nerve root with a minimum risk of injury to the visceral and neurovas-

cular structures as compared to anterior approaches ⁽⁶⁾.

2. Indications:

MELF can be used for primarily cases of posterolateral disc herniation, osteophyte compression, focal lateral thickening of the ligamentum flavum, facet thickening and arthropathy. It can be used for the cases with mild to moderate kyphosis so long as there is no evidence of instability. However, for these patients, particular caution must be taken to not resect too much of the medial facet complex during the decompression ⁽⁶⁾.

The appropriate radiographic finding (MRI, CT and etc.) with a good clinic history of radiculopathy may be supported with EMG to increase the successful of MELF and to avoid from the other differential diagnosis such as spinal canal tumors, trauma, inflammatory diseases, toxic and allergic conditions, hemorrhage, congenital defects, metabolic diseases, neuropathies, thoracic outlet syndrome, rotator cuff pathology, impingement syndromes, bursitis, arthritis of the shoulder, and bicipital tendonitis ⁽⁶⁾.

3. Contraindications:

For cases, of myelopathy, central or paracentral stenosis, deformity, or instability, the laminoforaminotomy technique is not the ideal procedure ⁽⁶⁾.

4. Surgical Procedures:

4.a. Surgical Equipment:

Draped C-arm fluoroscopy and monitor are essential for verifying the position and localization of the cervical level of MELF. The operating table must be suitable for sitting position. Additionally, high speed drill, operating microscope and posterior cervical minimal invasive surgery instruments are essential for the MELF procedure (Figure 1a, 1b, 1c).

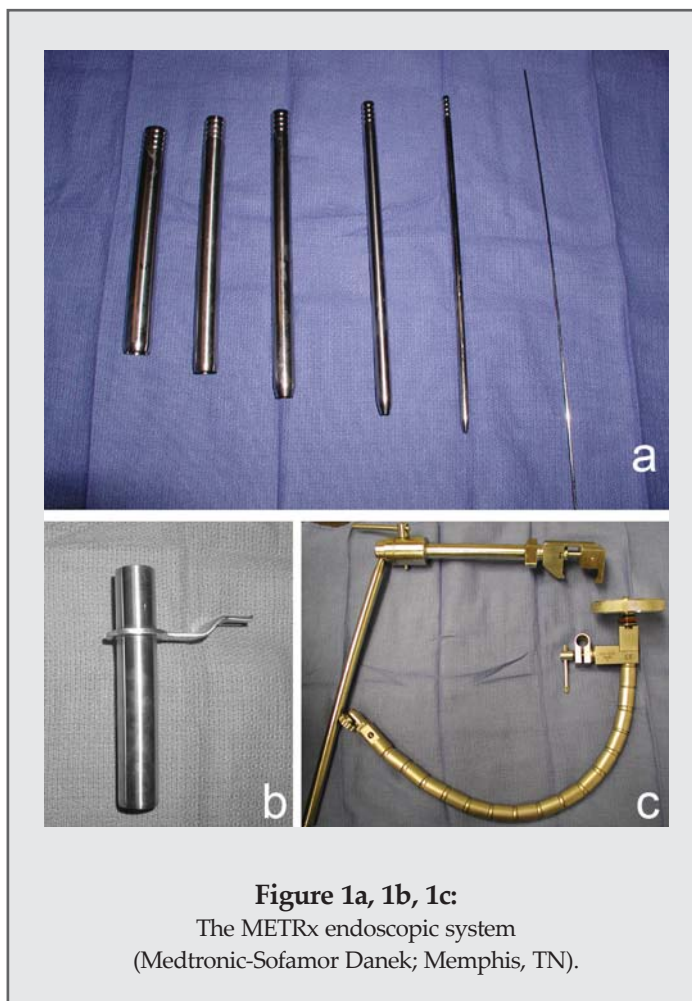


Figure 1a, 1b, 1c:
The METRx endoscopic system
(Medtronic-Sofamor Danek; Memphis, TN).

It will be better to use precordial Doppler monitoring and central venous pressure (CVP) catheter placed into the right atrium in anticipation of blood loss and possible venous air embolus. Additionally, intraoperative somatosensory evoked-potential monitoring of the operated dermatome and electromyographic recordings (EMGs) can also be used to assess the spinal cord and involved root integrity.

4.b. Operating Room Set-up:

The sitting position of the patient is generally preferred for MELF procedure. The C-arm and monitor is placed according to the localization of the surgeon. The surgeon generally stands directly behind the neck of the patient and a standard set up for posterior cervical surgery is used with the spine surgeon standing on the left or right side of the patient with a operation technician and a surgical assistant. It will be better if the video and C-arm monitors are placed on the opposite side of the operation area.

4.c. Patient Positioning:

After the patient was brought to the operation room, appropriate pre-operative evaluation was performed following the induction of general anesthesia. Then, the patient is brought to the sitting position on the operating table. The head of the patient is immobilized with Mayfield headrest without bending to right or left side in a semi-flexion position. The level of the MELF is signed with the C-arm before medical clearance and sterile covering.

The choice of the prone position with a Jackson or four-poster frame is left to the surgeon's individ-

ual preference. For the purpose of this text however, the sitting position will be assumed (Figure 2).

4.d. Surgical Technique:

After the determination of pathology level under C-arm, 0.5 cm length stab incision was made 1 cm off midline ipsilateral to the pathology. And then, a thin Steinman pin is inserted to the facet or lateral mass of the target level through the posterior cervical musculature and fascia. It is better to err laterally during this docking maneuver to avoid inadvertent dural penetration. At this moment, the antero-posterior radiographic images can be obtained to guar-

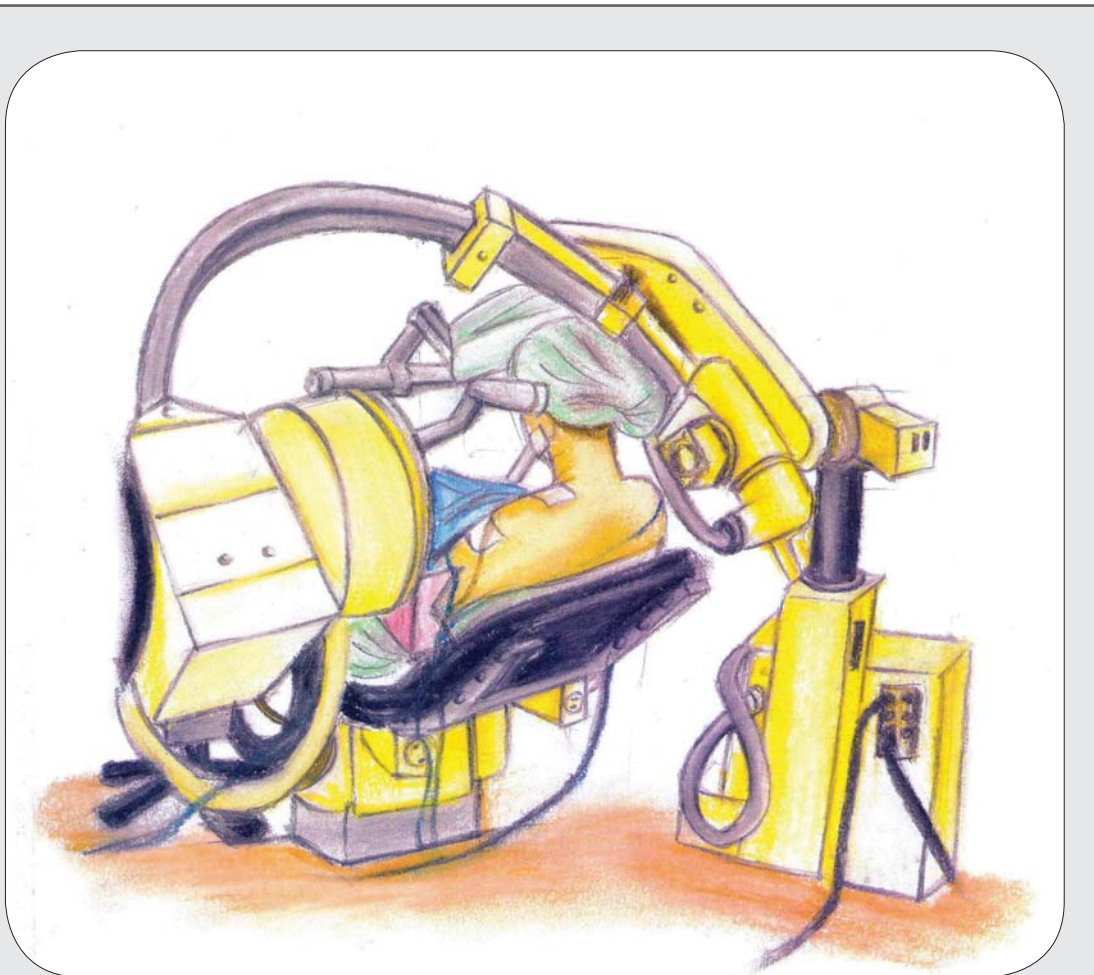


Figure 2:

The patient is positioned in the semi-sitting position with the head secured in a Mayfield headrest. The fluoroscopic C-arm is placed such that lateral images can be easily obtained throughout the procedure.

antee proper pin positioning. After the guidewire is docked on the facet, the skin incision is extended for a total length of approximately 2.0 cm. The cervical fascia is incised with maximum care to bleeding after the retraction of the skin edges. So, the cervical fascia allow to the sequential dilating cannulas with a minimum of force.

The series of dilators are then sequentially inserted over the Steinman pin until an 18mm tubular retractor is inserted (Figure 3a-d). After the insertion of final 18mm tubular retractor, the working channel (tubular retractor) is attached to a flexible retractor. This flexible retractor is affixed to the operating table side-rail and locked in position at the junction of the lamina and lateral mass. After this process, the endoscope is fixed to the tubular retractor via a circular plastic friction couple. We prefer the METRx system (Medtronic Sofamor-Danek; Memphis, TN) of endoscopic retractors, camera, and instruments

for our MEF procedures. Cervical modifications of this system have been made for cervical MELF procedure after its initial designs for lumbar discectomy. The endoscopic camera with high resolutions and smaller profile dissectors and Kerrisons make this system as better selection for cervical spine.

A bovie cautery with a long tip is used to remove the remaining muscle and soft-tissue overlying the lateral mass and facet, after the tubular retractor is set in the desired position. It is best to begin this dissection laterally and continue to medially to expose the laminofacet junction with attention paid to not slip into the interlaminar space at this point.

Because of the ligamentum flavum is thin or absent at the lateral edge of the interlaminar space, the dura and spinal cord have higher risk. After the well visualization of the bone, the inferior edge of the superior lamina and the medial edge of the lateral mass-facet complex is scraped with a small straight

endoscopic curette and extended underneath the lamina and facet with the use of a small angled endoscopic curette (Figure 4a). The angled endoscopic curette facilitates to free the soft tissue from its periosteal attachment extending under the lamina. The placement of the curettes can be confirmed with fluoroscopy (Figure 4b). The careful dissection of the soft tissues from the bone structures may prevent the incidental dural tears. Bleeding from epidural veins, edge of the flavum edge of the lamina is controlled via a long tipped and/or angled endoscopic bipolar cautery. After this processes, a small angled endoscopic 1 or 2 mm Kerrison rongeur

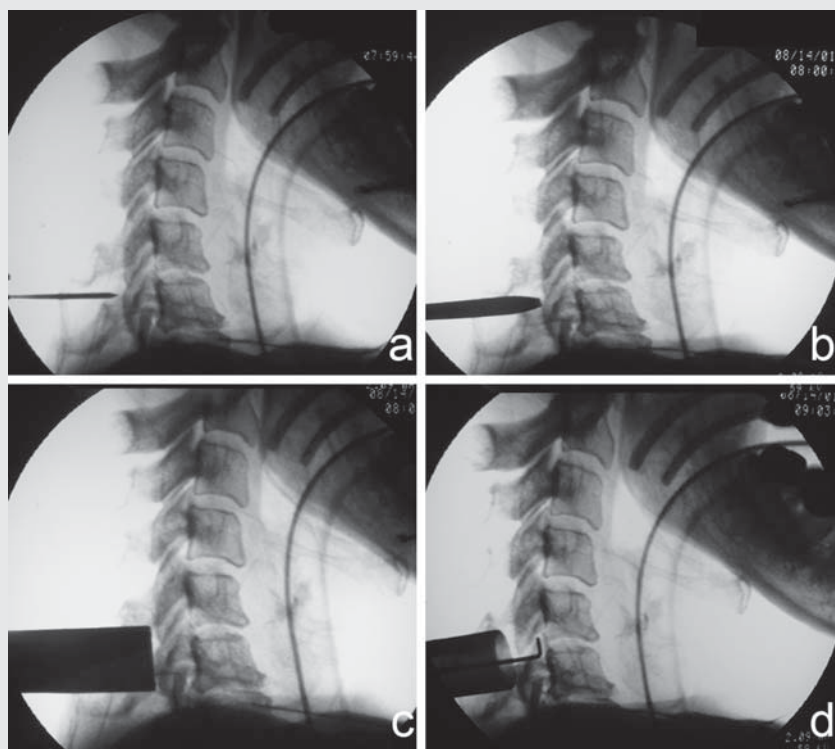


Figure 3 a-d:

A series of lateral fluoroscopic images demonstrating the: **a)** placement of the initial Steinman pin down to the operative level, **b-d)** the sequential passage of the tubular soft tissue dilators which gently spread the posterior cervical musculature.

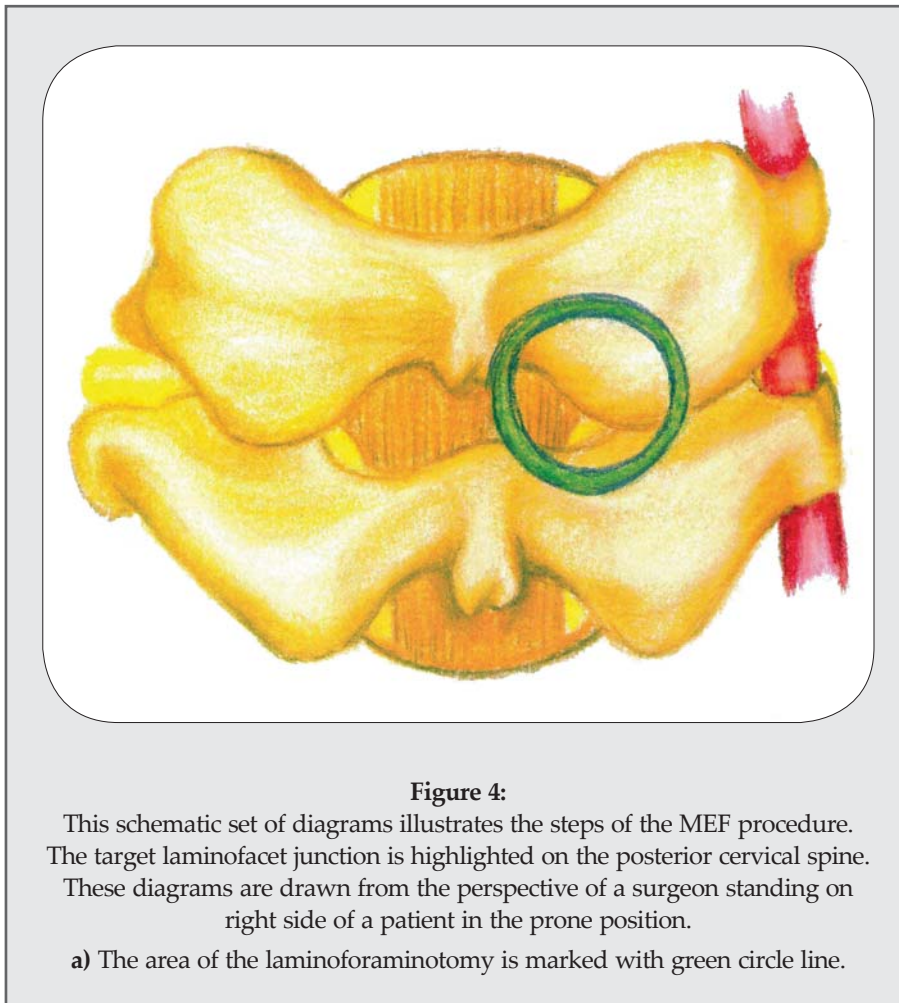


Figure 4:

This schematic set of diagrams illustrates the steps of the MEF procedure. The target laminofacet junction is highlighted on the posterior cervical spine. These diagrams are drawn from the perspective of a surgeon standing on right side of a patient in the prone position.

a) The area of the laminoforaminotomy is marked with green circle line.

is suitable to begin the foraminotomy. Periosteal and bone bleeding can be controlled with bone wax and cautery. A drill with a long endoscopic bit (e.g. AM-8 bit with Midas Rex, or TAC bit with MEDNext drill) can be used to thin the medial facet and lateral mass for the cases with marked facet arthropathy and enlargement. The decompression is carefully continued inferiorly and laterally along the course of the neural foramen (Figure 4c).

The laminoforaminotomy is completed after the exposition of the nerve root along its proximal foraminal course and the adequacy of the decompression can be checked by palpating the root along its course with a small nerve hook (Figure 4d). The nerve root is mobilized superiorly to expose the disc space and fragment with a nerve hook or small #4 Penfield for herniated disk cases. Drilling the supero-medial portion of the pedicle below the exiting nerve root can

obtain additional exposure and will create space for the root to be mobilized.

The disc fragment is removed in a standard fashion with curettes and long endoscopic pituitary rongeurs underneath the retracted root and encountered osteophytes is drilled or curetted. It will be better to confirm the free passage along the root with a nerve hook after the completion of the disectomy and decompression under lateral fluoroscopic image (Figure 4e). Additionally, we must ensure that the anterior surface, axilla and shoulder of the nerve root are free of residual disk material. But, fur-

ther caution is needed for the decompression of the paracentral disc herniations or osteophytes. Decompression of the far lateral foraminal stenosis or disc herniations can also be accomplished with MELF approach. The spine surgeons must care on the vertebral artery during decompression of this area. Brisk dark bleeding which depends on the rich venous plexus surrounding the vertebral artery warns us to limit further dissection and thus prevent inadvertent arterial injury. More than 50% facet removing may cause to iatrogenic instability of the cervical motion segment (17,18).

The hemostasis should be obtained with a bipolar cautery and a gentle tamponade with thrombin soaked gel-foam pledgets. After the irrigation of MELF area, we may place a small piece of gel-foam soaked with Solumedrol gently over the laminoforaminotomy defect. Use of epidural morphine paste or similar cock-

tails may help to reduce postoperative pain and allow for more rapid recovery and ambulation. A routine closure of the fascia and skin is performed after removing the tubular retractor and endoscope. Generally, there is no need to use a drain because of the small incision defect. The fascia is closed with reabsorbable 0-Vicryl stitches and it is continued with 4-0 Vicryl stitches for subcutaneous layer after the injection of marcaïn (0.25%).

5. Postoperative Care:

The patient is returned to the upright position immediately after the operation. The patient is then taken to the post-anesthesia recovery unit after awakening from anesthesia. A muscle relaxant is given systematically. The waterproof bandage permits the patient to bath or take a shower normally. MELF procedure does not result in either instability or fusion of the operated cervical motion segment. So, soft or other comfortable semi-rigid collars can be chosen for the comfort of the patients. The patients are allowed to rapidly mobilize and rehabilitation in the following hours after surgery to relax the paravertebral muscles. Arterial and intravenous lines are removed early on. The patients may be discharged the day after

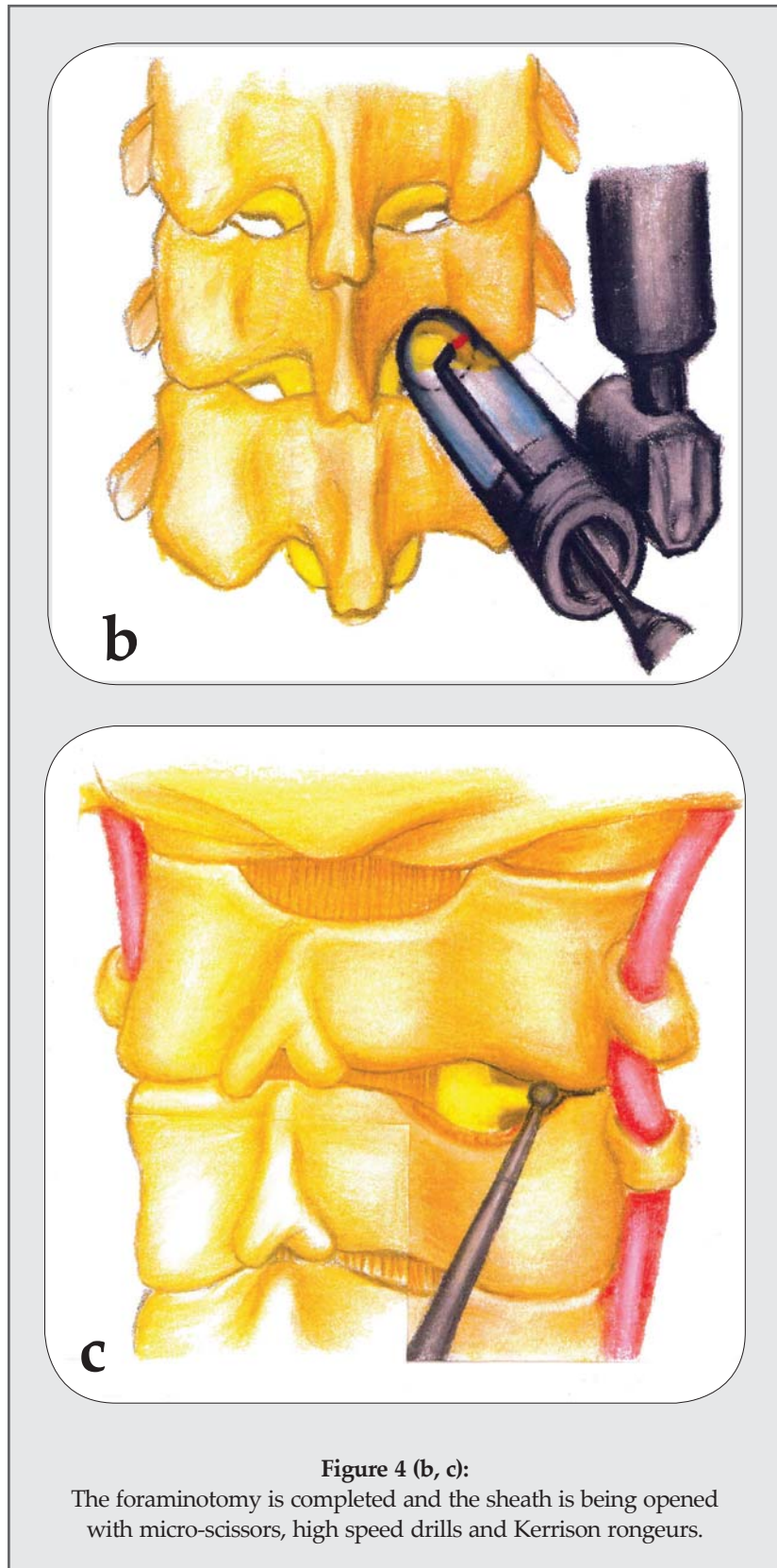


Figure 4 (b, c):

The foraminotomy is completed and the sheath is being opened with micro-scissors, high speed drills and Kerrison rongeurs.

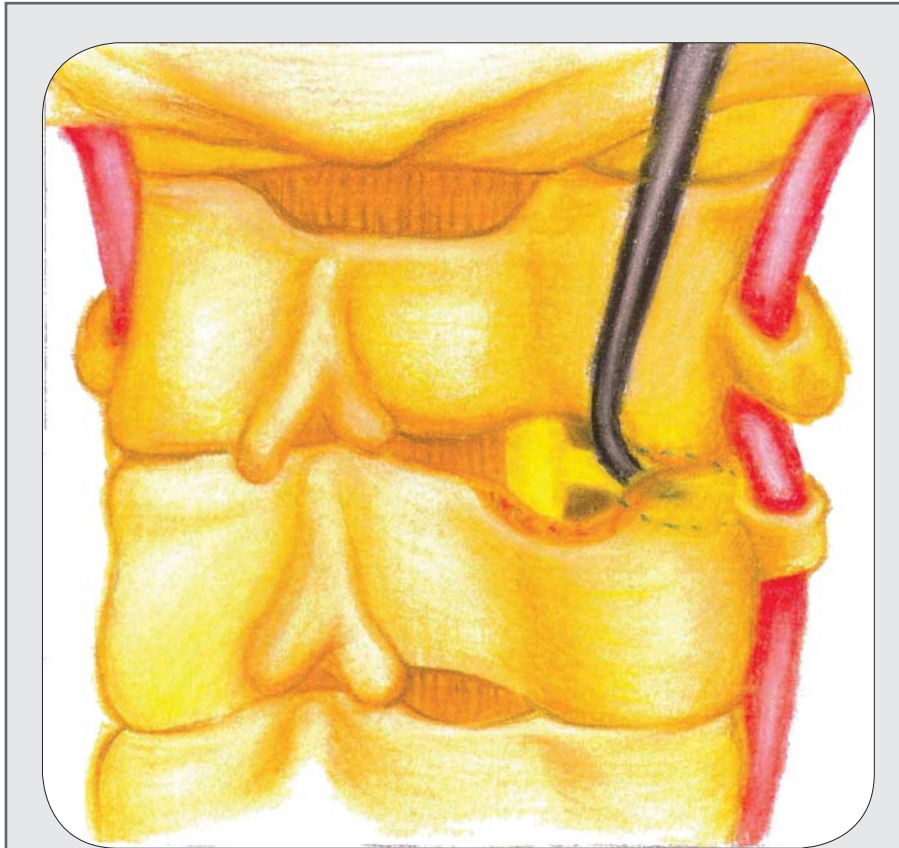


Figure 4 (d):
The root is gently elevated and the disc fragment is removed by a micro pituitary.

surgery. Depending on their pre-operative medications, patients undergoing MELF are typically discharged on a combination of muscle relaxant, non-steroidal anti-inflammatories, and an oral opioid for breakthrough pain. The patient may return his job in 2 weeks after surgery.

6. Complications and Avoidance:

Spinal cord injury may occur due to the removal of disc fragments, and spurs. Penetration of instruments may cause to contusion of spinal cord. These kinds of spinal cord injuries may result with quadriplegia, tetraplegia or paraplegia. Vertebral artery laceration is one of major complications during MELF. More practice with cadavers, advance anatomy education and familiar to the instruments may decrease these complications before starting the MELF.

The sitting position during MELF has a potential to cause air embolism or cerebral ischemia. It will be better to work with experienced neuroanesthesiologist to avoid the result of this complication. Additionally, to care on the sterilisation of the operation sets and instruments may prevent the patient from deep paraspinos, epidural or superficial wound infection. The hemostasis before removing the endoscope tubes may prevent the postoperative compressive hematoma in the epidural space.

The occurrence of cerebrospinal fluid (CSF) leakage from a small dural tear may be treated with

a lumbar drain for 2 to 3 days postoperatively without any direct repair of the duramater. Additional adjuncts such as fibrin glue, fat or muscle grafts can also be used if we detect the CSF leakage during operation. Direct repair can be necessary for large CSF leaks with the proper instruments through the endoscopic tube. Non-steroidal anti-inflammatory medications and bed rest will be better to avoid the possible complications of lumbar drainage such as spinal headaches and nausea.

7. References:

1. Frykholm R. Cervical nerve root compression resulting from disc degeneration and root sleeve fibrosis. *Acta Chir Scand* 1951; 160: 1-149.
2. Scoville WB, Whitcomb BB. Lateral rupture of cervical intervertebral discs. *Postgrad Med* 1966; 39: 174-180.

3. Bailey R, Badgley C. Stabilization of the cervical spine by anterior fusion. *J Bone Joint Surg* 1960; 42A: 565-594.
4. Cloward RB. The anterior approach for removal of ruptured cervical disks. *J Neurosurg* 1958; 15: 602-617.
5. Cloward RB. Complications of anterior cervical disc operation and their treatment. *Surgery* 1971; 69: 175-182.
6. Fessler RG, Khoo LT. Minimally invasive cervical microendoscopic foraminotomy (MEF): An initial clinical experience. *Neurosurgery* 2002; 51(2): 37-45.
7. Henderson CM, Hennessy RG, Shuey HJ, et al. Posterior-lateral foraminotomy as an exclusive operative technique for cervical radiculopathy: A review of 846 consecutively operated cases. *Neurosurgery* 1983; 13: 504-521.
8. Murphey F, Simmons JCH, Brunson B. Cervical treatment of laterally ruptured cervical discs: Review of 648 cases, 1939-1972. *J Neurosurg* 1973; 38: 679-683.
9. Hilibrand AS, Carlson GD, Palumbo MA, Jones PK, Bohlman HH. Previous anterior cervical arthrodesis radiculopathy. *J Bone Joint Surg Am* 1999; 81: 519-528.
10. Hunter LY, Braunstein EM, Bailey RW. Radiographic changes following anterior cervical spine fusions. *Spine* 1980; 5: 399-401.
11. Raynor R. Anterior or posterior approach to the cervical spine: An anatomical and radiographic evaluation and comparison. *Neurosurgery* 1983; 12: 7-13.
12. Roh SW, Kim DH, Cardoso AC, and Fessler RG. Endoscopic Foraminotomy Using MED System in Cadaveric Specimens. *Spine* 2000; 25(2): 260-264.
13. Raynor RB, Pugh J, Shapiro I. Cervical facetectomy and the effect on spine strength. *J Neurosurg* 1985; 63: 278.
14. Krupp W, Schattke H, Muke R: Clinical results of the foraminotomy as described by Frykholm for the treatment of lateral cervical disc herniation. *Acta Neurochi (Wien)* 1990; 107: 22-29.
15. Raimondi AJ. In *Pediatric Neurosurgery: Theoretical Principles, Art of Surgical Techniques*. Springer, New York, 1987; pp.98-105,107-109.
16. Ebersolf MJ, Raynor RB, Bovis GK, et al. Cervical Laminotomy, Laminectomy, Laminoplasty, and Foraminotomy. In *Spine Surgery: Techniques, Complication Avoidance and Management*. Benezel EC (ed). Churchill Livingstone, Philadelphia. 1999; pp. 251-253.
17. Kubo Y, Waga S, Kojima T, et al. Microsurgical anatomy of the lower cervical spine and cord. *Neurosurgery* 1994; 34: 895-902.
18. Sandhu FA, Perez-Cruet MJ, Fessler RG. Microendoscopic cervical foraminotomy and discectomy. In *An Anatomic Approach to Minimally Invasive spine Surgery*. Cruet-Perez MJ (eds) Quality Medical Publishing, St. Louis, Missouri. 2006, pp. 337-349.

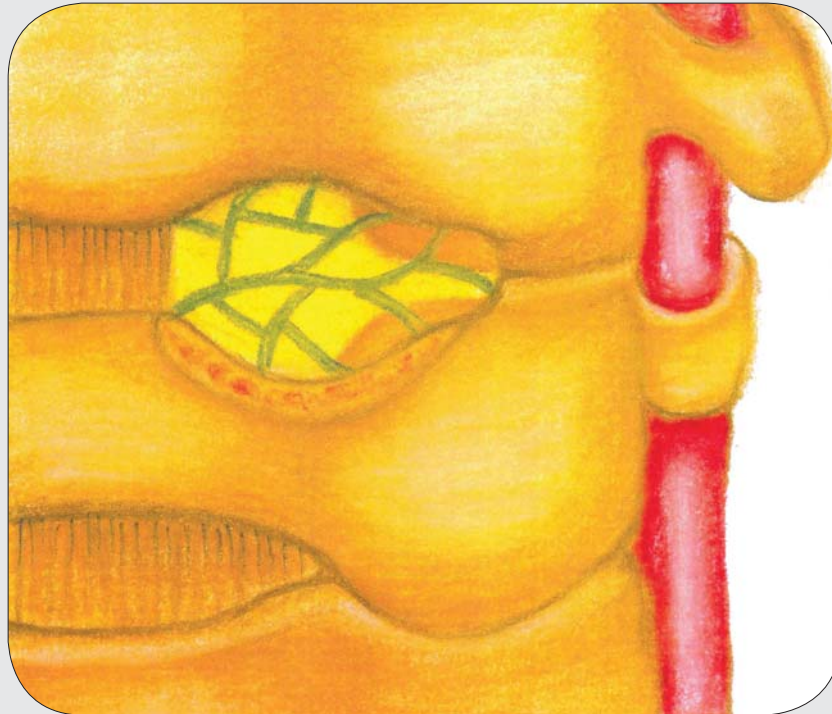


Figure 4 (e):

The nerve root is now decompressed with a full view of the foramen.

3d

MICROENDOSCOPIC MINIMALLY INVASIVE POSTERIOR CERVICAL INSTRUMENTATION AND FUSION TECHNIQUES

Farbod Asgarzadie MD, Larry T. Khoo MD

1. Introduction

A variety of techniques have been developed for internal fixation of subaxial cervical spine through a posterior approach ^(1,2). These include interspinous wiring with bone graft, interlaminar clamps, hook plates, Daab plates, lateral mass metallic plates and Harrington rod constructs. Before the advent of lateral mass screws fixation, interspinous wiring was commonly used for multilevel fixation. Using this technique three wires were passed through holes made at the spinolaminar junction and around the rostral border of the rostral spinous process (Figure 1a,b) ⁽³⁻⁵⁾. For cases requiring laminectomy with removal of the spinous processes, various facet wiring techniques were developed with and without bone grafting for purposes of stabilization. Combinations

of oblique facet and spinous wiring were also developed providing biomechanically superior fixation. The strength of this construct has been verified in biomechanical studies and excellent union has been reported in case reviews ⁽⁶⁻⁸⁾. Luque rectangles utilizing a triple-wiring technique through the facets were utilized in cases where the dorsal spinolaminar sites were unavailable, such as in severe posterior column injury. Unlike simple interspinous wiring, this technique allowed for the ability to bridge large dorsal column defects (e.g., after tumor resections), and provided greater rotational and torsional stability ^(9,10). In the late 1970's, Roy-Camille's group described a novel technique for posterior cervical instrumentation in which plates were secured to the lateral masses by the use of screws, a technique that proved to be significantly stronger than previous

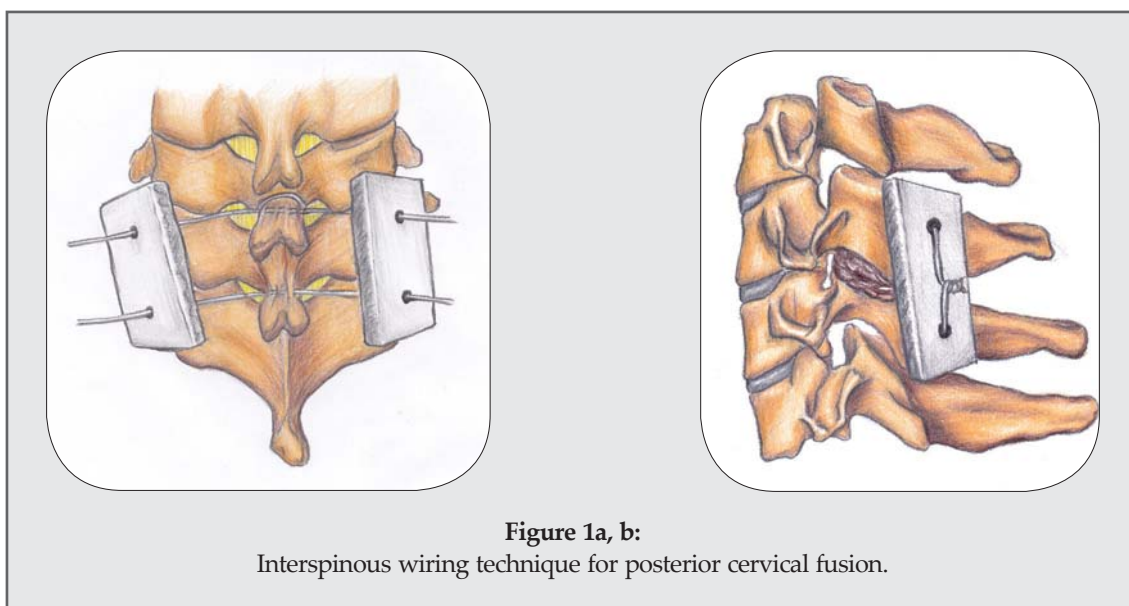
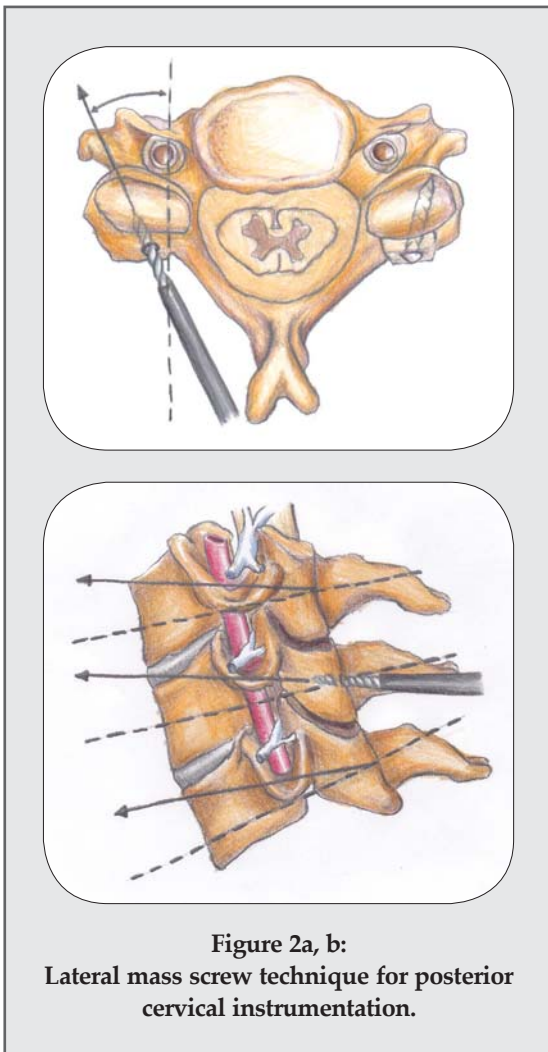



Figure 1a, b:
Interspinous wiring technique for posterior cervical fusion.

constructs on biomechanical cadaveric testing (Figure 2a,b) (11-15). In cases of cervical trauma utilizing this technique, 95 to 100% fusion rates were reported when autogenous bone grafting was performed (16,17). Because lateral mass screws at C7 may oftentimes render suboptimal purchase, pedicle fixation of the lower cervical spine and upper thoracic vertebrae has been proposed by several authors (18-24). Transpedicular screws have been shown to have more fixation stability compared to other midcervical reconstruction systems (25).



More recently developed instrumentation systems utilize two rods and variable screw islets at each level. These include the Axon systems (Synthes), Summit® (Depuy Acromed), S4 OCT (Aesculap), Vertex® (Medtronic Sofamor-Danek) (Figure 3). These systems vary by the angulation of their screws and



in the degree of the constraint placed at the screw-rod interface. The polyaxial tulip connectors of the screws are able to angle with varying degrees of rotational freedom in each direction. These systems make segmental fixation achievable from a top-loading approach, and thus allows for the possibility of minimally invasive posterior cervical fixation.

2. Indications and Contraindications

Decompression and fixation of the posterior cervical spine have been well established for a variety of indications including degenerative disease, trauma, tumor, infection, and deformity. With the advent of minimally invasive surgical techniques of the spine over the past decade, there have been significant improvements in the approach-related morbidities encountered with traditional techniques. The subperiosteal muscle dissection required in standard open procedures devitalizes the affected tissue and detaches crucial muscular and ligamentous insertions that can therefore disrupt the posterior musculoligamentous dynamic tension band. Traditional exposures can also cause substantial blood loss, muscular atrophy, and potentially large cosmetic defects. As a consequence of such iatrogenic injury, the effective-

ness of some traditional open procedures have been limited due to the potentially high level of postoperative disability.

As described in the previous chapter, one such example is the evolution of the decompressive posterior cervical laminoforaminotomy for lateral recess and neural foraminal decompression. The procedure has been shown to achieve symptomatic relief in 93 to 97% of patients who suffer from isolated cervical radiculopathy due to compression by disk or osteophyte (26-29). Enthusiasm for this surgery, however, was tempered by the considerable cervical muscular pain and spasm that often followed, resulting in slower recovery, especially in cases where the use of a wider incision was necessary for adequate visualization. A minimally invasive microendoscopic foraminotomy (Figure 4) minimizes the amount of tissue trauma and muscle injury, thereby overcoming the problems of postoperative pain and muscle spasm with the same clinical results as that of the classical open cervical foraminotomies (30,31).

Through the same minimally invasive path of tubular access, the lateral masses of the cervical spine can be readily approached. A 20 or 22 mm portal can expose two adjacent lateral masses and with the advent of some of the newer types of expandable ac-

cess portals, up to three lateral masses can be instrumented through a single exposure. The portals allow for the placement of top-loading polyaxial screws for the purposes of posterior cervical lateral mass fixation. Minimally invasive posterior cervical fixation (MI-PCF) has been applied in cases requiring lateral mass fixation with excellent clinical and radiographic results (32,33). The widespread popularity of simple top-loading polyaxial screw systems has also greatly facilitated the MI-PCF procedure.

3. Surgical Procedures

3.a. Patient Positioning and Set-Up

For the MI-PCF procedure, local anesthesia and intravenous sedation is inadequate due to the substantial risk of neurovascular injury in case of any accidental movement by the patient. Therefore, general endotracheal anesthesia is preferred along with rigid head fixation using a three-point head holder. Depending on the exact nature of the pathology, consideration should be given to fiberoptic intubation. Patients may be positioned in either a prone or sitting arrangement. An intermediate semi-sitting position may be helpful due to the reduced epidural venous engorgement and consequent decreased intraoperative blood loss with a minimal risk of air embolic events. As our experience with this surgical technique has grown, we no longer routinely place a CVP catheter due to the minimal blood loss of the operation. Prior to finalizing the head positioning, utmost care should be directed to ensuring that the cervical spine and neck musculature are not twisted or held in a grossly unusual position. Furthermore, the neck, chin, and chest must be allowed to remain loose and free of compression and all routine pressure points should be adequately protected.

Intraoperative somatosensory evoked potential (SSEP) monitoring of the operated dermatome and distal distributions is highly recommended in order to monitor spinal cord integrity during surgeries where decompression is to be combined with fixation. Electromyographic recordings can also be used to assess motor integrity of the involved nerve root, and can

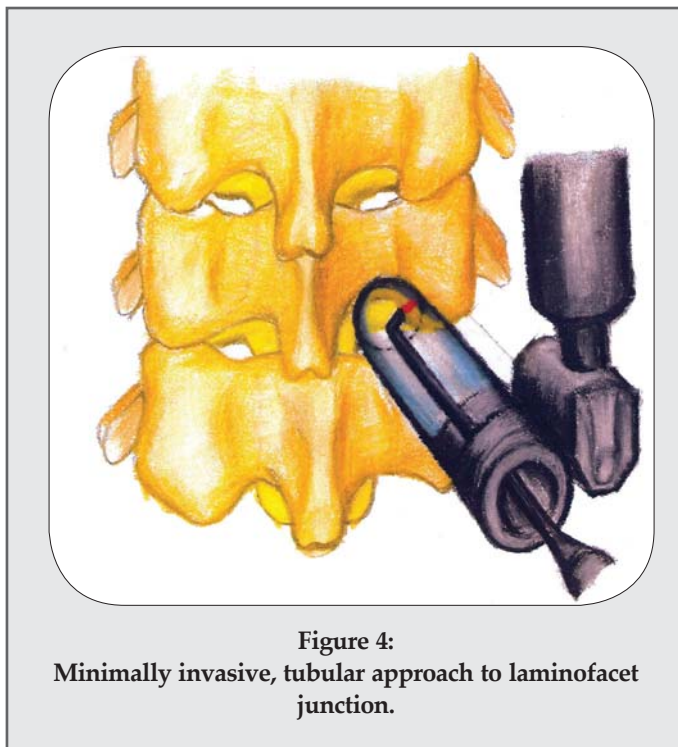


Figure 4:
Minimally invasive, tubular approach to laminofacet junction.

be used to stimulate the screws to increase safety and accuracy. This requires that the anesthesiologist refrain from the use of neuromuscular paralytics following induction in order to allow for improved feedback from the nerve root during the operation. For most cases, a single intraoperative dose of either Cephazolin or Vancomycin is used for prophylaxis against infection. We do not typically use corticosteroids for these procedures.

Intraoperative real-time imaging is a necessity for MI-PCF; therefore, a fluoroscopic C-arm should be brought into the surgical field. While lateral imaging is most commonly used for this procedure, the C-arm should be positioned in a manner that allows for easy rotation into various positions since visualization in other planes may become necessary – for example, anteroposterior fluoroscopic images can be helpful during the initial localization. Whereas lateral mass fixation can be accurately performed using anatomic landmarks, cervical pedicles should be cannulated with the use of supplemental lateral or AP fluoroscopic confirmation whenever feasible.

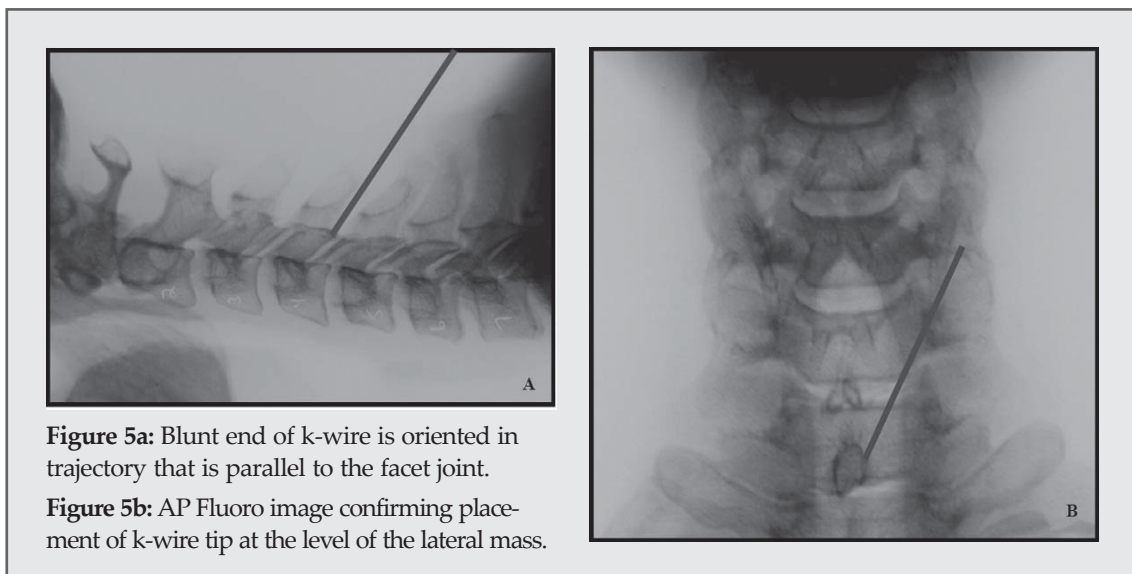
3.b. Surgical Technique

Tubular Dilatation and Exposure

The ultimate trajectory of the working portal matches that of the lateral mass screws. This trajectory dictates proper placement of the skin incision. As such, lateral fluoroscopy is essential for safe and appropriate guidance and to ensure proper ergonomic placement of the working portal directly on target.

After the patient is properly positioned, a Kirschner wire (K-wire) is placed lateral to the neck to exactly parallel the facet of interest to determine the center of the skin incision. The skin entry point lies two to three segments below the target level in the sagittal plane at the midline, and typically approximates the trajectory used during open lateral mass fixation. Confirmation of the appropriate trajectory is also done in the AP plane as well. Once this entry point is determined, under fluoroscopic guidance, the K-wire is inserted through the posterior cervical musculature and fascia to the target facet. One must take care to approximate the desired screw orientation by remaining parallel to the facet joint in the sagittal plane, with the pin trajectory directed in a superior and lateral direction (Figure 5a). Particular caution should be taken at this point to ensure that the guidewire is docked on bone to avoid inadvertent damage to the spinal cord by being too medial. To decrease the chances of this type of an interlaminar breach, it is recommended to aim more laterally during this docking maneuver. This can be confirmed through AP fluoroscopy (Figure 5b).

Once the guidewire is docked on the facet in question, the skin incision should be extended above and below the K-wire entry point for about 1 cm in each direction and deepened sharply to just below the level of the fascia, taking care not to cut muscle fibers during this procedure to avoid unnecessary bleeding. Sharp opening of the fascia allows for easier and safer passage of the sequential dilating cannula. Any plastic adhesive skin barriers should be



circumferentially removed from the edges of the incision to prevent inadvertent sequestration of material into the wound.

Sequential dilators are then inserted through the soft tissues and docked on the facet of interest. Real-time lateral fluoroscopic images should be obtained as often as needed to ensure a proper working trajectory throughout this process of serial cannula dilation. A final tubular working channel is inserted and docked at the junction of the lamina and the lateral mass (Figure 6). A variety of these working channels are available, including fixed 20 or 22 mm portals provided by the METRx[®] tubular access system (Medtronic Sofamor-Danek). As an alternative, expandable cannulas such as the Quadrant[®] system (Medtronic Sofamor-Danek) can provide a greater working space and more flexible approach angles for hardware placement, especially when two or more levels need to be addressed (Figure 7). Once the position of the working channel is confirmed using fluoroscopy, it is attached to a flexible retractor affixed to the side rail of the table and then locked into position. Visualization can be achieved using loupe magnification, an operating microscope, or an endoscope. If employed, the endoscope should be white-balanced and an antifog agent should be applied to

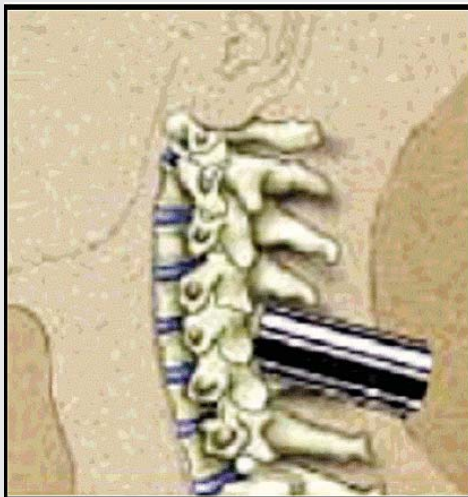


Figure 6:

A final tubular working channel is inserted and docked at the junction of the lamina and the lateral mass.




Figure 7:

A minimally invasive expandable retractor.

the lens after which the endoscope is attached to the tubular retractor via a mounting stage.

Instrumentation

The minimally invasive technique for screw placement does not significantly differ from the open methods once the lateral mass is exposed. For cases of trauma and/or cervical stenosis, decompression of the exiting root via the previously discussed minimally invasive cervical foraminotomy techniques can be executed prior to placing the screws. Similarly, cases of jumped facets can be drilled and reduced prior to placing the posterior instrumentation as well. The exiting nerve root is more likely to be encountered by a screw trajectory that is aimed too low and the vertebral artery is more likely to be damaged by screw trajectories that are excessively medial. Thus, in order to avoid the neurovascular structures, the technique focuses on placing the screw into the upper lateral quadrant of each lateral mass. There are various methods for screw placement into the cervical lateral masses. The first report of the procedure described screw placement directed forward and outward 10 degrees⁽⁴³⁾. Subsequent modifications recommended placing the screw at a point slightly medial to the center of the facet and directing it 25 degrees laterally and about 40 degrees cephalad⁽⁴⁴⁾. Other authors advocated for a technique in which the entrance point of the screw is 1 mm medial to the center of the lateral mass and aimed 15 to 20 degrees cephalad and 30 degrees laterally⁽⁴⁵⁾. The outer cortex

should be pierced either with an awl or a high-speed drill in order to prevent the drill from sliding over the lateral mass instead of entering the bone during screw placement. For C3 to C6 (and sometimes C7), it is recommended that the drill holes be made with a 15 to 20-degree cephalad angle and a 30-degree lateral trajectory. This rostral angle targets the transverse process and decreases the chance of damage to uninvolved joints. By starting the drill hole 1 mm medial to the center of the lateral mass and aiming laterally, there is less risk of damage to the vertebral artery which usually lies anterior to the junction of the lamina and the lateral mass. After drilling, the dorsal cortex can be tapped using the 3.5 mm cancellous tap. Because the majority of the new polyaxial screws are self-tapping, this step is not essential.

Screw length should allow for full penetration of the outer cortex and cancellous bone and, in case of trauma, bicortical screw penetration may help to achieve better purchase. The lengths typically vary between 12 and 16 mm, but are affected by factors such as the patient's specific anatomy, the presence of dorsal osteophytes, and the exact screw trajectory. Although violations of soft tissues by an overly lengthy screw are seldom problematic if the trajectory is correct, preoperative measurements from CT scans can be helpful in determining the best screw length, especially if a bicortical screw purchase is desired.

Care must be taken to fully expose the facet joints and lateral borders of the lateral masses, which can be readily accomplished with a shielded monopolar cautery combined with pituitary rongeurs. While the capsular ligaments and soft tissue around the facets are removed, the facet joints above and below the involved ligaments should remain intact to prevent late instability or fusion at those levels. The monopolar cautery can be used to stop bleeding such as that from the venous plexus lateral to the lateral masses; however, caution should be exercised to avoid inadvertent injury to the vertebral artery by avoiding overly aggressive cautery in this region. Alternatively, gentle tamponade with Gelfoam® or Surgifoam® will often effectively stop bleeding from this venous plexus.

For cases where facet realignment is not necessary, the lateral mass screws can simply be placed in an *in situ* fashion. If open reduction is needed, a high-speed drill can be used to remove a portion of the superior articular process of the inferior vertebrae, and a Penfield-type instrument can then be inserted

within the facet and rotated to elevate and posteriorly displace the subluxed lateral mass into proper anatomical alignment. An alternative method for open reduction involves disengaging the head holder after drilling of the facet edges followed by gentle in-line traction, appropriate anterior translation, and counterrotation opposite to the mechanism of injury for proper facet realignment. The head holder is then relocked and the facet complex fused *in situ*. It is highly recommended that SSEP monitoring combined with nerve root surveillance at the pathologic level be used during such maneuvers. Should neural decompression be necessary, it is recommended that the screw sites be marked, drilled, and tapped prior to removing the laminae. This method protects the dura and spinal cord during the drilling process⁽³²⁾.

The joint cartilage from the facets should be removed prior to instrumentation, and the joint should be decorticated using a high-speed drill with a small bit. Although there is a wide body of literature demonstrating successful arthrodesis without the use of bone graft, it is generally recommended to use bone grafts – such as cancellous autologous bone from the iliac crest – within the facets as well as over the decorticated laminofacet junctions. Given the postoperative pain syndrome associated with iliac bone harvesting, as an alternative source of autologous bone, the dust obtained during facet drilling, laminotomy, and foraminal decompression can be used. This graft can then be combined in a one-to-one ratio with an appropriate bone extender, such as demineralized bone matrix or calcium triphosphate substitutes.

After denuding the facet and placement of bone graft, an appropriately sized lateral mass screw is then inserted under both direct visualization and fluoroscopic guidance. Depending on the size of the lateral mass, 14 or 16 mm length, 3.5 mm diameter, screws are typically used. The exact size can be measured on the CT scan or estimated from lateral intraoperative fluoroscopy. The tubular retractor arm usually must be relaxed at this point to allow easy acquisition of the second screw trajectory following which the second screw is placed in the manner detailed above (Figure 8 A-B).

Since the C7 lateral mass is much thinner than that of the more rostral levels, placement of a lateral mass screw may prove to be excessively difficult; therefore, a pedicle screw may need to be used at this level instead. Furthermore, cervical pedicle

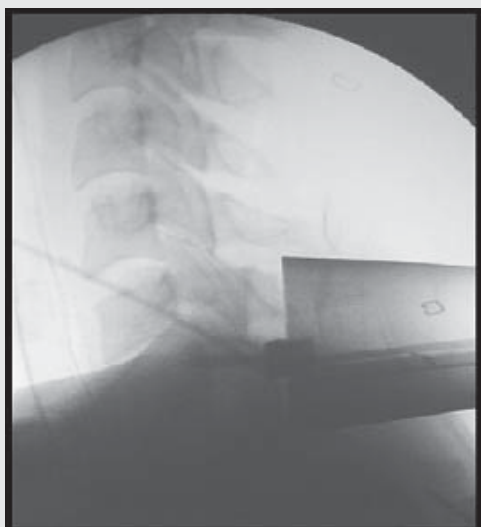


Figure 8a: Lateral fluoroscopic image showing an expandable retractor spanning two lateral masses.

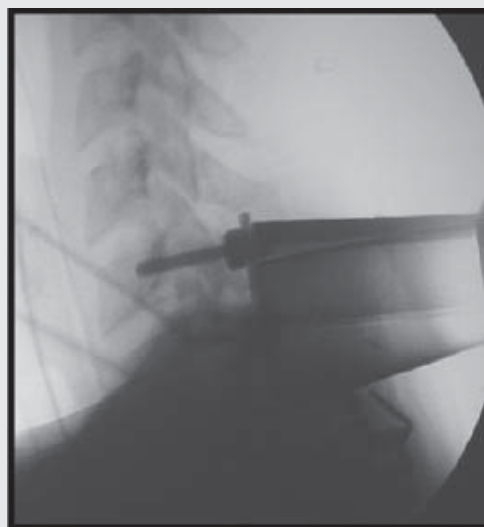

Figure 8b: Lateral fluoroscopic image showing an expandable retractor allowing insertion of two lateral mass screws and a rod.

screws may attain greater pullout strength than lateral mass screws due to the greater length and circumferential cortical penetration. Cervical pedicle screws may also be used in levels where the lateral mass is fractured or unusable. There is usually no vertebral artery in the transverse foramen allowing for safe pedicle screw placement at this level and at T1. For C7 pedicle screw placement, the drill is generally angled 25 to 30 degrees medially, and perpendicular to the rostral-caudal plane. At the T1 level, the angle is usually 10 to 15 degrees medially and 5 degrees caudally. A careful examination of the preoperative CT scan is important in order to determine the pedicle size and to gauge the appropriate angle. Usually, a 4.0 mm cortical screw of 20 to 22 mm length is sufficient in size. A small laminotomy can be made to palpate the medial aspect of the pedicle or AP fluoroscopy can be used for safer placement of the screw.

Following placement of the screws, an appropriate-sized rod is inserted into the top of the polyaxial screws and locked into place. The rod diameter generally varies from 3.2 to 3.5 mm, depending on the specific system used. Rod placement is more technically challenging when fusing three adjacent segments, but careful dorsal elevation of the tubular retractor system away from the facet joints usually creates adequate space for rod manipulation and placement.

For this reason, the expandable retractors in conjunction with modern top loading polyaxial tulip head fixation systems, such as Mountaineer® (Depuy), or Vertex® (Medtronic Sofamor-Danek), are particularly useful at providing a larger working space. Once the rods are locked into place, the construct is complete (Figure 9). Appropriate lateral and anteroposterior

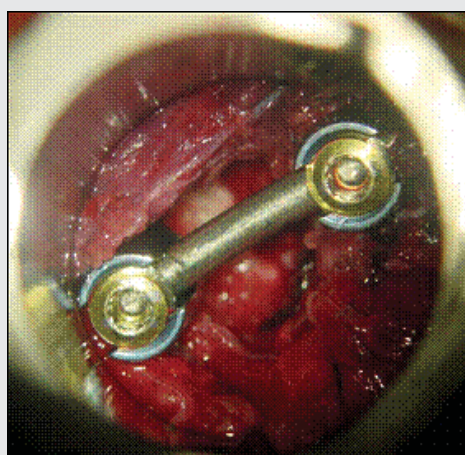


Figure 9: Intraoperative picture showing a complete one-level lateral mass screw-rod construct.

fluoroscopy should be used at this point to confirm proper bony alignment and construct placement, following which the tubular retractor is removed. For cases where bilateral fixation is needed, the above steps can be repeated through the same midline incision, using a contralateral trajectory. Closure is then completed with a simple fascial O-vicryl stitch followed by some degree of subcutaneous closure with 3-0 Vicryl. Skin closure can be accomplished with steri-strips or DermaBond type closure .

Transfacet screws

Posterior cervical fixation can also be achieved through transfacet screws. For this procedure the optimum entry point for the screw is on the center of the lateral mass with a trajectory that is perpendicular to the facet joint (Figure 10A). As such, the incision should be placed more rostrally in order to allow for the insertion of the K-wire in such a manner that it docks at 90 degrees to the facet and parallel to the spinous process. Once the entry point and trajectory have been confirmed, the K-wire is driven into the superior articular process to a depth that is determined by the length of the specific compression device to be used. Fluoroscopy should be used in order to insure appropriate depth and trajectory.

At this point the bone is drilled through the superior lateral mass, across the facet, and into the inferior lateral mass to a depth of about half to two-thirds of the inferior lateral mass width as guided by lateral fluoroscopy. This procedure is facilitated by systems that supply cannulated drills with depth limiting contacts that are designed to be passed over the K-wire, such as the 3.8mm CS Facet Compression Device® (Triage Medical). For this system, after the proper depth has been achieved, the drill hole is tapped and the compression device is passed over the K-wire, engaged, and locked in place. The K-wire is then removed and the procedure is repeated for the contralateral side in a similar manner. For cases of simple adjunctive dorsal fixation after multilevel anterior fixation, the percutaneous in-line nature of this fixation technique has proven to be extremely rapid, efficient, and cost-conscious (Figure 10B).

While this transarticular fixation system allows for fixation at all cervical levels including C1 and C2, a modified version of the above-mentioned procedure can also be used for arthrodesis in cases of

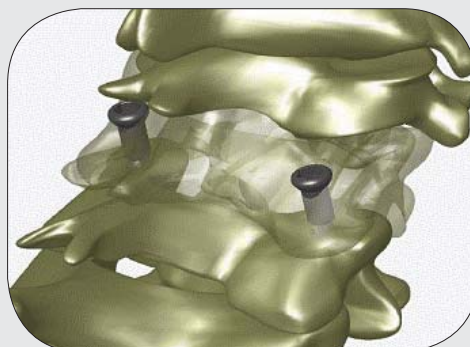


Figure 10a:
Diagram depicting transfacet screws of the cervical spine.

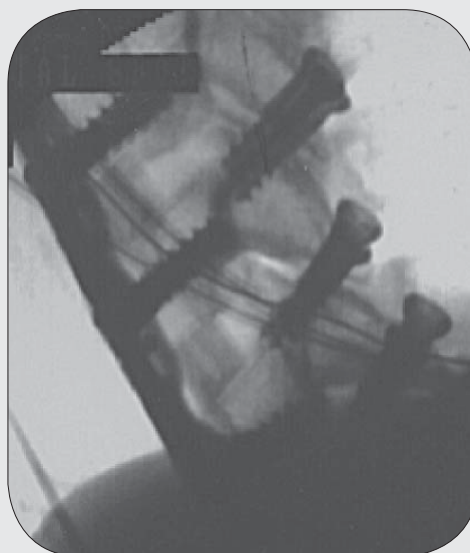

Figure 10 b:
Lateral x-ray revealing transfacet screws of the cervical spine as a means of providing a posterior tension band in a multilevel anterior cervical fusion procedure.

trauma such as operative cases of Hangman's type fractures. The initial approach for this type of surgery is similar to the transarticular procedure described above in that the entry point for the drill is at the center of the C2 lateral mass with a trajectory that is parallel to the spinous process in the lateral plain; however, instead of the device being aimed inferiorly, the trajectory in the cephalad-caudad direction is toward the superoanterior border of the C2 pedicle at a depth that allows for bicortical pur-

chase. Once this trajectory is confirmed by lateral fluoroscopy, the remainder of the operation is completed as described above.

Closure

Prior to closure, meticulous hemostasis should be obtained by a combination of bipolar cautery and gentle tamponade with thrombin-soaked Gelfoam® or Surgifoam®. The entire wound is then copiously irrigated with lactated ringers impregnated with bacitracin antibiotics. Although optional, a small pledget of Gelfoam® soaked with methylprednisolone can be placed over the decompression defects, if present in order to decrease local inflammation. The use of epidural morphine paste or similar cocktails is reasonable if there is no evidence of dural erosion or tear. Such agents may help to reduce postoperative pain and allow for more rapid recovery and ambulation.

The portal is cautiously removed and the soft tissue corridor is washed with antibiotic irrigation prior to a routine closure of the fascia with one or two 0-Vicryl® or similar absorbable sutures. Because the defect is typically small, only a limited amount of closure needs to be performed, and a drain is not needed. Bupivacaine (0.25%) may be injected into the skin edges and superficial musculature prior to closure in order to minimize immediate postoperative pain. Inverted 2-0-Vicryl® stitches are usually used to close the subcutaneous layer with a 4-0-Monocryl® subcuticular closure to meticulously reapproximate the skin edges. Either Steri-Strips® or Dermabond® can then be used to cover the skin. The latter is an attractive option since it keeps the skin edges closely approximated for a 7- to 10-day period, and it provides a waterproof barrier, allowing the patient to shower almost immediately after surgery, if desired.

4. Complications and Avoidance

Although the lateral screw fixation method carries a risk of potential neurovascular injury, proper use of the technique is associated with an extremely low incidence of complications – only 4 to 6%. A disadvantage of lateral mass instrumentation, however, is that it is primarily an in situ fixator and cannot be reliably used for reduction of a significant kyphosis, which is why for major anterior compression, kyphosis, or cases with very poor bone quality in the lateral masses an anterior approach is recommended

with posterior supplemental fixation as deemed necessary to enhance stability and maintain the operative correction.

When a CSF leak occurs in the course of a MI-PCF, direct repair is often difficult because the durotomy is usually small and access is limited. Thus, the use of fibrin coagulation products, fat, or muscle grafts should be used. Lumbar drainage can also be used in these cases for 2 to 3 days postoperatively, combined with elevation of the head of the bed, in order to help closure of the small dural tear. Spinal headaches and nausea associated with lumbar drainage can be treated symptomatically with non-steroidal anti-inflammatory medications and bed rest. For large dural tears, direct repair can be attempted if specialized instruments are available for use through the endoscopic tube: Fine-tipped needle holders and long forceps are particularly useful in this regard. In rare instances, conversion to an open procedure may be necessary to close very large dural violations.

5. Clinical Experience

The initial experience with minimally invasive cervical fixation at UCLA consists of 10 patients followed to radiographic fusion – 6 patients underwent a single-level fusion and 4 patients with two-level fusions. Instrumentation was performed at the C3 to C7 segments with bilateral screw placement with the exception of 3 cases where lateral mass screws were placed unilaterally due to bony fractures on the contralateral side. Seven cases were posterior supplementations of anterior fusions, and three were stand-alone posterior constructs. Seven of the ten patients underwent surgery due to traumatic pathology with cervical burst fractures and fracture dislocations treated with combined anterior and posterior fusions. In three cases with bilaterally jumped facets treatment consisted of drilling and removal of the superior facet followed by intraoperative reduction and hardware placement with fusion. Three cases were posterior supplements to an anterior vertebrectomy for neoplasia.

All procedures were accomplished successfully with the use of 18 to 22 mm tubular dilator retractors. There were no complications or new neurologic deficits, and proper hardware placement was confirmed with a postoperative CT scan. In

one case, the C6 screw was positioned fairly laterally with penetration of the lateral cortex of the lateral mass; however, no additional procedure or followup studies were deemed necessary as this was still thought to provide a stable construct. Fusion was confirmed in all cases with dynamic x-rays and CT scans.

Current tubular dilator dimensions limit the feasibility of this minimally invasive approach to one or two-level fusions, since longer segment constructs pose a problem with rod placement. However, the development of elliptical expandable tubular dilators may allow longer constructs to be placed safely. Furthermore, strategies similar to the arc rod systems and polymerizing connecting rods, which currently allow true percutaneous transpedicular instrumentation in the lumbar spine, may also prove to be beneficial in the cervical spine where it may ultimately allow for placement of longer segment cervical constructs in a minimally invasive fashion.

Radiographic guidance is essential for safe screw placement, and fluoroscopic images may be inadequate for the lower cervical spine in patients with a short neck, large body habitus, or muscular shoulders. Image-guided systems surmount this problem and allow for virtual representation of the spine without the need for real-time x-rays. However, these systems are limited in accuracy with regard to the differences in the intersegmental relationships between vertebrae in preoperative image acquisition and final operative positioning. These inaccuracies are especially exaggerated in cases with abnormal intersegmental motion or in patients who require reduction of a fracture.

The emergence of three-dimensional fluoroscopic imaging allows for intraoperative acquisition of axial CT renderings of the spinal column. These images are less hampered by superimposed soft tissues, which allow access to the lower cervical spine for the purpose of minimally invasive screw placement. Furthermore, because the images are acquired intraoperatively, screw trajectories can be more reliably confirmed by guidewire placement prior to final instrumentation. Amalgams of 3-dimensional intraoperative imaging modalities with frameless navigation systems will ultimately make percutaneous placement of cervical instrumentation safe and accessible.

6. References

1. Aebi M, et al. AO ASIF Principles in Spine Surgery. 1998. New York: Springer.
2. Chapman JR, et al. Posterior instrumentation of the unstable cervicothoracic spine. *J Neurosurg* 1996; 84: 552-8.
3. Bohlman HH. Acute fractures and dislocations of the cervical spine. An analysis of three hundred hospitalized patients and review of the literature. *J Bone Joint Surg Am* 1979; 61: 1119-42.
4. Cahill DW, et al. Bilateral facet to spinous process fusion: a new technique for posterior spinal fusion after trauma. *Neurosurgery* 1983; 13: 1-4.
5. Callahan RA, et al. Cervical facet fusion for control of instability following laminectomy. *J Bone Joint Surg Am* 1977; 59: 991-1002.
6. McAfee PC, et al. Triple wire technique for stabilization of acute cervical fracture dislocation. *Orthop Trans* 1986; 10: 455-6.
7. Perin NL and Cusick JF. Interspinous, lamina, and facet fusion. In *Spine Surgery: Techniques, Complication Avoidance, and Management*. E. Benzel (Ed.) 1999. Philadelphia, PA: Churchill Livingstone. pp. 257-263.
8. Sutterlin CE, 3rd, et al. A biomechanical evaluation of cervical spinal stabilization methods in a bovine model. Static and cyclical loading. *Spine* 1988; 13: 795-802.
9. Coe JD, et al. Biomechanical evaluation of cervical spinal stabilization methods in a human cadaveric model. *Spine* 1989; 14: 1122-31.
10. Maurer PK, et al. Cervical spondylotic myelopathy: treatment with posterior decompression and Luque rectangle bone fusion. *Neurosurgery* 1991; 28: 680-3.
11. Roy-Camille R, et al. Internal fixation of the unstable cervical spine by posterior osteosynthesis with plates and screws. In *The Cervical Spine*. (2nd ed). The Cervical Spine Research Society Editorial Committee (Ed.) 1989. Philadelphia, PA: Lippincott-Raven. pp. 390-404.
12. Benzel EC. Construct design. In *Biomechanics of Spine Stabilization: Principles and Clinical Practice*. E. Benzel (Ed.) 1995. New York: McGraw-Hill. pp. 163-172.
13. Cooper PR, et al. Posterior stabilization of cervical spine fractures and subluxations using plates and screws. *Neurosurgery* 1988; 23: 300-6.

14. Gill K, et al. Posterior plating of the cervical spine. A biomechanical comparison of different posterior fusion techniques. *Spine* 1988; 13: 813-6.
15. White AA and Panjabi MM. Biomechanical considerations in the surgical management of the spine. In *Clinical biomechanics of the spine*. (2nd ed). A. White and M. Panjabi (Ed.) 1990. Philadelphia, PA: Lippincott-Raven. pp. 511-639.
16. Ebraheim NA, et al. Internal fixation of the unstable cervical spine using posterior Roy-Camille plates: preliminary report. *J Orthop Trauma* 1989; 3: 23-8.
17. Khoo L, et al. Biomechanical Comparison of Fixation Techniques across the Cervicothoracic Junction. Presented at Annual Meeting of North American Spine Society. 2000. New Orleans, LA.
18. An HS, et al. Spinal disorders at the cervicothoracic junction. *Spine* 1994; 19: 2557-64.
19. Dekutoski MB, et al. Comparison of in vivo and in vitro adjacent segment motion after lumbar fusion. *Spine* 1994; 19: 1745-51.
20. Delamarter RB, et al. The C7-T1 junction: problems with diagnosis, visualization, instability and decompression. *Orthop Trans* 1989; 13: 218.
21. Evans DK. Dislocations at the cervicothoracic junction. *J Bone Joint Surg Br* 1983; 65: 124-7.
22. Kramer DL, et al. Placement of pedicle screws in the cervical spine: Comparative accuracy of cervical pedicle screw placement using three techniques. *Orthop Trans* 1997; 21: 496.
23. Panjabi MM, et al. Cervical human vertebrae. Quantitative three-dimensional anatomy of the middle and lower regions. *Spine* 1991;16: 861-9.
24. Stanescu S, et al. Morphometric evaluation of the cervico-thoracic junction. Practical considerations for posterior fixation of the spine. *Spine* 1994; 19: 2082-8.
25. Kotani Y, et al. Biomechanical analysis of cervical stabilization systems. An assessment of transpedicular screw fixation in the cervical spine. *Spine* 1994; 19: 2529-39.
26. Henderson CM, et al. Posterior-lateral foraminotomy as an exclusive operative technique for cervical radiculopathy: a review of 846 consecutively operated cases. *Neurosurgery* 1983;13: 504-12.
27. Krupp W, et al. Clinical results of the foraminotomy as described by Frykholm for the treatment of lateral cervical disc herniation. *Acta Neurochir (Wien)* 1990; 107: 22-9.
28. Murphey F, et al. Surgical treatment of laterally ruptured cervical disc. Review of 648 cases, 1939 to 1972. *J Neurosurg* 1973; 38: 679-83.
29. Odom GL, et al. Cervical disk lesions. *J Am Med Assoc* 1958; 166: 23-8.
30. Roh SW, et al. Endoscopic foraminotomy using MED system in cadaveric specimens. *Spine* 2000; 25: 260-4.
31. Fessler RG, Khoo LT. Minimally invasive cervical microendoscopic foraminotomy: an initial clinical experience. *Neurosurgery* 2002; 51: 37-45.
32. Khoo L. Minimally-invasive posterior decompression and fixation of cervical jumped facets: An initial clinical experience in 11 patients. Presented at Annual Meeting of the AANS/CNS Section on Disorders of the Spine and Peripheral Nerves. 2003. Tampa, FL.
33. Wang MY, et al. Minimally invasive lateral mass screws in the treatment of cervical facet dislocations: technical note. *Neurosurgery* 2003; 52: 444-7.
34. Grob D and Magerl F. Dorsal spondylodesis of the cervical spine using a hooked plate. *Orthopade* 1987; 16: 55-61.
35. Haid RW, et al. Lateral mass plating for cervical instability. Presented at Congress of Neurological Surgeons. 1990, Los Angeles, CA.

3e

ANTERIOR CERVICAL MICROFORAMINOTOMY

R Kemal Koc MD

1. Introduction:

Cervical radiculopathy is typically caused by posterolateral disc herniation or spondylotic foraminal stenosis. Standard surgical treatment for cervical degenerative disc disease has been either direct anterior excision necessitating fusion or indirect posterior decompression. Anterior decompression has now become more widely used. It can be achieved using different techniques.

Anterior fusion procedures; Anterior cervical discectomy with fusion is an excellent option for one or two-level spondylosis. Anterior corpectomy may provide an improved decompression and is ideal for patients with kyphotic deformity⁽¹⁾. Anterior cervical discectomy with fusion and corpectomy techniques requires bone fusion with or without spinal instrumentation, and a degenerative change at adjacent vertebral levels frequently results in long-term morbidity. Wada *et al.*⁽²⁾ demonstrated that listhesis exceeding 2 mm developed at 38% of the upper adjacent levels, osteophyte formation occurred at 54% of the lower adjacent levels, and axial pain was observed in 15%. The mean vertebral range of motion had decreased from 39.4 degrees to 19.2 degrees in 49% of patients by the final follow-up assessment. In addition, conventional corpectomy series are excessively focused on graft morbidity and pseudoarthrosis⁽¹⁻³⁾.

Anterior cervical foraminotomi (ACF); The ACF technique involves direct decompression of the nerve root just as the anterior discectomy techniques does, but does not require bone fusion or postoperative immobilization. In addition, ACF preserves the motion unit anatomically as well as functionally. The drilling is much more extended laterally on the opera-

tive side, and ACF totally opens the intervertebral foramen. ACF requires considerable technical skill to keep the intervertebral disc intact functionally. To maintain spinal stability, ACF hole has to be small enough to maintain structural integrity. Extensive decompression can easily cause symptoms of spinal instability even flexion-extension radiographs reveal no obvious instability postoperatively.

Jho^(4,5) showed that excellent clinical outcomes with fast recovery and adequate anatomical decompression in patients with cervical spondylotic myelopathy and radiculopathy. Johnson *et al.*⁽⁶⁾ reported the good or excellent outcomes in 85% of patients treated with ACF. However, Hacker and Miller⁽⁵⁾ retrospectively reviewed 23 patients who underwent ACF, and they found that 30% of patients' required additional surgery and 53% of patients experienced a good or excellent outcome. Reoperation rate is considerably higher than other series of anterior cervical surgery for radiculopathy. Their poor surgery-related outcome seems to be directly due to spinal instability and collapse of the neural foramen caused by their excessive removal of the uncinat process. Katoni *et al.*⁽⁸⁾ showed that uncovertebral joint resection resulted in decreased stability of the functional spine unit in every plane of motion.

1.a. Advantages

- Minimally traumatizing exposure; supine surgical position, anatomic cleavage dissection, and direct decompression of the nerve root.
- The segment mobility is preserved and prevents the acceleration of degenerative changes at adjacent levels.
- The drilling is totally opens the intervertebral foramen.

- Elimination of bone fusion and immobilization.
- The number of levels has never been considered to be a limitation of this technique.

1b. Disadvantages

- Approach not familiar to most surgeons.
- Difficulty to maintain spinal stability. Foraminotomy hole has to be small enough to maintain structural integrity. Extensive decompression can easily cause symptoms of spinal instability.
- The potential injury for the vertebral artery (VA).

Preoperatively all patients had radiography (lateral neutral, flexion, and extension views), magnetic resonance (MR) imaging and computerized tomography (CT) scans of the cervical spine. Cervical spondylosis was confirmed on MR imaging and CT scanning.

Although this surgical technique requires meticulous microsurgical skill, advantages of this surgical technique are quickly recover without bone fusion and preserving the motion segments. Preservation of the motion segment avoids fusion of the disc space and potentially the long-term degenerative changes at adjacent disc levels. This surgical technique has shown excellent clinical outcomes with adequate anatomical decompression in patients with CSR. This technique is, therefore, alternative to the anterior transcorporeal approach.

2. Indications:

Absolute:

- Unilateral radicular symptoms due to cervical spondylotic radiculopathy (CSR).
- Imaging studies corresponding to the clinical symptoms.

Relative:

- Foraminal soft disc herniation.

3. Contraindications:

Absolute:

- Significant spondylotic stenosis causing spinal cord compression.
- Contralateral foraminal stenosis.
- Predominantly posterior compression.

- Patients whose dynamic plain radiographs show more than 2 mm of movement between two connective vertebral bodies.
- Severe mechanical neck pain.

Relative:

- Thyromegaly.

4. Surgical Procedure:

4.a. Surgical Equipment:

Operating table suitable for spine surgery, operating microscope, biplanar C-arm, high speed drill and cervical microforaminotomy surgical tools are the main parts of this surgical equipment (figure 1a, 1b, 1c).

4b. Operating Room set up:

The commander part of C- arm and operating microscope is located opposite to the surgeon. The high speed drill is prepared and located at the nurse desk. The position of surgeon depends on the pathology of cervical spine. The surgical assistant is positioned opposite to the surgeon and operation technician or nurse is located between the surgeon and assistant (figure 2).

4.c. Patient Positioning:

The supine position with a slight extension of the neck is suitable for anterior cervical microdiscectomy operations. The operation level is marked with C-arm and operation area is washed and draped in a usual sterile fashion. Prophylactic antibiotics may be initiated before the operation to avoid from the infection (figure 3a, 3b).

4.d. Surgical Technique:

The detailed surgical technique has been reported by Jho⁽⁵⁾. Some modification was performed. The anterolateral aspect of the cervical spine is approached from the symptomatic side. The skin incision is made transverse in one or two levels and longitudinal in three or more levels. A transverse skin incision is made about 3 to 6 cm long at the anterolateral neck along a skin crease (figure 4a). A longitudinal skin incision is made along the medial edge of the sternocleidomastoid (SCM) muscle for 5-7 centimeters in mid-portion of lesion. The subcutaneous tissue and the platysma muscle are incised. The loose connective tissue layer

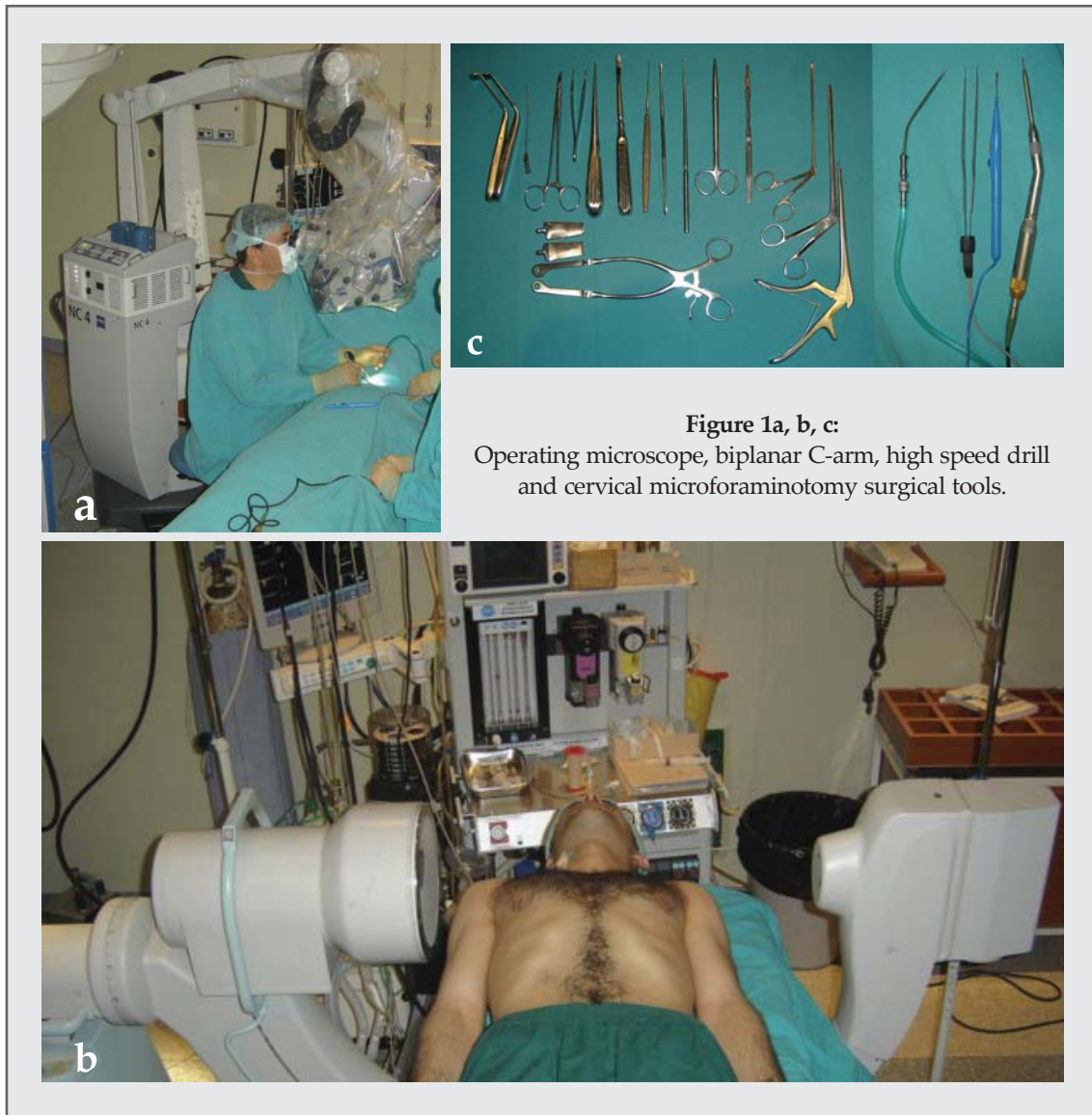


Figure 1a, b, c:
Operating microscope, biplanar C-arm, high speed drill
and cervical microforaminotomy surgical tools.

under the platysma muscle is cleanly undermined to provide space in which to work. A combination of sharp and blunt dissection is used to access the anterior column of the cervical spine. SCM muscle, carotid artery, and jugular vein are retracted laterally. Esophagus and trachea are retracted medially, and protected by a wide blade retractor. In this technique, retraction is minimal, because the surgical exposure remains laterally. The sympathetic chain is recognized under the prevertebral aponeurosis. The aponeurosis and sympathetic chain are retracted laterally. The medial portion of longus colli muscle is excised to expose the transverse processes of the upper and lower vertebrae

and the lateral aspects of the vertebral bodies. Before starting the drilling, the VA is identified, and a retractor is placed between VA and unciniate process while drilling (figure 4b). The VA occasionally enters the transverse foramen at a different level. Careful preoperative assessment of the VA in CT scans will aid in avoiding unexpected findings intraoperatively. The far lateral margin of the unciniate process and the medial portion of the transverse foramen of the superior vertebra are drilled. The unciniate process is not completely excised. The medial wall of the unciniate is preserved to keep the disc intact. The intervertebral foramen is fully opened (figure 4c). Disc frag-

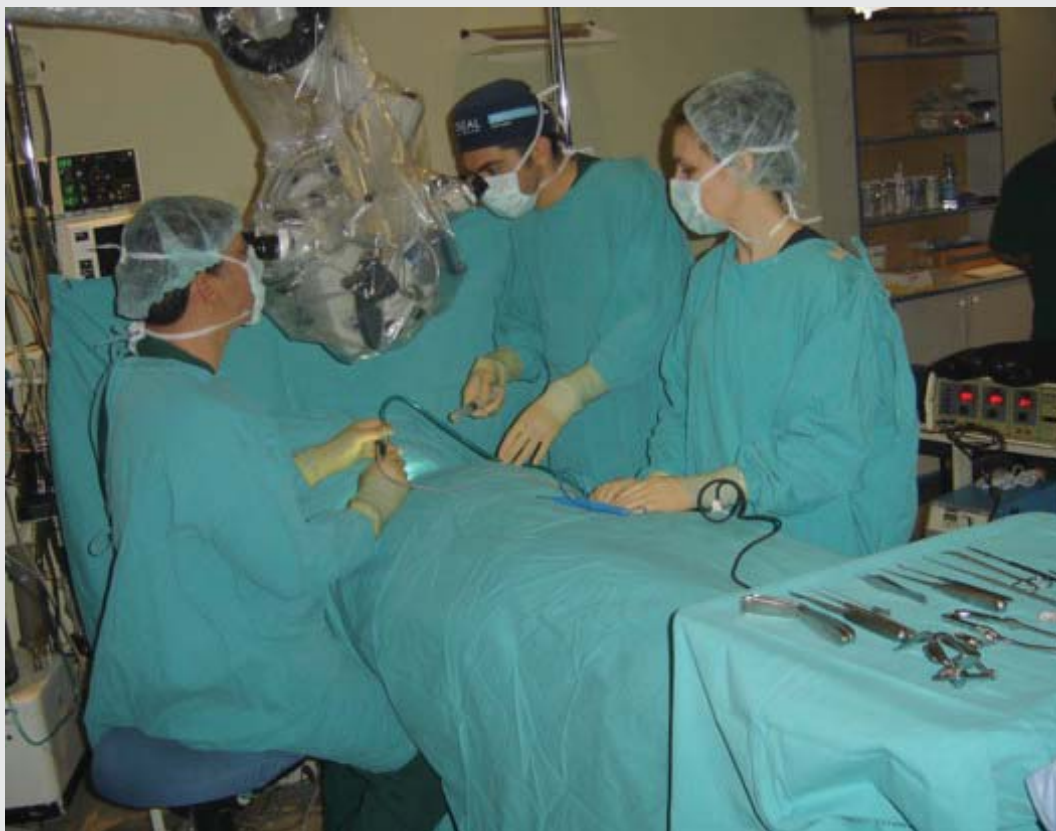

Figure 2:

Operating microscope is located opposite to the surgeon. The high speed drill is located at the nurse desk. The position of surgeon depends on the pathology of cervical spine. The surgical assistant is positioned opposite to the surgeon and operation technician or nurse is located between the surgeon and assistant.

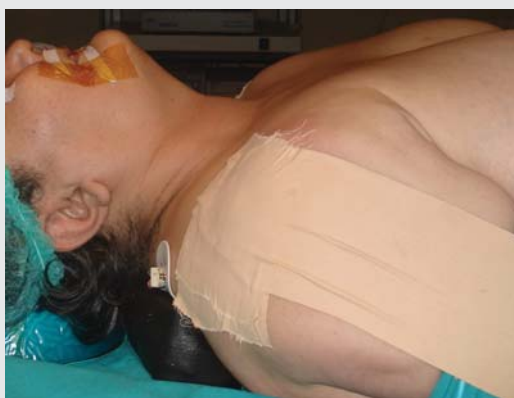

Figure 3a:

The supine position with a slight extension of the neck is suitable.

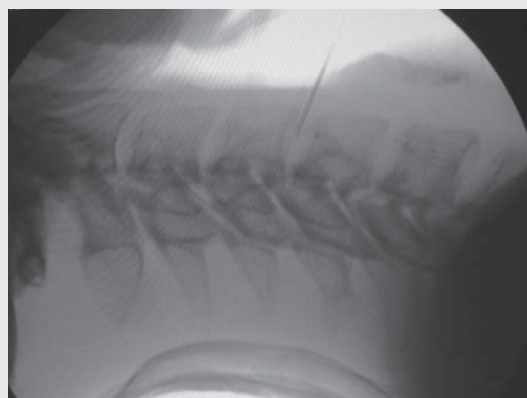

Figure 3b:

operation level is marked with C-arm.

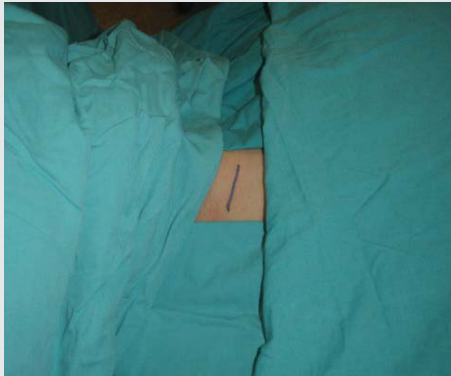


Figure 4a:
Transverse skin incision is made at the anterolateral neck along a skin crease.

ments and/or bone spurs are excised via a foraminotomy hole by using curettes. The nerve root is decompressed from its origin in the spinal cord to the point where it passes behind the VA laterally. The size of the hole that is made by drilling at the uncovertebral joint is usually approximately 4 to 5 mm wide transversely by 5 to 7 mm wide vertically (figure 4d). Neither bone grafting nor osteosynthesis is used.

The hemostasis should be obtained with a bipolar cautery and/or suitable chemical hemostatic gel foam agents can be used. There is no need to use a drain if you ensure from the hemosthesis. After the

irrigation of area, a routine closure of the platysma and skin is performed. The platysma is closed with reabsorbable 3-0 Vicryl stitches and subcutaneous layer of the skin is closed with suitable absorbable or non-absorbable stitches. Steri-Strips® or Dermabond® can be used to keep the skin edges closely for 5 to 7 day period (figure 4e).

5. Postoperative Care:

There is no need to use a postoperatively cervical collar. Muscle relaxants and non-steroidal anti-inflammatory drugs may be given if the patient has postoperative subjective complaints. The patients may be allowed to mobilize in the same day and discharged the day after surgery. The patient may return his job in 2 weeks after surgery if he is free from the postoperative problems.

6. Complications and Avoidance:

Axial pain: The risk of further spinal instability is smaller, because only the lateral part of the vertebral body is drilled and the anterior longitudinal ligament, posterior longitudinal ligament and the medial portion of uncinat process are preserved. In this technique, the risk of instability is mainly related to the resection of the nucleus pulposus of well hydrated discs (9,10). In the publication by Hacker *et al* (7), high incidence of recurrent herniation (13%) also seems to be due to the excessive iatrogenic disruption of the

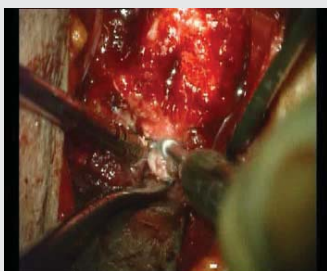


Figure 4b:
Medial portion of longus colli muscle is excised to expose the transverse processes of the upper and lower vertebrae and the lateral aspects of the vertebral bodies. The VA is identified, and a retractor is placed between VA and uncinat process while drilling.

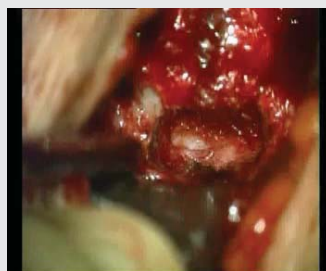

Figure 4c:
The medial wall of the uncinat process is preserved to keep the disc intact. The intervertebral foramen is fully opened.

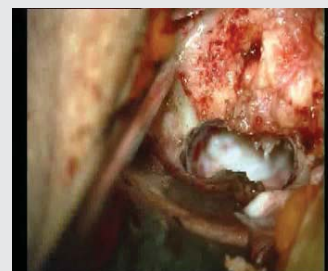

Figure 4d:
The size of the hole that is made by drilling is usually approximately 4 to 5 mm wide transversely by 5 to 7 mm wide vertically.

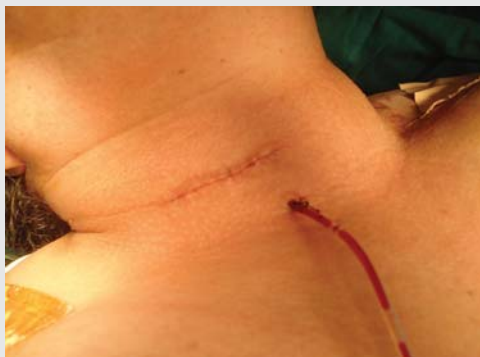

Figure 4e:
Subcutaneous layer of the skin is closed with suitable absorbable or non-absorbable stitches.

disc integrity. However, when the disc is already dehydrated and collapsed, as is commonly observed in spondylosis of the cervical spine, no grafting or osteosynthesis is necessary. This has well been demonstrated in cases of cervical spondylotic myelopathy treated by decompression with oblique corpectomy⁽⁹⁻¹²⁾. This procedure is most appropriate for older patients with more degenerated discs.

Temporary Horner's syndrome: The medial portion of longus colli muscle had only to be excised. Before dividing this muscle, the sympathetic nerve running under the aponeurosis must be identified and gently retracted laterally. If the sympathetic nerve is manipulated, the patient may exhibit Horner's syndrome postoperatively. However, if the main trunk of the sympathetic nerve is kept intact, no or mild Horner's syndrome occurs, and it recovers rapidly. Because the sympathetic nerve passes along the lateral portion of the longus colli muscle, to prevent the incidence of Horner's syndrome, the longus colli muscle is not incised laterally to the anterior tubercle of the transverse process. Transient Horner's syndrome occurred in 5.3%⁽¹³⁾.

Vertebral artery injury: VA injury is a rarely described complication. VA control permits the safe drilling of the lateral corner of the vertebral bodies and control of the distal nerve root. The VA oc-

asionally enters in to the transverse foramen of C5 instead of C6. In that case, the VA runs in the middle of the longus colli muscle at C6, which can be severed inadvertently when the C6-7 disc is surgically treated⁽¹⁴⁾. Injury to the vertebral artery during anterior approaches can be avoided by preoperative identification of anomalous arteries and by intraoperative attention while work very close to the VA. When the artery is injured, primary repair may be the optimal management strategy.

Injury of the cervical roots: Dural tears may be caused by accidental drilling. A surgeon must be mindful of the nerve root's proximity to the uncinate process while removing it with drilling.

Controlateral foraminal stenosis: Controlateral foraminal stenosis is uncommon at the level of the surgery. Anterior discectomy and fusion must be undergone.

7. Case Illustrations:

7.a. Neuroradiological evaluation:

Sagittal alignment was obtained by measuring the Cobb angle from the base of C2 to the superior endplate of C7. Spinal instability was quantitated by the increased intervertebral angle difference in flexion-extension of more than 12 degrees or displacement of the vertebral body over 3.5 mm in flexion⁽¹⁵⁾. Before discharged, the extent of drilling was evaluated by CT. Spine stability was demonstrated at 1.5, 3, 6 and 12 months by dynamic radiographies (flexion-extension).

7.b. Clinical Results

78.9% of patients with CSR demonstrated excellent results, 10.5% of patients demonstrated good results, and 5.3% of patient experienced a fair result and 5.3% of patient experienced worse result. Motor-weakness and sensory deficit improved dramatically immediately postoperatively, and improved to normalization in the majority of patients within 6 months⁽¹³⁾.

7.c. Natural Course:

Most of these patients had experienced advanced spondylotic changes with limited motion at the involved intervertebral motion segments⁽¹⁶⁾. The intervertebral motion segments are more likely expected to be fused eventually by advanced spondylotic

changes and by the surgical effect of substantial bone resection. Despite the advanced spondylotic changes, the preservation of motion units may still be a better surgical strategy than bone fusion (figure 5a, 5b).

8. References:

1. Wada E, Suzuki S, Kanazawa A, et al. Subtotal corpectomy versus laminoplasty for multilevel cervical spondylotic myelopathy: a long-term follow-up study over 10 years. *Spine* 2001; 26:1443-7.
2. Fessler RG, Steck JC, Giovanini MA. Anterior cervical corpectomy for cervical spondylotic myelopathy. *Neurosurgery* 1998; 43:257-65.
3. Lee TT, Manzano GR, Green BA. Modified open-door cervical expansive laminoplasty for spondylotic myelopathy: operative technique, outcome, and predictors for gait improvement. *J Neurosurg* 1997; 86:64-8.
4. Jho HD. Decompression via microsurgical anterior foraminotomy for cervical spondylotic myelopathy. Technical note. *J Neurosurg* 1997; 86:297-302.
5. Jho HD. Microsurgical anterior cervical foraminotomy for radiculopathy: a new approach to cervical disc herniation. *J Neurosurg* 1996; 84:155-60.
6. Johnson JP, Filler AG, McBride DQ, et al. Anterior cervical foraminotomy for unilateral radicular disease. *Spine* 2000; 25: 905-9.
7. Hacker RJ, Miller CG. Failed anterior cervical foraminotomy. *J Neurosurg* 2003; 98 (Suppl 2):126-30.
8. Kotani Y, McNulty PS, Abumi K, et al. The role of anteromedial foraminotomy and the uncovertebral joints in the stability of the cervical spine. A biomechanical study. *Spine* 1998; 23: 1559-65.
9. George B, Lot G. Oblique transcorporeal drilling to treat anterior compression of the spinal cord at the cervical level. *Minim Invasive Neurosurg* 1994; 37: 48-52.
10. George B, Zerah M, Lot G, et al. Oblique transcorporeal approach to anteriorly located lesions in the cervical spinal canal. *Acta Neurochir (Wien)* 1993; 121(3-4):187-90.
11. George B, Gauthier N, Lot G. Multisegmental cervical spondylotic myelopathy and radiculopathy treated by multilevel oblique corpectomies without fusion. *Neurosurgery* 1999; 44:81-90.
12. Koç RK, Menkü A, Akdemir H, et al. Cervical spondylotic myelopathy and radiculopathy treated by oblique corpectomies without fusion. *Neurosurg Rev* 2004; 27:252-8.
13. Koç RK, Menkü A, Tucer B, et al. Anterior cervical foraminotomy for unilateral spondylotic radiculopathy. *Minim Invas Neurosurg* 2004; 47:186-9.
14. Jho HD. Failed anterior cervical foraminotomy. *J Neurosurg* 2003; 98 (Suppl 2):121-5.

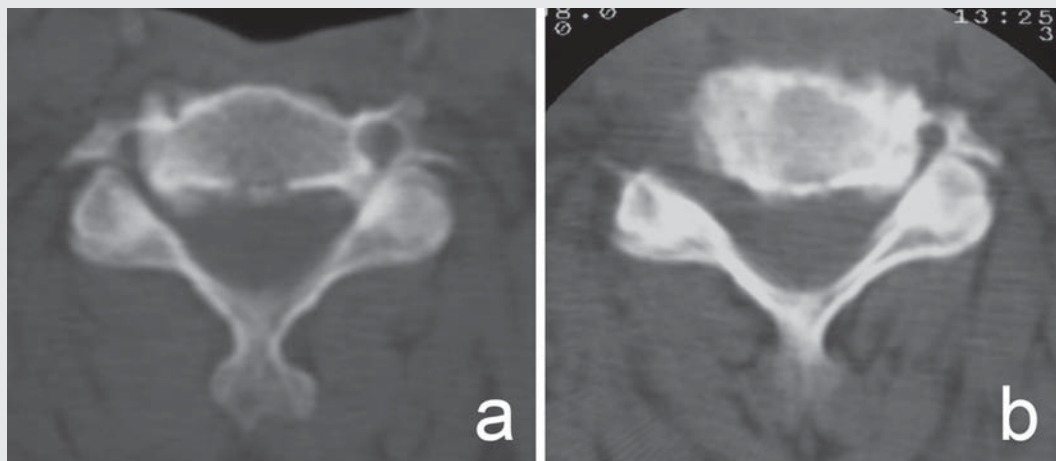


Figure 5a, b:

Most of these patients had experienced advanced spondylotic changes with limited motion at the involved intervertebral motion segments.

Anterior Cervical Microforaminotomy

15. White AA 3rd, Johnson RM, Panjabi MM, et al. Biomechanical analysis of clinical stability in the cervical spine. *Clin Orthop* 1975; 109: 85-96.
16. Jho HD. Spinal cord decompression via microsurgical anterior foraminotomy for spondylotic cervical myelopathy. *Minim Invasive Neurosurg* 1997; 40: 124-9.

3f

ANTERIOR CERVICAL MICRODISCECTOMY AND FUSION

Ali Fahir Ozer MD, Murat Cosar MD PhD

1. Introduction:

Anterior approach of the cervical spine was described by Cloward in 1958⁽¹⁾. The results of microscope applied spine surgery are very optimistic. Partial and/or complete discectomy and osteophyte resection is performed to decompress the neural canal and foramen via the operating microscope techniques. Operating microscope provide us magnification, improves illumination and reduces the amount of bone resection required to expose the herniated disc especially osteophytes of the vertebral corpus. Anterior cervical microdiscectomy is performed in main three clinical and pathological situation; soft disc, cervical spondylosis and ossified posterior longitudinal ligament just under the disc level. Anterior approach is also used to decompress the anterior wall of foramen instead of posterior part. In this situation, it is not necessary to remove all discs. Extreme lateral approach is performed directly onto the neural foramen.

A lesion at the C2-3 level may compress to C3 nerve root with pain and causes sensory changes at the back of the neck, mastoid process or pinna of the ear. C4 nerve root compression cause sensory changes and pain at the back of neck, over the scapula and anterior chest. Compression of the C5 nerve root often causes pain at the neck, tip of the shoulder and anterior arms. Sensory changes are localized to the lateral portion of the skin overlying deltoid muscle. C5 nerve root innervate deltoid biceps muscle. Deltoid is almost entirely innervated by C5; the biceps has dual innervations from both C5 and C6. Biceps reflex can be diminished because of two nerve roots innervations.

C5-6 disc herniation will affect the C6 nerve root associated with pain in the neck, shoulder, medial border of scapula, lateral arm and dorsal forearm. Sensory loss is often noted in the distribution of lateral

fore arm as well as thumb, index finger and occasionally radial half of the middle finger. Muscle testing includes biceps muscle and wrist extensors. Biceps and brachia-radial reflex are lost or diminished. Pathology of C7 nerve root will cause pain at the neck, shoulder, medial border of the scapula, lateral arm and dorsal fore arm. Sensory changes are usually confirmed to the index and long fingers. Muscle testing of C7 level involves the triceps, wrist flexors and finger extensors. Triceps tendon reflex are involved at the pathology of C7 nerve root. Compression of the C8 nerve root will cause sensory changes in the ring and little finger. Manual motor testing includes the finger flexors (grip) and intrinsic muscles of the hand.

Foraminal herniations can be diagnosed easily with MRI. The annular defects, bulging and/or free fragments are seen in neural foramina. If the clinical examinations are in accordance with MR scans, it is not necessary to perform an extra EMG examination. Cervical myelopathy can be precipitated by either a large disc herniation or more commonly by severe pathological antite.

Spondylotic changes may occur with or without a congenitally narrow spinal canal. Most patients are usually unaware of the precise onset time of the symptoms. Symptoms include the deterioration in gait and abnormal dexterity, generalized weakness and/or urinary urgency or frequency. A minor trauma may precipitate the onset of symptoms.

2. Patient Selection and Indications:

There are two different indications for anterior cervical discectomy. The first is the intractable pain of the patient with and/or without neurological deficit and unresponsive to medical treatment. The second is the spinal cord compression. The cervical spine is

mobile in young patients. If there is spinal stenosis, the mean diameter of the spinal cord becomes equal to the spinal canal diameter and the squeezing of the spinal cord is unavoidable. Daily micro traumas cause spinal cord malaises slow by slow. With aging, mobile spine becomes immobile. Frozen movement of functional segment causes fewer traumas on spinal cord and less potential dangerous when it is compared with young patients. In elderly age, if there is a fusion of functional segment with spinal cord malaises just in front of it, the surgical intervention is not necessary.

Two diagnostic tools lead to us to decide surgery. The first is dynamic MRI and the second is dynamic SEP and MEP. Dynamic MRI shows normally motion of spinal cord with harmony of spinal canal, and there is no change a size and shape of spinal cord during the flexion and extension movements. However, dynamic stenosis at hyperextension position causes to squeezing of spinal cord. The spinal cord seems to be hourglass. In hyperflexion position, the diameters of spinal canal and cord are normal.

Most of these patients' have normal SEP and MEP in neutral position of neck, but in hyperextension position, because of the squeezing of spinal cord electrophysiological measurements is disturbed.

3. Contraindications:

It will be better not to choose anterior cervical approach for the cases with dorsal compression of neural structures and isolated traumatic disruption of the posterior elements. Thyromegali or other pathologies of the surgical area can limit the surgical approach.

4. Surgical Procedures:

4.a. Surgical Equipment

Biplanar C-arm, operating microscope and cervical microdiscectomy equipment are the main parts of this surgical procedure (Figure 1a). We also preferred Ozer's retractor in most of our operations (Figure 1b) ^(2,3). The sterilization equipment for cervical spinal surgery such as betadine, alcohol solution, drape and sterile towel are also prepared.

4b. Operating Room Set up

The C- arm and operating microscope is located opposite to the surgeon (Figure 2). The spine surgeon is positioned according to the dominant hand. The right side of the patient is suggested for the right handed surgeons. The surgical assistant is positioned opposite to the surgeon and operation technician is located between the surgeon and assistant.

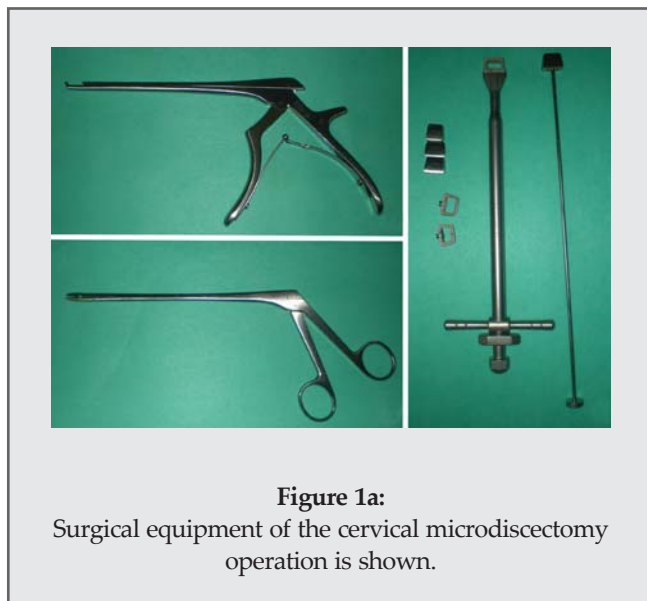
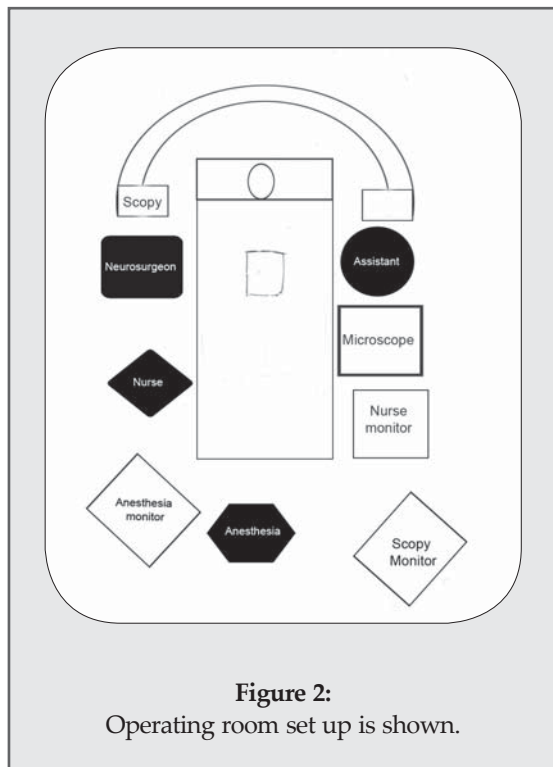


Figure 1a:
Surgical equipment of the cervical microdiscectomy operation is shown.



Figure 1b:
The latest design of Ozer's retractor.



4.c. Patient positioning:

The supine position and a radiolucent spine operative table are suitable for anterior cervical microdiscectomy operations (Figure 3). A slight extension position of the neck with a rolled towel will facilitate the visualization and expand the discectomy level. The operation area is washed and draped in a usual sterile fashion after the correction of operation level with C-arm.

Before the operation, suitable antibiotics are given in operation room. The most important point is to avoid manipulating neck during endotracheal intubation in patients who has spinal canal stenosis. Anesthesiologist should check the maximum degree of cervical flexion and extension tolerated by the patient before operation.

4.d. Surgical Technique:

A transverse incision is made at the appropriate level (Figure 4a). Platysma layer is opened and dissected cranially and caudally. Sternocleidomastoid (SCM) muscle is found and through the medial border vessel-nerve

packet is found and carotid pulsation is seen and felt by finger. It is reached to prevertebral fascia with finger dissection between the vessels-nerve packet and tracheoesophageal complex. Sometimes the superficial fascia has bands between the SCM muscles, vessels nerve packets.

During the finger dissection of thin layered bands, when they come together, they may act as strong rope and defense to the manipulation. So, this defense mechanism may prevent the exposure of the surgical area. Additionally, careful dissection of these bands are necessary, in order to avoid damage of superior laryngeal nerve. It is also difficult to set up the retractors because of the small surgical area. For these reasons, all of these bands must be determined and cut with a maximum care on neural structures.

Tracheoesophageal complex retracted medially and prevertebral fascia are opened and disc annulus, corpus vertebrae are seen in midline and longus colli muscles are straight lie down along the lateral border (Figure 4b,4c).

Correct level are marled with a little pin and confirmed by C-arm. And our designed retraction is placed just over the disc level and blades are screwed (2,3). Advantage of this retractor is preventing surrounding tissue come over surgical area at the same time to save the damage of tissues. And this retractor acts as a vertebrae sprider. We think that it is more practical as compared with Caspar retractor (4).

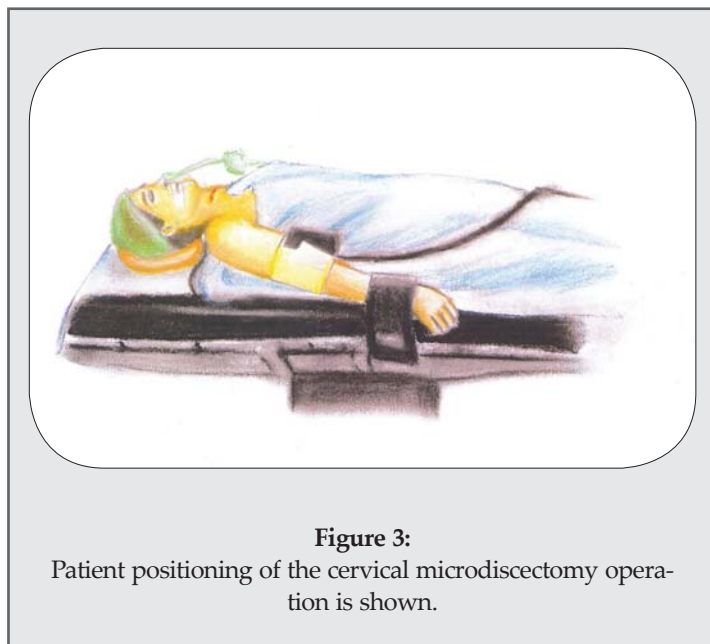

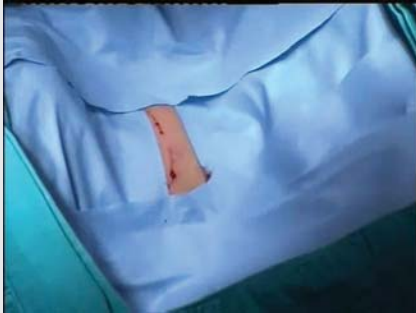


Figure 4a:
The incision of cervical microdiscectomy operation is shown.

After these procedures, longus colli muscles are dissected laterally and front border of annulus are betrayed. Anterior osteophytes are cleaned and incision is made to the annulus.

Under the microscopic magnification and with the assistance of high speed drill cartilage endplates, osteophytes are removed. Moving the head of microscope posterior border of vertebrae and both foramen are opened. Free fragments of the herniated disc can be found among the layers of posterior longitudinal ligament (Figure 4d). It is found and removed. Sometimes free fragments can be localized behind the posterior longitudinal ligament. It is necessary to control this area, if it is not found, a fragment can be seen

in the control MRI. Foramens are opened and fragments should be checked with nerve hooks.

If we stop the operation without doing anything it is called "simple discectomy". Bone graft alone or bone graft with cage, bone graft with plate or disc prosthesis can be placed after the discectomy.

4.d.1. Bone graft:

The cartilage endplates are curetted or drilled after simple discectomy. The osteofites compressing the neural structures are excised with Kerrison rongeurs, curettes and high speed drills. A cave for bone graft is prepared in the lower and upper vertebrae corpuses. The appropriate sized bone graft is chosen for disc level. The spongy part of the upper and lower surfaces of the bone graft must contact to the upper and lower surfaces of vertebrae corpus at the disc level. More surface area means the increase of fusion and decrease of pseudoarthrosis. After the bone graft is located to the prepared disc space, it is controlled with biplanar scopy.

The anterior surfaces of the upper and lower corpuses are smoothed with high speed drill or curettes for anterior plating. Anterior plates prevent the pull out of the bone graft and provide it stable in the disc space until the fusion process. There are many different sized and shaped anterior cervical plates in the marketing. The appropriate sized and shaped plate is located on the anterior surfaces of the prepared corpuses and screwed which are at the up-

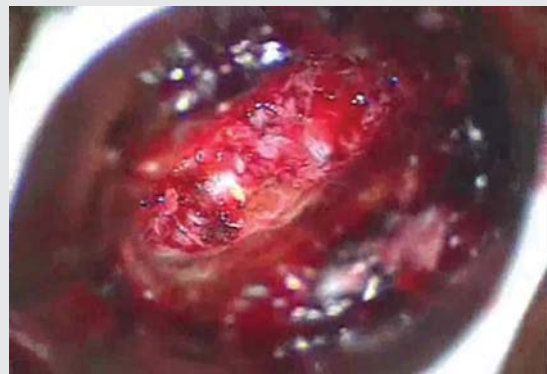
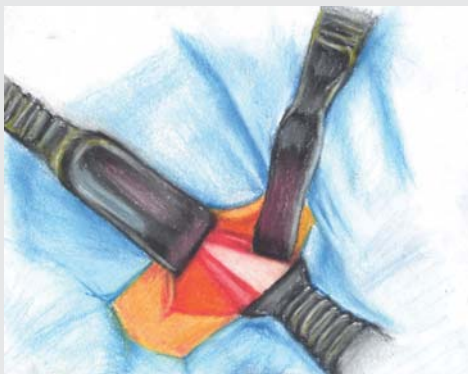
Figure 4b,4c:
Tracheoesophageal complex, prevertebral fascia, disc annulus, vertebra corpus and longus colli muscles are shown (the microscope photo and drawing).

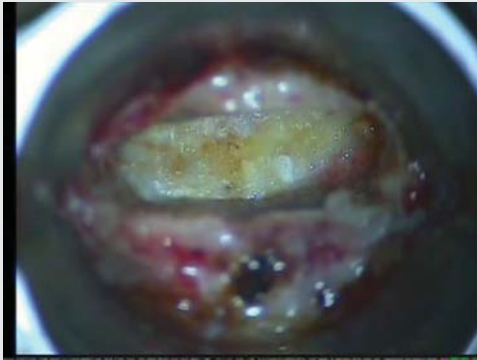

Figure 4d:
Microscope photo of cervical microdiscectomy is shown.

per and lower of the disc space under biplanar fluoroscopy (Figure 4e).

4.d.2. Cage:

The upper and lower cartilage endplates are curetted or drilled after simple discectomy and cor-puses of upper and lower vertebrae are exposed. Posterior and Lushka joint based osteofites are excised with curettes and high sped drills. After these processes, the appropriate cave is prepared at the upper and lower surfaces of the disc space for the cage. The size of disc space is measured and appropriate cage is experienced for the disc space. The cavity inside the cage is filled with mixture of bone graft and bone morrow. The cage is located into the disc space and controlled with biplanar fluoroscopy.

Recently, we use knifed-PEEK cages which can provide the stability with its knives is sticked after 90° switching to the upper and lower vertebrae cor-puses (Figure 4f).

4.d.3. Prosthesis:

The cartilage endplates and osteofites are curetted or drilled after simple discectomy. The upper and lower surfaces of the disc space are prepared for prosthesis. There are a few kind of disc prosthesis in the marketing and all of them have own hand tolls and different preparing instructions. Although, they are different marks, their base functions have similarity.

At first, the size of disc prosthesis is measured according to the size of disc space. And then, the cavity of disc prosthesis is prepared with appropriate tools of prosthesis set. During these processes, the simetry of the surgical area is controlled with bilanar fluoroscopy and microscope.

As a general rule for disc prosthesis, the two parts marked disc prosthesis are combined as one part marked disc prosthesis during performing the apparatus. And then, the disc prosthesis is inserted to the disc space under the control of biplanar fluoroscopy. We used PCM cervical disc prosthesis for our chapter (Figure 4g).

Conclusion:

The platysma layer, subcutaneous tissues and skin are stitched after the homeostasis of the surgical area. It is known that subsidence can occur even placed bone graft after cage and prosthesis^(5,6). If it is placed vertebral margin subsidence can occur little on the other hand can protect the alignment.

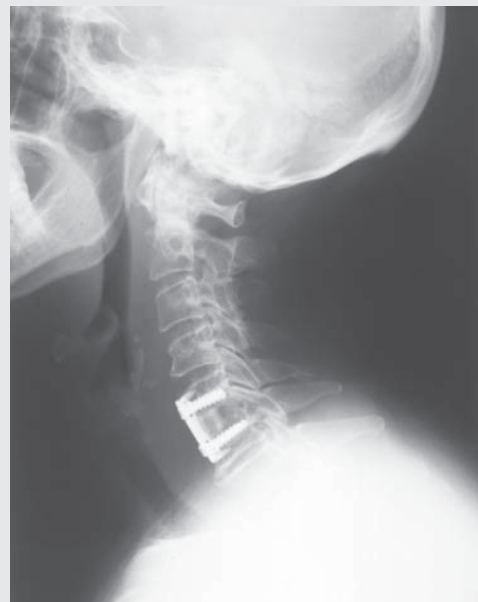

Figure 4e:
The lateral cervical graphy of bone graft + plate performing after cervical microdiscectomy is shown.

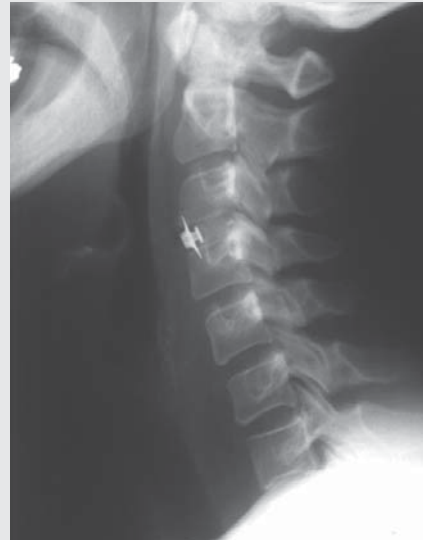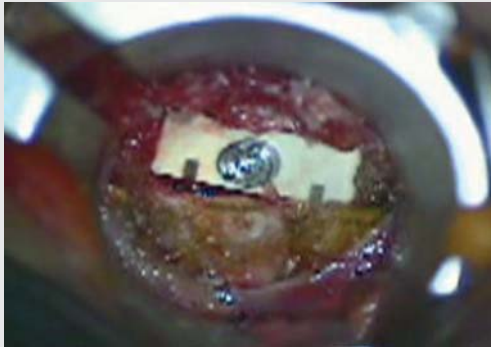


Figure 4f:
The microscope photo and lateral cervical graphy of cage insertion after cervical microdiscectomy is shown.

5. Postoperative Care:

A soft collar can be applied to the patient during wake up time at the operating table and continued for 4 weeks, if a fusion material is implanted. A muscle relaxant and non-steroidal anti-inflammatory drugs are given systematically. The patients are allowed to mobilize in the same day and discharged the day after surgery. The patient may return his job in 2 weeks after surgery.

6. Complications and Avoidance:

It is known that familiar with surgical anatomy of the neck, careful patient selection, preoperative planning of the surgery will facilitate the surgery and prevent the complications. Using prophylactic antibiotics and care on sterility will decrease the infections.

Due to the anatomy of the neck, carotid artery, jugular vein, vertebral artery, superior and inferior

thyroidal arteries has potential of injury. The identification of carotid sheath and feel under the fingers of surgeon will avoid the surgeon from a possible injury. Avoidance from the prolonged retraction of carotid artery will also prevent the possible embolic complications depends from the carotid artery. Careful dissections of muscles and respect to the anatomy of the neck will avoid the surgeon from the injury of superior and inferior throi-

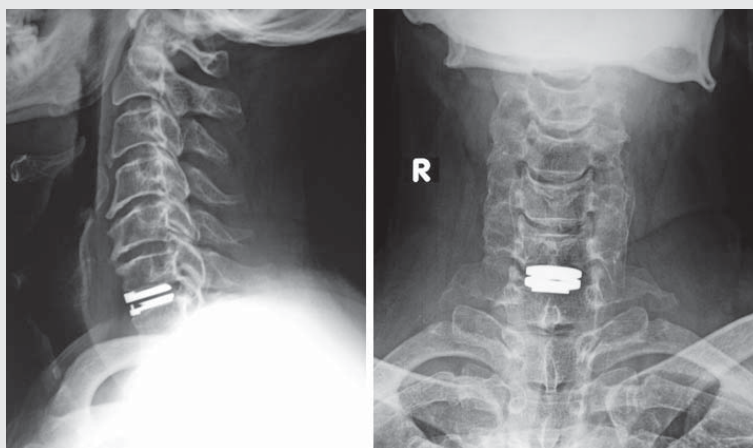


Figure 4g:
The anteroposterior and lateral cervical graphy of cervical disc prosthesis is shown.

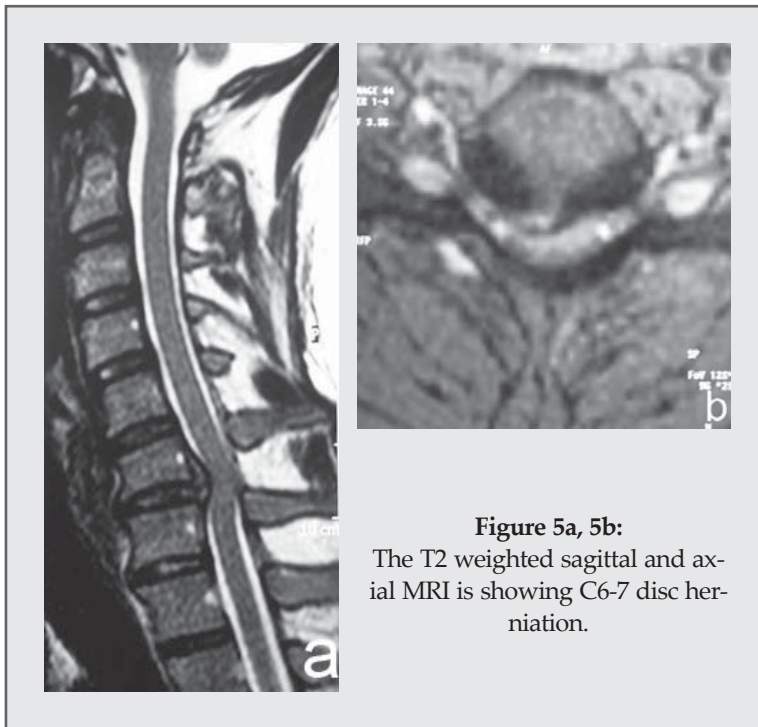


Figure 5a, 5b:
The T2 weighted sagittal and axial MRI is showing C6-7 disc herniation.

7. Case Illustrations:

Case 1:

A 35 year old man admitted to the physical therapy and rehabilitation clinic with complaints of severe neck and upper right extremity pain for 1 month. The neuroradiological images of the patient revealed C6-7 disc herniation (Figure 5a, 5b, 5c). Medical treatment and physical therapy was suggested to the patient. The patient admitted to the neurosurgery clinic because of the increasing of the complaints. The neurological examination revealed motor force regression at the right hand and numbness at the fifth finger. C6-7 microdiscectomy was performed to the patient and cervical disc pro-

thesis insertion was added to the operation (Figure 5e, 5f).
dal arteries. To care on the uncinat processes and behave as a lateral borderline of microdiscectomy operation may prevent the vertebral artery injuries and sympathetic nerve injuries and also Horner's syndrome.

The careful surgical technique and respect to the surgical anatomy will prevent the spinal cord and neural root injuries beside possible hypoglossal, spinal accessory, phrenic, auricular and cutaneous nerves. Gentle retraction of the thyroid gland, esophagus and trachea will prevent the injury and postoperative dysphasia and airway obstructions due to edema. Dural tears and cerebrospinal fluid leakage are also the possible complications of ACMF.

The failure of plate, bone graft, cages, and disc prosthesis can occur in the following processes after operation.

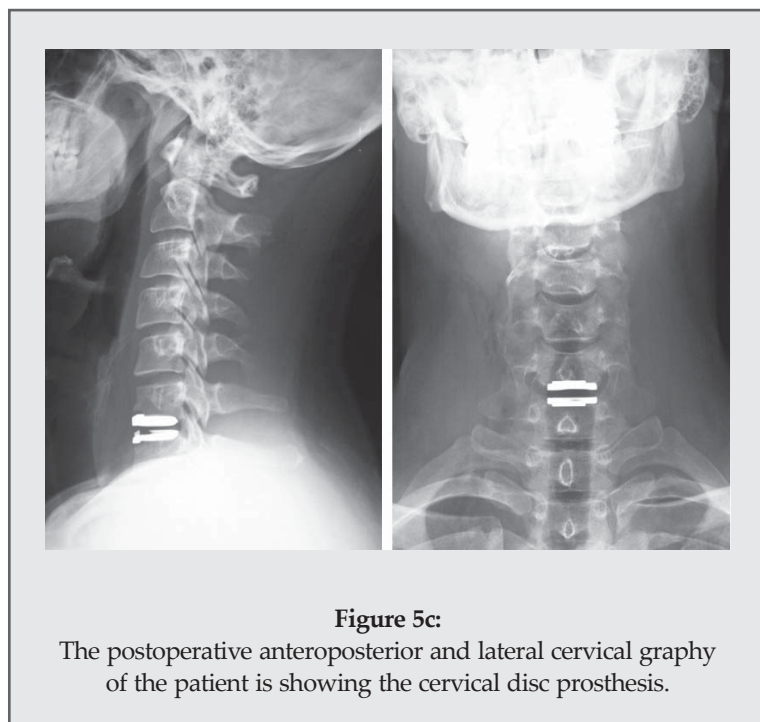


Figure 5c:
The postoperative anteroposterior and lateral cervical graphy of the patient is showing the cervical disc prosthesis.

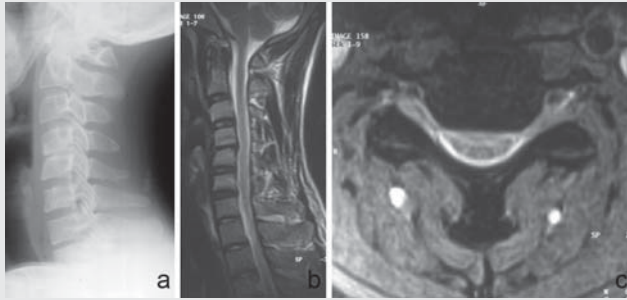


Figure 6a:

The lateral cervical graphy of the patient is showing the collapse of C4-5 vertebra disc level after the first operation.

Figure 6b, 6c:

The T2 weighted sagittal and axial MRI is showing the collapse of vertebra at C4-5 disc level and anterior angulation.

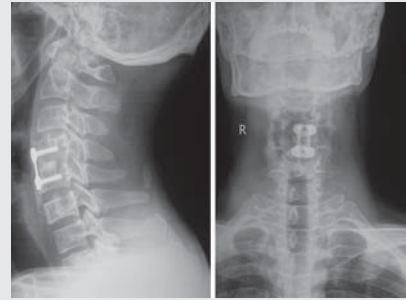

Figure 6d:

The anteroposterior and lateral cervical graphy showing the fusion after anterior plating.

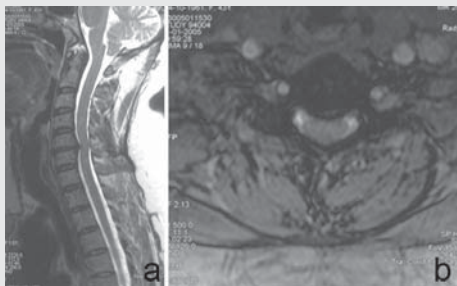


Figure 7a, 7b:

The T2 weighted sagittal and axial MRI is showing C5-6 disc herniation.

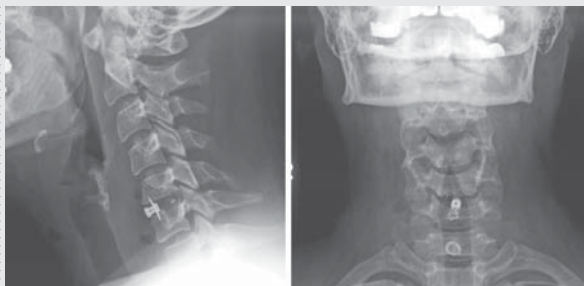


Figure 7c:

The anteroposterior and lateral cervical graphy of cervical cage insertion after cervical microdiscectomy is shown.

Case 2:

A 25 year old man had admitted to the neurosurgery clinic with complaints of neck and right upper extremity pain. His upper extremity pain had improved after operation. However, the neck pain worsened although additional physical therapy and medical managements.

He readmitted to the neurosurgery clinic three months after the first operation. The radiological images revealed pseudoarthrosis and segmental instability at the C4-5 level (Figure 6a, 6b, 6c). C4-5 microdiscectomy was performed to the patient and bone graft and anterior plating was added. The pa-

tient was uneventful after operation and fusion was detected at the post operative plain graphies (Figure 6d, 6e, 6f).

Case 3:

A 35 year old woman admitted to the neurosurgery clinic with complaints of neck pain, numbness and prickles in both hands. The radiological images revealed c5-6 disc herniation (Figure 7a, 7b). The operation was planned after medical and physical therapy managements. The cervical cage was inserted to the patient after anterior cervical microdiscectomy and discharged at the second day (Figure 7c,7d).

8. References:

1. Cloward RB. The anterior approach for removal of ruptured cervical disks. *J Neurosurg* 1958; 15(6): 602-617,
2. Ozer AF. A novel retractor for the anterior approach to the cervical spine. *Neurol Res* 1999; 21(1): 43-44,
3. Ozer AF. The latest design of Ozer cervical retractor. *Neurol Res* 2008 ;30(7): 695-6.
4. Geisler FH, Tamargo RJ, Weingart JD. Modifications to the transverse Caspar cervical retractor blades optimized for a single-level anterior cervical discectomy. *J Spinal Disord* 1993; 6(1):57-9.
5. Cosar M, Ozer AF, Iplikcioglu AC, Kosdere S, Sasani M, Bozkus H, Khoo LT, Sarioglu AC. The Result of β -Tricalcium Phosphate Coated Hydroxyapatite (β -TCP/HA) Grafts for Interbody Fusion after Anterior Cervical Discectomy. *J Spinal Disord Tech* 2008; 21(6):436-41.
6. Oktenoglu T, Cosar M, Ozer AF, Iplikcioglu C, Sasani M, Canbulat N, Bavbek C, Sarioglu AC. Anterior cervical microdiscectomy with or without fusion. *J Spinal Disord Tech* 2007; 20(5): 361-368.