



MICROLUMBAR DISCECTOMY

Ali Fahir Ozer MD, Murat Cosar MD PhD

1. Introduction:

Microlumbar discectomy is one of the debatable topics of spine surgery. The most important question is “Can we decrease the unsatisfactory results with microsurgery?” If we look at the literature, we can see the successful results with microsurgery. There is no doubt microsurgery helps some parameters such as short operation time, minimal tissue damage, short hospital stay and in many cases short rehabilitation duration before the job ⁽¹⁾. But in some literature findings in overall results there are no big differences between the discectomy with microsurgery and microdiscectomy ⁽²⁾. The important question is which factors effect on the unsuccessful results? Are these patient’s history, neurological examination and MRI evaluation?

When the patient tells his/her history, two points is remarkable. The first point is the previous low back pain before the extremity pain. The patient gives at least two, three or more sudden low back pain attacks or complains constant back pain in daily life as least amount one year. The second point is the sudden onset history of low back pain and leg pain. Examination can show a mild to severe neurological deficit either one side or both side. Neurological deficits of the patients strongly effect our decision under a perspective of medical to surgical treatment.

In patients with L5 radiculopathy, weakness of the extensor hallucis longus muscle can be seen. L5 sensory loss can be detected on the sensory examination of the gluteus muscles. The patient may have sciatic pain and show step page on affected side. Gluteus medius muscle can also be weak in patients with L5 radiculopathy. In this situation, the patient shows

disordered walking pattern on the affected side. Pelvis may glissade when the patient tries to walk. A discrete mapping of L5 dermatome may be possible on sensory examination of the patient.

In patients with S1 radiculopathy, the strength of the triceps surae group can be decreased and ankle Jerk is diminished. Additionally, the examination of the foot shows the weakness of its push. The patient has sciatic pain and complains to drag the foot along the ground while walking.

Upper lumbar disc herniations are rare and it would expect weakness in the quadriceps muscle. Knee jerk is diminished and the patient complains discharge feelings of affected knee while walking. On sensory examination, there may be a discrete mapping of L4 or upper nerve roots. Sciatic or femoral tension signs are seen in most individuals who present with lumbar disc herniations.

The development of MRI technology is the corner stone of the diagnosing of lumbar disc disease. We can see the annular rupture of the disc on MRI. The localization and size of annular rupture are important. Wide based annular tear and laxity of posterior annulus can easily be diagnosed in MRI scans and it is related to severe low back pain attacks even in the absence of nerve root compression findings. A little tear including all layers of annulus is always better than laxity of wide based annulus.

2. Natural History:

A natural history of a disc disruption leads up to healing or instability. Some factors affect this process. Especially, strength of paravertebral and abdominal muscles play an important role of healing. If these

muscles are strong enough or the patient showed a great ability to make strong these muscles after a painful attack, probability of a healing process is always high ⁽³⁾.

On the other hand, overweight, hard work stereotype daily life can promote instability of the disrupted disc, or not, a disrupted disc can be a painful disc in the length of the time ⁽⁴⁾. Sometimes, painful period can start after the simple discectomy operation. Every simple discectomy operation has recurrence rate changing between %3-15, and instability rate % 20 in the next ten years duration after the procedure. This means that % 30 of the patients have painful syndromes in a short or long time periods after discectomy.

3. Indications and Contraindications:

Patient selection and/or preoperative evaluation of the patients should be carefully evaluated, in order to increase patient's satisfaction after the microdiscectomy. We prefer simple discectomy for the patients who have only small rupture of the annulus with or with or without extruded disc fragment. If there is an extended fragment material which is located among the annulus layers, we open a small opening on the layer and remove the fragment. After these procedures, this small lax area is shrunk with bipolar coagulation.

In young and athletic patients, we emphasize microdiscectomy, because strong paravertebral muscles will share loading with spinal column. In wide based annulus laxity with herniation, the probability of unsatisfactory results will be quite high; therefore we support microdiscectomy with a dynamic stabilization. In elderly people or patients who have no sport in their life with weak paravertebral muscles, microdiscectomy with dynamic stabilization is a good choice for patients' satisfaction.

4. Surgical Procedures

4.a. Surgical Equipment

The sterilization equipment for spinal surgery such as betadine, alchole solution, drape and sterile towel are prepared. The C-arm, surgical microscope and

microdiscectomy equipment are the main part of this surgical procedure (Figure 1a, 1b).

4b. Operating room set up

The C- arm and monitor is placed according to the localization of the surgeon, the opposite side of the surgeon should be preferred (Figure 2). The microscope should be located at the opposite side of the surgeon. The spine surgeon, surgical assistant and operation technician are located according to the left or right side of the surgical area.

4.c. Patient positioning

Patient should receive intravenous antibiotics in the operating room prior to surgery. Standard operation

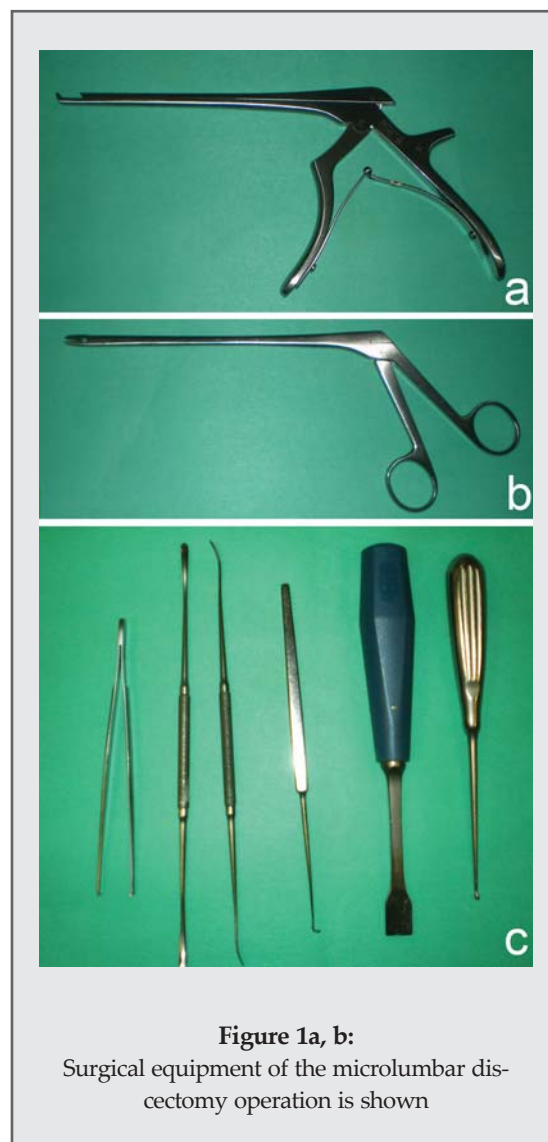


Figure 1a, b:
Surgical equipment of the microlumbar discectomy operation is shown

table can be used. The patient should have prone position. Careful inspection should be done to the eyes, ulnar nerves, and genitalia for the males, and breast for the females to ensure that excessive pressure does not exist. Abdominal viscera and vessels should be checked. The surgical area is propped with an antiseptic solution and covered with sterile clothes. The disectomy level should be found with C-arm before the operation and incision line is marked (Figure 3).

4.d. Surgical Technique

The length of the incision line changes between 1,5 - 2 cm, the lower point of incision should be the upper point of lower spinal process (Figure 4a). While performing incision, subcutaneous tissue should not be destroyed to avoid fat tissue necroses. Fascia should be opened just lateral border of spinous process to keep supraspinous ligament.

After dissection of the muscle tissue on the spinous process and lamina, it should be cared to the two important points. First of them is to save the capsular ligament and second is to leave intact the interspinous ligament; therefore retractor should not be forced against interspinous ligament.

The next step is to save ligamentum flavum ⁽⁶⁾. In L5-S1 level, the ligamentum flavum is opened from the medial side to lateral as a flap like C and fixed with a spinal needle (no: 18) to the lateral wall. Under the microscope magnification, epidural fat tissue retracted medially with nerve root (figure 4b,4c). This

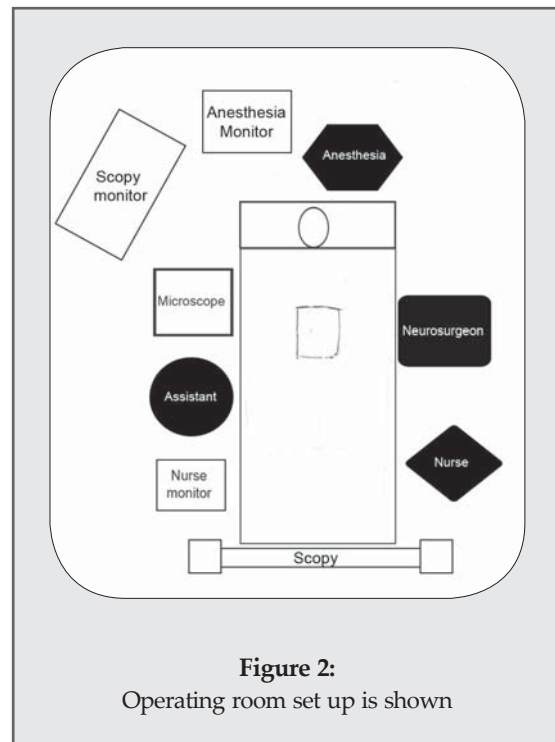


Figure 2:
Operating room set up is shown

procedure should be performed gently, because there is a very thin layer to keep the fat tissue. If this layer is opened, the dispersed fat tissue can prevent to see the nerve root. The thin layer should be opened just under the nerve root. Some epidural veins can be seen and coagulated with bipolar. After these procedures, disc annulus can easily be found under the nerve root and disectomy is performed (figure 4d,4e). After the

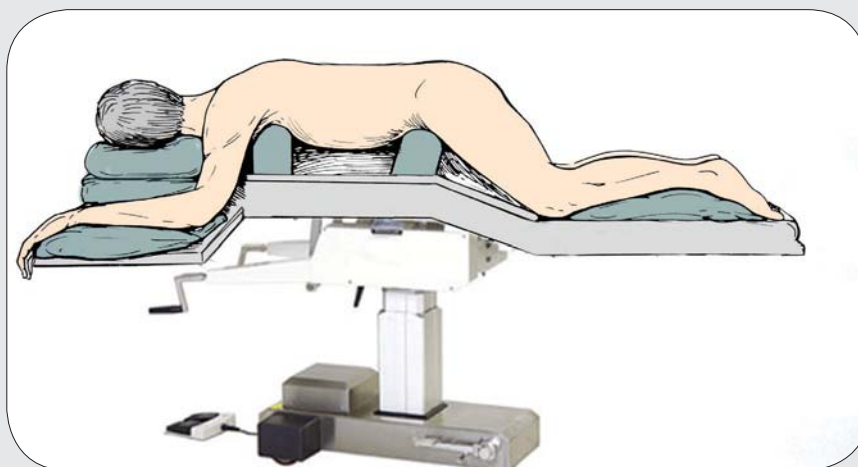


Figure 3:
Patient positioning of the microlumbar disectomy operation is shown

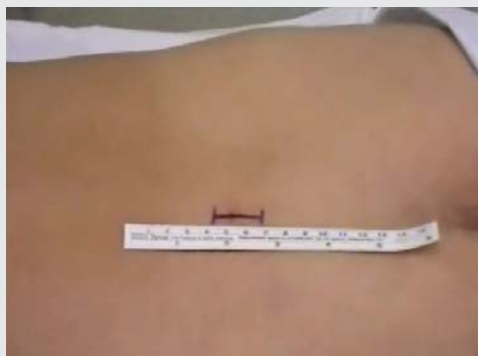

Figure 4a:
The incision length of the microlumbar discectomy operation is shown

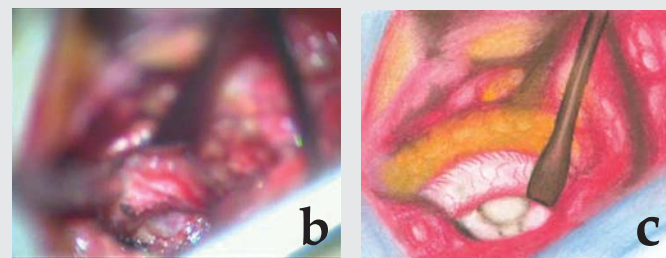


Figure 4b, 4c:
Epidural fat tissue, nerve root and lumbar discectomy is shown (the microscope photo and drawing)

discectomy, ligamentum flavum is placed on the epidural fat tissue. The fascia is sutured and skin is closed with subcutaneous sutures.

5. Postoperative Care:

The patient should be kept on the bed for six hours after operation. The mobilization and oral food intake of the patient should be started after six hours. Analgesics can be administered to the patient if they need. The patient can be discharged at the same day or

the day after operation. We offer one week relaxation time at home. After the relaxation time period, the patients are allowed to begin their job slow by slow. We recommend low back exercise program after 45 days of operation.

6. Complications and Avoidance:

Nerve root injuries, cerebrospinal fluid leakage after dural tear, major vessels injury are rare but major complications of the microlumbar discectomy. Maximum care to the sterility will decrease rate of infection.

7. Illustrative Case:

30 years old female patient in complaining with back and left lower extremity pain. The duration of complains was about 2 month and he had no benefit with medical treatment and physiotherapy program. Neurologic examination revealed weakness of plantar flexion and loss of ankle jerk. S1 dermatomal loss was found.

MR scan revealed L5-S1 disc herniation (Figure 5a,5b). L5-S1 microlumbar discectomy was performed. The patient was uneventful and discharged at the second day. She turned back her job two weeks after operation.

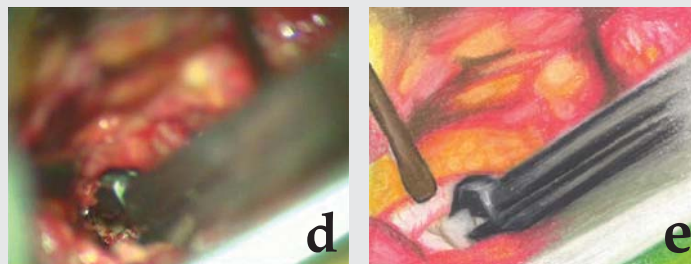

Figure 4d, 4e:
Microlumbar discectomy is shown (the microscope photo and drawing)

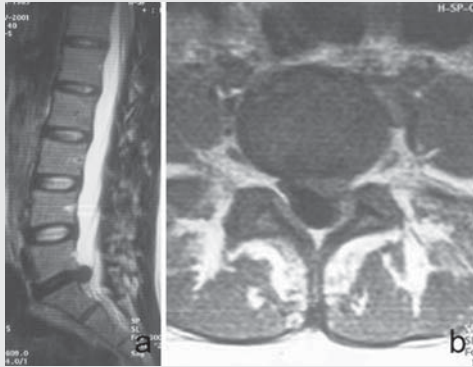


Figure 5a, 5b:
T2 weighted sagittal and axial MRI scans showing the L5-S1 disc herniation at the left side.

8. References:

1. Ozer AF, Oktenoglu T, Sasani M, Bozkus H, Canbulat N, Karaarslan E, Sungurlu SF, Sarioglu AC. Preserving the ligamentum flavum in lumbar discectomy: a new technique that prevents scar tissue formation in the first 6 months postsurgery. *Neurosurgery* 2006; 59 (1 Suppl): 126-33.
2. Maroon JC. Current concepts in minimally invasive discectomy. *Neurosurgery* 2002; 51 (5 Suppl): 137-145.
3. Bajek S, Bobinac D, Bajek G, Vranić TS, Lah B, Dragojević DM. Muscle fiber type distribution in multifidus muscle in cases of lumbar disc herniation. *Acta Med Okayama* 2000; 54(6): 235-241.
4. Liuke M, Solovieva S, Lamminen A, Luoma K, Leino-Arjas P, Luukkonen R, Riihimäki H. Disc degeneration of the lumbar spine in relation to overweight. *Int J Obes (Lond)* 2005; 29(8): 903-8.
5. Ozer AF, Oktenoglu T, Sasani M, Bozkus H, Canbulat N, Karaarslan E, Sungurlu SF, Sarioglu AC. Preserving the ligamentum flavum in lumbar discectomy: a new technique that prevents scar tissue formation in the first 6 months postsurgery. *Neurosurgery* 2006; 59 (1 Suppl 1):126-33.

TRANSFORAMINAL ENDOSCOPIC DISCECTOMY

Mehdi Sasani MD, Ali Fahir Ozer MD

1. Introduction:

Percutaneous endoscopic discectomy (PED) is a minimally invasive technique for the treatment of lumbar foraminal or extraforaminal and foraminal disc herniations that represent up to 11% of all lumbar herniated discs ⁽¹⁻⁴⁾ Another study defined that farlateral disc herniations, constituting 7% to 12% of all disc herniations, typically migrate cranially as they extended laterally, foraminally, and farlaterally ⁽⁵⁾

In 1934 Mixter and Barr were the first authors who treated lumbar disc herniation surgically ⁽⁶⁾ In 1950 Hult L described the anterior transperitoneal approach ⁽⁷⁾ Hijikata S was the first author who performed the percutaneous discectomy technique in 1975 using fluoroscopy ⁽⁸⁾ During this time, long follow up results were obtained by others. Kambin described the uniportal arthroscopic discectomy in 1983 ⁽⁹⁾ Indications to use endoscopic discectomy technique have since changed. Kambin and Gellman have played major roles in forming the indications used today.

Various minimal invasive intradiscal techniques have been described. Intradiscal techniques like percutaneous nucleotomy and laser decompression without chemonucleolysis revealed poor results in prospective randomized and controlled studies ⁽⁶⁾ Numerous surgical accesses, such as midline approaches involving partial or complete facetectomy, intramuscular extra foraminal and paramedian approaches have been described ⁽¹⁰⁻¹⁴⁾ These approaches are often associated with partial bone removal therefore the risk of spinal instability can develop ⁽¹⁵⁻¹⁹⁾ Percutaneous endoscopic technique is optional approach for disc removal through the foramen and this technique has gradually developed. The benefits of per-

cutaneous endoscopic discectomy are less postoperative pain ⁽²⁰⁻²²⁾, less adhering and scarring ⁽²³⁻²⁵⁾ Direct and clear visualization is obtained by the irrigation of surgery space, increased efficacy of the intervention and avoided instabilization ⁽²⁶⁻²⁸⁾

1.a. Historical prospective and background:

Looking at history the principal changes in concept of PED up to now. Percutaneous endoscopic nucleotomy using scopy was first described by Hijikata in 1975 ⁽⁸⁾ This method is advanced by Parviz Kambin ^(6,9,26) and today is extensively used. In 1985 Onik described automated nucleotomy to remove nucleus pulposus and then laser nucleotomy was developed ⁽²⁹⁾ Percutaneous nucleotomy became popular all around the world. However the outcomes were not satisfactory. In 1993, Revel reported a 44% success rate with percutaneous nucleotomy and a 66% with chemonucleolysis ⁽³⁰⁾ Today percutaneous nucleotomy is not used, so PED indications are totally changed ⁽²⁶⁾

2. Indications:

The morphologie of disc herniation and clinical findings are two factors that have major role to choice of endoscopic surgery for treatment of farlateral disc herniations. Many authors believe that the treatment procedures to noncontained disc herniations and contained disc herniations are different. The arthroscopic and percutaneous endoscopic techniques are suited for patients with contained disc herniations ^(5,31) on the other hand noncontained disk herniations maybe removed using the transforaminal technique or microendoscopic discectomy the criteria's for performing endoscopic transforaminal discectomy were gradually changed with development

of endoscopy technology and advanced in personal practice experience.

Recently, Kambin^(6,9,32) defined the criteria's for performing of endoscopic extraforaminal approach:

- Positive sign of straight leg response
- Radiologic examination findings describe the clinical symptoms and signs
- Radiating pain with or without neurologic deficits
- If radiating leg pain severity is more than lower back pain
- Insufficient conservative (non-surgical) treatment during 8 weeks

The advantages of endoscopic posterolateral approach:

The use of posterolateral route to approach for farlateral disc herniations supply many advantages with comparison of middle approach with senior total facetectomy. Besides, use of endoscopic techniques supply extreme minimally invasive surgery to reach extraforaminal field.

- In endoscopic posterolateral approach, the entrance route is transmuscle, in result epidural and neural ven is prevented, neural edema does not arise from venal congestion.
- Epidural bleeding in result establish of epidural scar tissue is protected.
- Connective tissues and ligaments such as ligamentum flavum, posterior longitudinal ligaments are protected.
- Paravertebral muscle retraction is not performed in posterolateral approaches, on the contrary of middle line approach.
- Protect of facet joint prevent long-term instabilization complications such as spondilolisthesis
- The risk of disc herniation recurrence is less than middle approach, because supportive and connective tissues are preserved in posterolateral approach.
- The superiority of endoscopic posterolateral approach is protection of facet joint.
- In case of recurrence disc herniation, middle approach is fresh, because in the first operation, epidural and epidural anatomic structures are preserved.

3. Contraindications and Disadvantages:

Endoscopic extraforaminal discectomy have more benefits. Therefore these techniques become popular near spine surgeons. Despite useful characters, this technique has many limitations in practice and indications.

Some disadvantages of endoscopic surgery:

- A long time to master this technique and gain experience in endoscopic surgery
 - Technical difficulties are adapting to endoscopic equipments
 - Paravertebral intramuscle extensive scarring
- Contraindications:
- Extensive immigrated disc fragment (far disc fragment imigration)
 - To L5-S1 level (particularly in male patient, the patient with long iliac wings)
 - More than one level
 - Spine canal and foramen stenosis
 - Spondilolisthesis
 - Recurrence disc herniations (reoperation)
 - Nerve root anomalies such as conjugant root.

4. Surgical Procedures:

Endoscopic approach for farlateral disc herniations is usually performed using by one port. A bipolar approaches used for the removal of large central or paramedian subligamentous, the uniportal approach is used for the removal of extraforaminal, foraminal herniations⁽³²⁾

4.a. Surgical Equipments:

Initially, the endoscopic system for discectomy of farlateral disc was designed without irrigation. Then for the best exposure, the endoscopic instrument was modified which irrigation endoscopic system. The instruments and equipments which are used in percutaneous extraforaminal discectomy are showed (Figure 1).

4b. Operating room set up:

A spacious room is used to performing endoscopic procedure. The fluoroscopy is positioned appropriately after patients were given prone position. The layout of the operating room is presented in (Figure 2)

4.c. Patient positioning:

The procedure is usually performed in an operation room, using epidural anesthesia. General anesthesia is also used to do endoscopic farlateral discectomy by many surgeons. We also believe that perform of general anesthesia supply comfort ambience for both patient and surgeon. The patient is positioned prone position same classic position for performing discectomy, but the femur and knee angels are little more than classic prone positions (Figure 3)

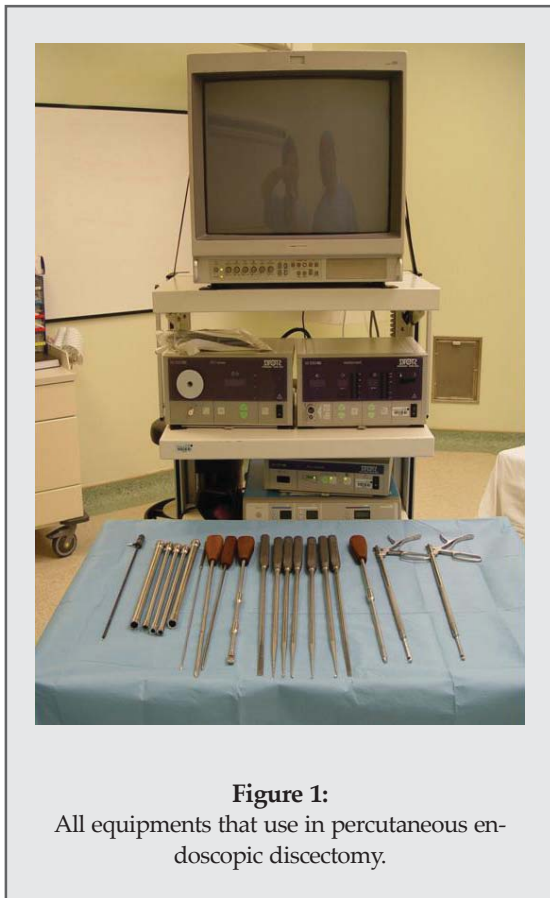


Figure 1:
All equipments that use in percutaneous endoscopic discectomy.

4.d. Surgical Technique:

The entry point 8-10 cm laterally to the midpoint is done on the effected side using fluoroscopy. The guide wire is inserted through the triangular working zone into the intervertebral disc with approximately a 45 ° angle (Figure 4) As depicted in (Figure 5) the triangular working zone is basically defined by Kambin and Gellman⁽⁹⁾ The zone is formed medially by the superior facet joint, inferiorly by the transverse process and superiorly and inferiorly by the nerve root exiting the neural foramen. The guide wire location should be on the interpedicler line and controlled with fluoroscopy in AP position. The working channel is placed in order from thin to wide dilators. The end working channel was fixed on working triangle very carefully. In this way, the root nerve was quitted superior-anterior side out of working channel, in result wall of trocar was retracted root nerve. We used a 0 ° angle optic with 15 cm length and 3 mm diameter. The irrigation system was set up and Saline irrigation was used to aid visualization. The special tools which were designed for this technique such as dis-

sector, grasping forceps were adapted to PED procedure. Normally, working channel is positioned superior-anteriorly for visualization of root nerve. But in some patient's nerve roots have only been in half of working area, the root nerve was mobilized by a nerve hook and then the working channel was repositioned. After clear exposure of the extruded disc material, it was removed (Figure 6) and at the end of the operation the foraminal area was looked over.

5. Post operative care:

The patient is followed-up in recovery postoperatively after neurological examination transfer to ward. Perfusion of analgesia via patient control analgesics (PCA) equipment can be applying a comfort ambience for patient postoperatively. Patients are usually discharged one day after surgical treatment.

6. Complications and Avoidance:

Complications of endoscopic extraforaminal discectomy usually occur during operation or early postoperatively. The complications in our series (66 patients) were postoperatively dysesthesias with partial root damage in 6% of patients, 3% were operated after PED at the same sessions, 4.5% late recurrence disc herniation⁽³³⁾

Complication of endoscopic extraforaminal discectomy usually occurs during operation or early postoperatively. Preoperatively more malposition of working port or other endoscopic instruments cause nerve root damage. In result depend to nerve root injury, dysesthesias, paresia, paresthesia and neuralgia can be occurred. Insufficient or unsuccessful discectomy is other reason of early postoperative pain.

As other surgical procedure, infections such as discitis, wound infection, extensive hematoma are complications after endoscopic surgery. In late term recurrence of disc herniation is common complication. Instability and spondilolisthesis is occurred less than classic open surgery.

7. Discussion and Summary:

The PED technique is a minimal invasive surgical procedure in foraminal or extraforaminal disc herniations. In open surgery, due to partial facetectomy it always has a risk for potential instability^(16,18,19) PED provides enough observations of all foraminal anat-

omy with a 45° angle, so that it is not necessary to remove facets for visualization and partial facetectomy is not even performed (27,34-36)

Kambin (6) reported the indications which are accepted today. These indications are: 1) with or without neurologic deficit, 2) Intractable pain after conservative treatment for 8 weeks, 3) The pain shows radicular character. That means, the basic criteria's of classic lumbar disc surgery are also available with PED.

PED is an alternative method to open surgery. As discussed above in midline approach to foraminal or extraforaminal disc herniation, medial or lateral facetectomy is necessary (12,37) Removal of disc and facet joint results in a risk to develop segmental instability (16,19) An alternative open surgery technique is to approach laterally through muscles and laterally to facet joint (38) This is an invasive technique because passing through muscles might causes bleeding during the operation so that there is no clear visualization during the operation. Extensive scarring can be seen to both muscles and foraminal area in the long term. In addition the distance is too long from the skin to the extraforaminal space. The PED technique offers an easy way to reach extraforaminal space and Saline irrigation provides good vision and no need to remove facet joint. Although PED is a minimal invasive method and offers many benefits to the patient, it takes a long time to master this procedure and to gain experience in endoscopic surgery requires working with experienced surgeons for sometime. Technical difficulties are adapting to an endoscope monitor, endoscope tools and endoscopic anatomy of the surgical area. All these factors restrict PED practice in lumbar surgery.

The hospitalization period is only 1 day and 63% of our cases returned to work in 3-4 days similar to literature data (28) The injury to paraspinal muscles due

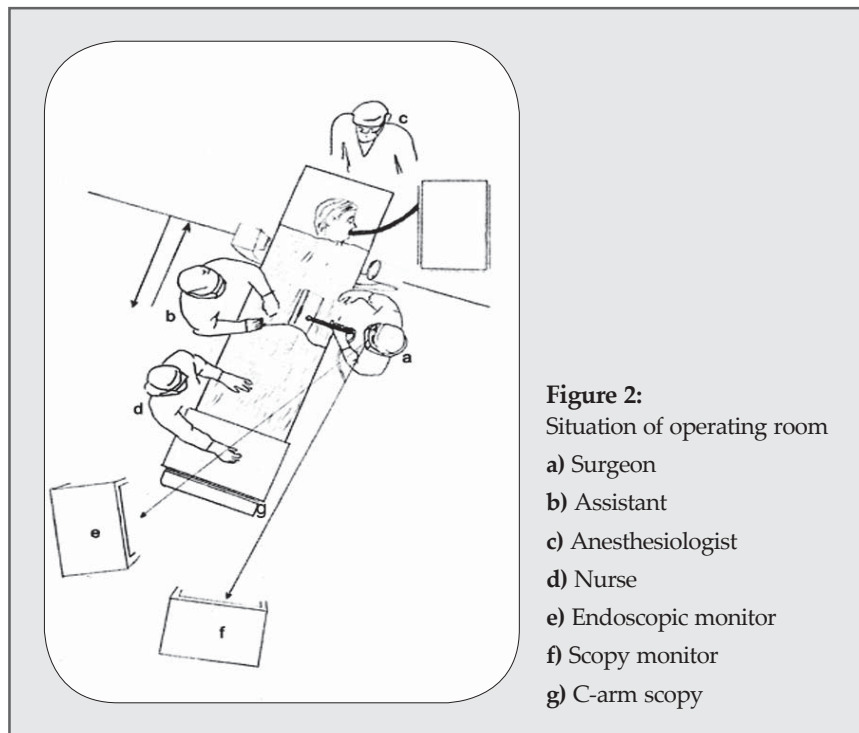


Figure 2:
Situation of operating room
a) Surgeon
b) Assistant
c) Anesthesiologist
d) Nurse
e) Endoscopic monitor
f) Scopy monitor
g) C-arm scopy

to traction and denervation are common in open surgery (23-25) There is no retraction in PED and it is not necessary to remove excessive bone and facet joint, does not cause probable instability. There is always a chance of a midline approach for reoperation.

Postoperative evaluation is critical to understand the success of the procedure. Onik and Allen (29) de-

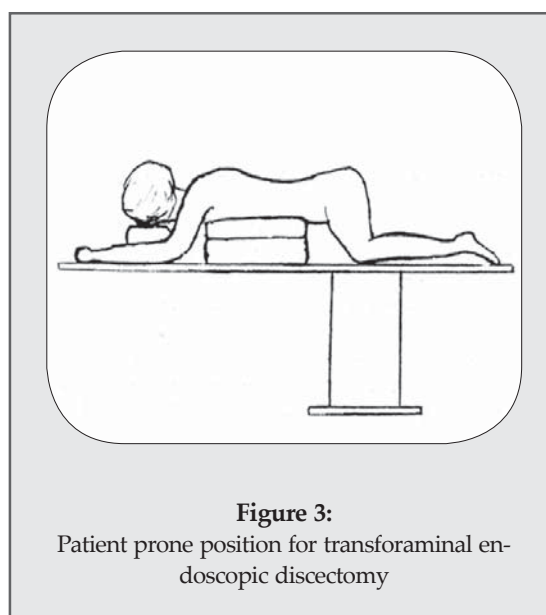
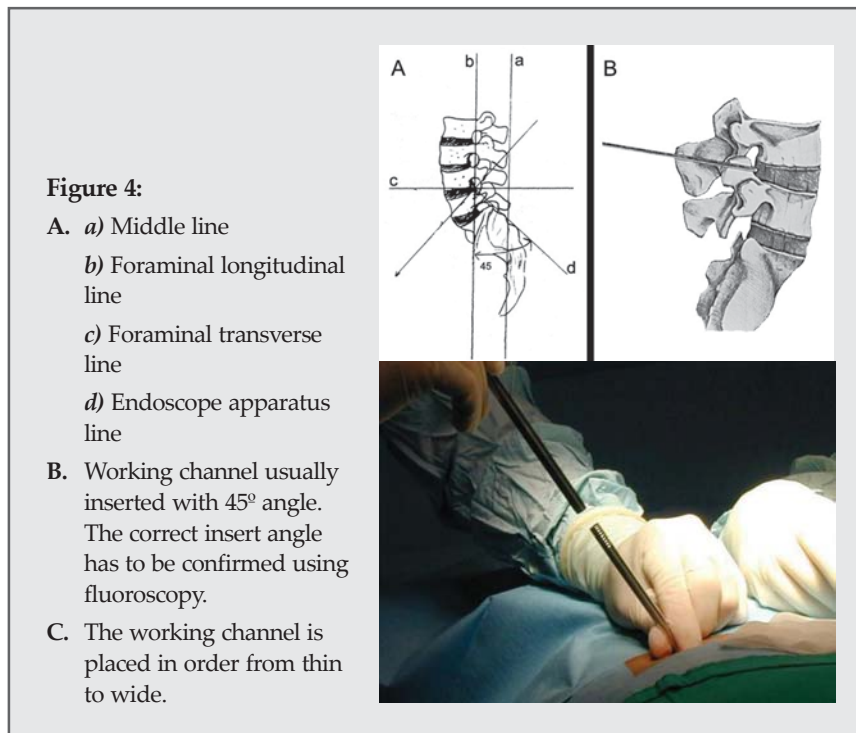


Figure 3:
Patient prone position for transforaminal endoscopic discectomy



can do the open surgery during the same session under general anesthesia.

As discussed above, a minimal invasive method offers many advantages to the patient. Less anatomic injury offers the patient to return to normal daily life in a short period. Thus, the least amount of time out of work offers economic and social advantage to the patient. The major disadvantages of this method is the difficulty to reach extraforaminal disc herniations at L5-S1 level due to iliac bone wings and the disc herniations lo-

cate the satisfactory outcome criteria; total or partial reduction in radicular pain, the return of postop functions, no need for narcotic analgesics, also the surgeon and patient both being relaxed. These criteria are also valid in open surgery. Our experience showed following PED procedure the significant reduction in pain is an important criteria. Particularly, in extruded extraforaminal disc herniations there is a dramatic improvement following PED. In these cases, the general outcome can only be obtained with removal of fragmented disc material. The removal of fragmented disc material offers pain free status; we know some points of view in literature show that removal of the free fragment is enough in lumbar disc surgery. We share this opinion because our practice is the same ⁽³³⁾

The data shows that PED procedure can be applied both under general or local anesthesia ^(6,39-41), we did all procedures under general anesthesia. Literal reviews show that general anesthesia is important in regard to the patient's psychology ⁽⁴²⁻⁴⁴⁾ Patients still might experience pain during the procedure under local anesthesia. Moreover, the operating room condition may also have a negative effect on the patient's psychology ⁽⁴⁵⁾ Finally, if the PED procedure fails to remove fragmented material, we

can do the open surgery during the same session under general anesthesia. Additionally, in the presence of pathologies such as spinal stenosis, degenerative spondylosis, facet hypertrophy, short pedicle and spondylolisthesis the decompression can not be achieved.

In summary, PED technique in appropriate cases can be an optional surgical procedure which can achieve a favorable outcome with pain free status, and need a competent team with adequate endoscopic technology.

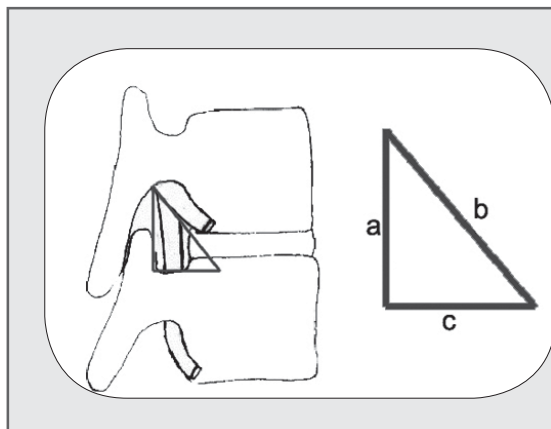
8. Case illustrations

Illustrations of some patients who underwent percutaneous arthroscopic discectomy procedure. Sagittal and axial view of these patients was showed (Figure 7)

9. References:

1. Abdullah AF, Ditto EW III, Byrd EB, et al. Extreme lateral lumbar disc herniations. Clinical syndrome and special problems of diagnosis. *J. Neurosurg* 1974; 41: 229-234.
2. Abdullah AF, Wolber PG, Warfield JR, et al. Surgical management of extreme lateral lumbar disc herniations. Review of 138 cases. *Neurosurgery* 1988; 22:648-653.

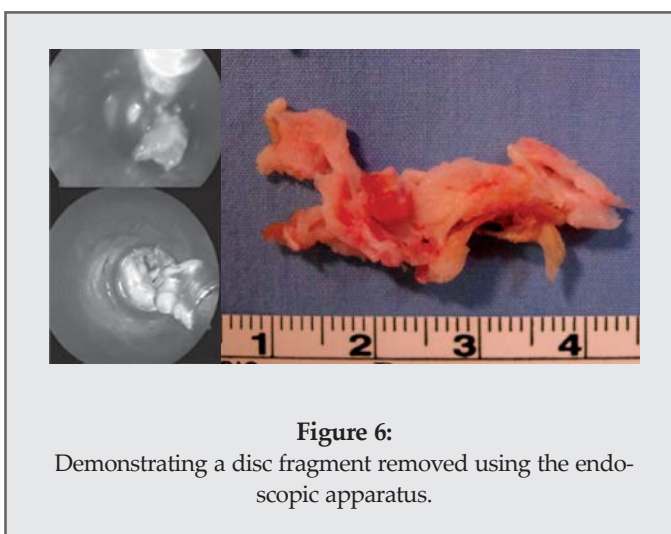
3. O'Hara LJ, Marshall QW. Far-lateral disc herniation. The key to the intertransverse approach. *J. Bone Joint Surg (Br)* 1997; 79:943-947.
4. Quigley MR, Bost J, Maaron JC, et al. Outcome after microdiscectomy. Results of a prospective single institutional study. *Surg Neurol* 1998; 49(3):263-7.
5. Epstein NE, Epstein JA, Carras R, et al. Far lateral lumbar disc herniations and associated structural abnormalities. An evaluation in 60 patients of the comparative value of CT, MRI, and myelo-CT in diagnosis and management. *Spine* 1990;15(6): 534-9.
6. Kambin P, Gennarelli T, Hermantin F. Minimally invasive techniques in spinal surgery. *Current practice. Neurosurg Focus* 1998; 4(2):1-10.
7. Hult L. Retroperitoneal disc fenestration in low back pain and sciatica. *Acta Orthop Scand* 1956; 20: 342-348.
8. Hijikata S. Percutaneous discectomy. A new treatment method for lumbar disc herniation. *J Toden Hosp* 1975; 5: 5-13.
9. Kambin P, Gellman H. Percutaneous lateral discectomy of the lumbar spine. A preliminary Report. *Clin Orthop* 1983; 174:127-132.
10. Darden BVII, Wade JF, Alexander R, et al. Farlateral disc herniations treated by microscopic fragment excision. *Techniques and results. Spine* 1995; 20:1500-1505.
11. Epstein NE. Different surgical approaches to far lateral lumbar disc herniation: Review. *J Spinal Disorders* 1995; 8: 383-394.
12. Garrido E, Connaughon PN. Unilateral facetectomy approach for lateral lumbar disc herniation. *J. Neurosurg* 1991; 74:754-6.
13. Jackson RP, Glah JJ. Foraminal and extraforaminal lumbar disc herniation. Diagnosis and treatment. *Spine* 1987; 12 (6): 577-85.
14. Maroon JC, Kopitnik TA, Schulof LA, et al. Diagnosis and microsurgical approach to farlateral disc herniation in the lumbar spine. *J. Neurosurg* 1990; 72:378-382.

**Figure 5:**

Triangular working zone.

- a. Medial is superior edge facet joint, triangular zone
- b. Superior, anterior edge is the nerve root exiting the adjacent neural foramen
- c. Inferior edge is transverse process.

15. Halldin K, Zoega B, Karrholm J, et al. Is increased segmental motion early after lumbar discectomy related to poor clinical outcome 5 years later? *Int Orthop* 2005; 29(4): 240-4.
16. Kotilainen E. Long term outcome of patients suffering from clinical instability after microsurgical treatment of lumbar disc herniation. *Acta Neurochir (Wien)* 1998; 140(2): 120-5.
17. Kramer J, Ludwig J. Surgical treatment of lumbar intervertebral disc displacement. Indications and methods. *Orthopade* 1999; 28(7): 579-84.
18. Kuroki H, Goel VK, Hdekamp SA, et al. Contributions of flexion-extension cyclic loads to the lumbar spinal segment stability following different discectomy procedures. *Spine* 2004; 29(3): E39-46.
19. Schaller B. Failed back surgery syndrome. The role of symptomatic segmental single level instability after lumbar microdiscectomy. *Eur Spine J* 2004; 13(3): 193-8.
20. Shaikh, Chung F, Imarengiaye C, et al. Pain, nausea vomiting and ocular complications delay discharge

**Figure 6:**

Demonstrating a disc fragment removed using the endoscopic apparatus.

- following ambulatory microdiscectomy. *Can J Anaesth* 2003; 50(5): 514-8.
21. Gamberdella G, Gervasio O, Zaccone C, et al. Prevention of recurrent radicular pain after lumbar disc surgery. A prospective study. *Acta Neurochir* 2005; 92: 151-4.
 22. Swartz KR, Trost GR. Recurrent lumbar disc herniation. *Neurosurg Focus* 2003; 15(3): E10.
 23. Ganzer D, Giese K, Volker L, et al. Two year results after lumbar microdiscectomy with and without prophylaxis of a peridural fibrosis using Adcon-L. *Arch Orthop Trauma Surg.* 2003; 123(1): 17-21.
 24. Gerszten PG, Moossy JJ, Flickinger JC, et al. Inhibition of peridural fibrosis after laminectomy using low-dose external beam radiation in a dog model. *Neurosurgery* 2000; 46(6): 1478-85.
 25. Vogelsang JP, Finkenstaedt M, Vogelsang M, et al. Recurrent pain after lumbar discectomy. The diagnostic value of peridural scar on MRI. *Eur Spine J* 1999; 8(6): 475-9.
 26. Kambin P, Casey K, O'Brien E. Transforaminal arthroscopic decompression of lateral recess stenosis. *J. Neurosurg* 1996; 64: 462-467.
 27. Lew SM, Mehalic TF, Fagone KL. Transforaminal Percutaneous endoscopic discectomy in the treatment of far-lateral and foraminal lumbar disc herniations. *J. Neurosurg (Spine)* 2001; 94:216-220.
 28. Mayer HM, Brock M. Percutaneous endoscopic discectomy. Surgical technique and preliminary results compared to microsurgical discectomy. *J. Neurosurg* 1993; 78: 216-225.
 29. Onik G, Helms C, Ginsburg L. Percutaneous lumbar discectomy using a new aspiration probe. *AJR Am Roentgenol* 1985; 144: 1137-1140.
 30. Revel M, Payan D, Vallee C. Automated percutaneous lumbar discectomy versus chemonucleolysis in the treatment of sciatica. A randomized multicenter trial. *Spine* 1999;18: 1-7.
 31. Mayer HM, Brock M, Stern E, et al. Percutaneous endoscopic laser discectomy. Experimental results. In Mayer HM, Brock M (eds). *Percutaneous lumbar discectomy*. 1st ed. Heidelberg, Germany, Springer Verlag, 1989;pp187-99.
 32. Kambin P, Zhou L. History and current status of percutaneous arthroscopic disc surgery. *Spine*. 1996 Dec 15;21(24 Suppl).57S-61S
 33. Sasani M, Ozer AF, Oktenoglu T, et al. Percutaneous endoscopic discectomy for far lateral lumbar disc herniations. prospective study and outcome of

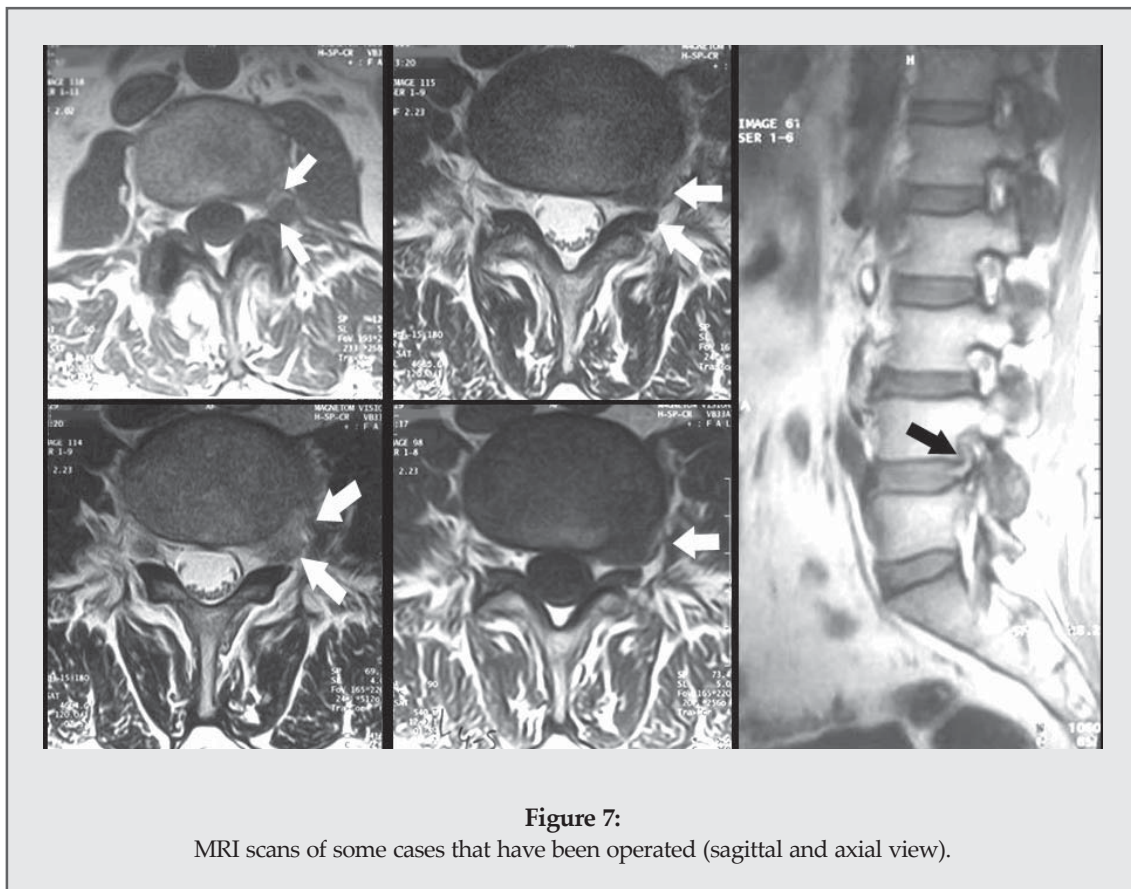


Figure 7:
MRI scans of some cases that have been operated (sagittal and axial view).

- 66 patients. *Minim Invasive Neurosurg.* 2007; 50(2): 91-7.
34. Ditsworth DA. Endoscopic transforaminal lumbar discectomy and reconfiguration. a posterolateral approach in to the spinal canal. *Surg Neurol* 1998; 49(6): 588-97.
 35. Haag M. Transforaminal endoscopic lumbar discectomy. Indications and short term to intermediate term results. *Orthopade* 1999; 28(7): 615-21.
 36. Mathews HH. Transforaminal endoscopic microdiscectomy. *Neurosurg Clin N Am* 1996; 7(1): 59-63.
 37. Ray CD. Transfacet decompression with dowel fixation. A new technique for lumbar lateral spinal stenosis. *Acta Neurochir Suppl* 1988; 43: 48-54.
 38. Reulen HJ, Muller A, Ebeling U. Microsurgical anatomy of the lateral approach to extraforaminal lumbar disc herniations. *Neurosurgery* 1996; 39(2): 345-50.
 39. Casey KF, Chang MK, O'Brien ED, et al. Arthroscopic microdiscectomy. comparison of preoperative and postoperative imaging studies. *Arthroscopy* 1997;13: 438-445.
 40. Kunogi J, Hasve M. Diagnosis and operative treatment of intaforaminal nerve root compression. *Spine* 1991; 16(11): 1312-20.
 41. Mixer WJ, Barr JS. Rupture of intervertebral disc with involvement of the spinal canal. *N Eng J Med* 1934; 211: 210-215.
 42. Miyawaki T, Kohjitani A, Maeda S, et al. Intravenous sedation for dental patients with intellectual disability. *J Intellect Disabil Res* 2004; 48(pt8): 764-8.
 43. Smith AF, Pittaway AJ. Premedication for anxiety in adult day surgery; Review. *Cochrane Database Syst Rev* 2003; 1: CD002192.
 44. Wu CL, Hso W, Richman JM, et al. Postoperative cognitive function as an outcome of regional anesthesia and analgesia. *Reg Anesth Pain Med* 2004; 29(3): 257-68.
 45. Voon LW, Au Eong KG, Saw SM, et al. Effect of preoperative counseling on patient fear from the visual experience during phacoemulsification under topical anesthesia. Multicenter randomized clinical trial. *J Cataract Refract Surg* 2005; 31(10): 1966-9.

5c POSTEROLATERAL SELECTIVE ENDOSCOPIC DISCECTOMY THE YESS TECHNIQUE

Anthony T. Yeung MD, PC, Christopher A. Yeung MD

1. Introduction

The intervertebral disc, an important supporting structure of the spinal column, is implicated as a major source of low back pain and sciatica.^(1,2) The pathogenesis of disc degeneration and herniation is complex and multifactorial, but clearly outlined and documented by Wolfgang Rauschnig's work illustrating the patho-anatomy of degenerative disc disease and degenerative conditions of the lumbar spine.⁽³⁾ Most disc herniations are not the result of an acute event, but an accumulation of several insults to the spine that lead to degeneration, annular tears, and eventual disc herniation.⁽⁴⁾ There are several theories of disc degeneration including mechanical, chemical, age-related, autoimmune and genetic. Within the mechanical theory, the following types of abnormal loads have been proven experimentally to cause disc injury: torsion⁽⁵⁾, compression^(5,6), repetitive compressive loading in flexion⁽⁷⁾, hyper flexion⁽⁸⁾, and vibration.⁽⁹⁾

Traditionally disc surgery has been reserved for disc herniations causing radiculopathy or nerve deficits due to mechanical compression on the spinal nerves.⁽¹⁰⁾ This is due to the inherent morbidity of the posterior surgical approach that must violate and alter the important function of the posterior spinal column. Open posterior discectomy often includes or requires a midline incision, muscle and ligament stripping, prolonged muscle retraction, bone resection of the lamina and facet, and nerve root and dural tube retraction. This can cause instability and scarring around the sensitive nerve roots even in a technically perfect operation. The morbidity of the standard posterior approach has therefore limited the use of surgery as an early treatment option in the cascade of disc degeneration and herniation. Thus,

surgery was often not recommended for herniations without neurologic deficits, "small" herniations, central herniations, and annular tears. The dogma that "disc surgery is really decompressive nerve surgery" dominates the rationale for traditional micro-discectomy for herniated discs.

Minimally invasive surgical options that limit the inherent approach related-morbidity are possible with the posterolateral portal.⁽¹¹⁻²⁸⁾ This approach to the disc is most challenging at the L5-S1 level due to the prominence of the iliac crest. Most L5-S1 disc spaces are accessible; however, entry into the disc may require foraminal decompression of the lateral facet.

The least invasive of all posterolateral intradiscal techniques is the injection of Chymopapain, a treatment option validated by at least two large prospective, randomized double blind studies and numerous cohort studies.^(29,30) This treatment produced satisfactory results in many studies and came into widespread clinical use in the 1970's, but lost popularity with reports of complications as severe as anaphylactic shock and transverse myelitis.⁽³¹⁾ Although these complications can now be virtually eliminated with pre-operative antigen screening and discography, the perceived risk has limited its continued use. More recent studies from experienced chymopapain users still tout chymopapain as a valuable adjunct to endoscopic disc surgery.^(32,33,34)

The introduction of the operating microscope for discectomy by Yasargil in 1967 and later by Williams encouraged smaller incisions for the standard posterior approach.^(35,36) The transcanal microscope-assisted technique became the gold standard; however, it still requires retraction of the dural tube and nerve, periosteal stripping of the muscle and ligaments, hemi-

laminotomy, and regional or general anesthesia. Tubular retractors have recently been developed that can be used with either a microscope or endoscope for this posterior transcanal approach.⁽³⁷⁾ This utilizes tissue dilation rather than cutting, and minimizes the superficial tissue destruction, but still requires the same amount of bone removal and neural manipulation as the standard microscopic posterior discectomy.

The concept of indirect decompression of the spinal canal via a posterolateral, extracanal approach was introduced by Kambin in 1973 using a Craig cannula for limited nucleotomy in combination with a transcanal approach.⁽¹⁴⁾ In 1975 Hijikata reported the first stand alone nonvisualized posterolateral percutaneous central nucleotomy.⁽⁹⁾

Kambin went on to describe the safe triangular working zone (Kambin's Triangle) (Figure 1) and results of arthroscopic microdiscectomy, in which arthroscopic visualization of the herniation via the posterolateral approach was used for discectomy of contained herniations.^(11,14-19) Hermantin et al. reported satisfactory results from video assisted arthroscopic microdiscectomy in 97% of patients compared to 93% in traditional microdiscectomy with an average of 31 months follow-up.⁽¹¹⁾ The arthroscopic group had less narcotic use and less time off from work. The study was prospective and randomized with 30 subjects in each group.

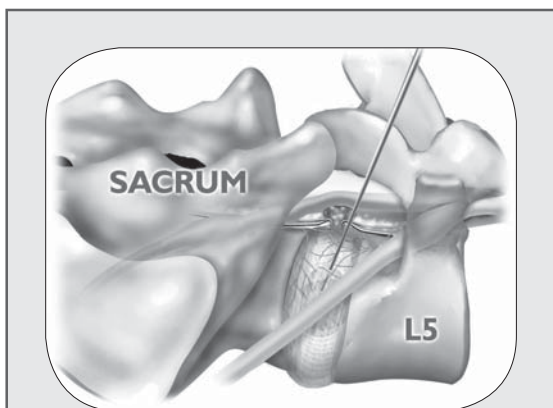


Figure 1:

Kambin's triangular working zone is the site of surgical access for posterolateral endoscopic discectomy. It is defined as a right triangle over the dorsolateral disc. The hypotenuse is the exiting nerve root, the base (width) is the superior border of the caudal vertebra, and the height is the dura/traversing nerve root.

Mayer also showed promising results in a prospective randomized study comparing percutaneous discectomy with microscopic discectomy for contained or slight subligamentous herniations.⁽²¹⁾ The percutaneous group showed comparable or superior results. Long term disability defined by return to work status, produced statistically significant differences. In the percutaneous group, 95% returned to their previous occupation compared to 72.2% in the microdiscectomy group. Each group had 20 subjects.

Evolving methodology the 1980's and early 1990's allowed for endoscopic lumbar nerve root decompression by a visualized, direct excision of contained and non-contained herniated disc fragments.^(19,20,25,28)

Yeung introduced a rigid rod-lens, flow integrated, multichannel, wide-angle operating spinal endoscope in 1998 that allowed for even more flexibility accessing the disc, traversing and exiting nerve roots, and epidural space. The endoscope configuration offered significant visual improvement and the complementary instrument system with specialized slotted and bevel-ended tubular access cannulas allowed for same-field viewing of the intradiscal space, annular wall, and epidural space. The design allows for improved access to the posterior disc for visualized fragmentectomy, improved access to the undersurface of the superior articular facet for foraminoplasty, and protection of the neural structures by rotating the cannula.^(26,27)

2. Indications and Treatment Rational

- All lumbar disc herniations except migrated/sequestered fragments inaccessible through the foramen
- Annular tears
- IDD-Internal disc disruption diagnosed with discography producing concordant pain and radiographic abnormalities
- Foraminal stenosis
- Synovial cysts of the facet joint
- Discitis

Perhaps the ideal lesion for posterolateral selective endoscopic discectomy is the far lateral, extraforaminal disc herniation. The exiting nerve is routinely visualized, and the cannula inserts directly at the herniation site. This approach requires less ma-

nipulation of the exiting nerve root than the paramedian posterior approach.

Any herniation contiguous with the disc space not sequestered and migrated is amenable to endoscopic disc excision. The timing of surgical treatment is similar to posterior transcanal discectomy. The size and types of herniations chosen by the surgeon for endoscopic excision will depend on the skill and experience of the surgeon as well as the anatomic considerations in the patient relative to the location of the herniation. Certainly, all contained disc herniations are appropriate for endoscopic decompression. With experience extruded herniations can be routinely addressed.

The posterolateral endoscopic approach only requires tissue dilation to accommodate a 7mm working cannula. This tissue sparing approach offers consideration for earlier surgical timing when approach related risk/benefit ratios are factored in after patients fail conservative treatment and continue to have debilitating pain without neurologic deficit. Quality of life issues and functional issues associated with chronic discogenic pain can be addressed with this minimally invasive surgical option. Therefore, small disc herniations with predominant leg pain, central disc herniations with predominant back pain, IDD, and annular tears causing chemical sciatica are amenable to disc surgery by endoscopic means.

The discectomy decompresses the disc, alleviating pressure on the annulus, and removes any unstable degenerated disc fragments that could herniate. Radiofrequency energy can be applied to the annular tears under direct visualization to contract the collagen and ablate ingrown granulation tissue, neoangiogenesis, and sensitized nociceptors. Frequently interpositional nuclear tissue is seen within the fibers of the annular tear preventing the tear from healing. This tissue can then be removed to allow the tear to heal.

Endoscopic foraminoplasty can be readily achieved with bone trephines/rasps and the side firing Holmium-YAG laser.⁽³⁸⁾ The roof of the foramen is formed by the undersurface of the superior articular facet. This is easily visualized and accessed via the endoscope. The side firing Holmium-YAG laser and bone trephines strip the facet capsule and remove bone to enlarge the foraminal opening. Studies by Panjabi have demonstrated that decompression through the foramen can be more effective than posterior decompression for foraminal stenosis. The posterior removal of

1/3 of the medial facet produces more instability than posterolateral foraminal decompression.⁽³⁹⁾ Synovial cysts can also be visualized and removed.

Discitis can be treated with posterolateral endoscopic discectomy and debridement. Current methods rely on needle aspiration followed by prolonged antibiotic treatment. Needle aspirations are not as reliable as tissue samples from endoscopic debridement, and are often negative even in the face of bacterial discitis. Surgeons are often hesitant to perform open debridement because of the morbidity of the open approach, creation of dead space and devascularized tissue, and the concern for spreading the infection in the spinal canal. Endoscopic excisional biopsy and thorough debridement via the posterolateral portal has provided almost immediate pain relief and a much more reliable tissue sample for laboratory analysis and culture.⁽⁴⁰⁾ Since only tissue dilation is used, no dead space is created that would allow the infection to spread. Many patients with discitis have co-morbidities, which make them poor open surgical candidates.

3. Surgical Procedures

3.a. Surgical Equipment

The Yeung Endoscopic Spine Surgery System (Richard Wolf) consists of the following instruments. (Figure 2)

- Multichannel, 20° oval spinal endoscope with 2.7mm working channel and integrated continuous irrigation (inflow and outflow) ports
- Multichannel, 70° oval spinal endoscope
- 7mm working cannulas with various open slotted, beveled, and tapered ends
- 2 channel tissue dilator/obturator
- Specialized single and double action rongeurs for visualized fragmentectomy
- Larger straight and hinged rongeurs for discectomy and targeted fragmentectomy
- Trephines for annulotomy and foraminoplasty
- Micro rasps, curettes, and penfield probes
- Annulotomy knife
- Flexible bipolar radiofrequency probe for hemostasis, thermal contraction of the annular collagen, and thermal ablation of the annular nociceptors (Ellman trigger-flex bipolar probe)

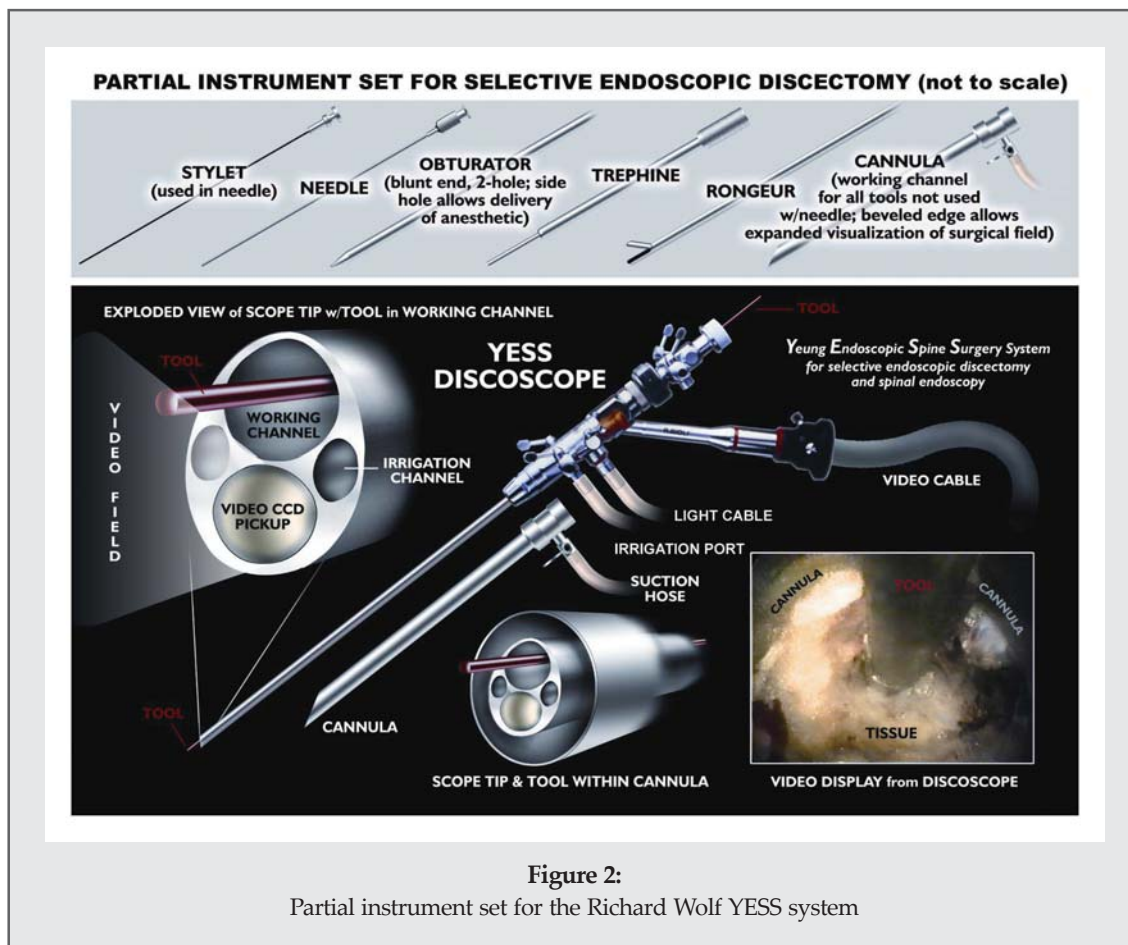


Figure 2:
Partial instrument set for the Richard Wolf YESS system

Adjunctive equipment

- Straight and flexible suction-irrigation shavers for discectomy (Endius MDS)
- Side firing Holmium-YAG laser (Trimedyne)
- Fluid pump for continuous irrigation
- Video endoscopy tower

3.b. OR Set up

Proper OR setup requires a radiolucent table with a hyperkyphotic frame, one C-arm, and a tower with the usual monitor for endoscopic viewing. Ideally the operating suite will be equipped to record the procedure including fluoroscopic images onto video and/or still images. Foot pedals controlling the radiofrequency probe, shaver, suction, C-arm, and laser should be ergonomically arranged. Required personnel include the anesthesiologist, scrub tech, circulator, C-arm technician and a surgical assistant if a biportal approach is planned. (Figure 3)

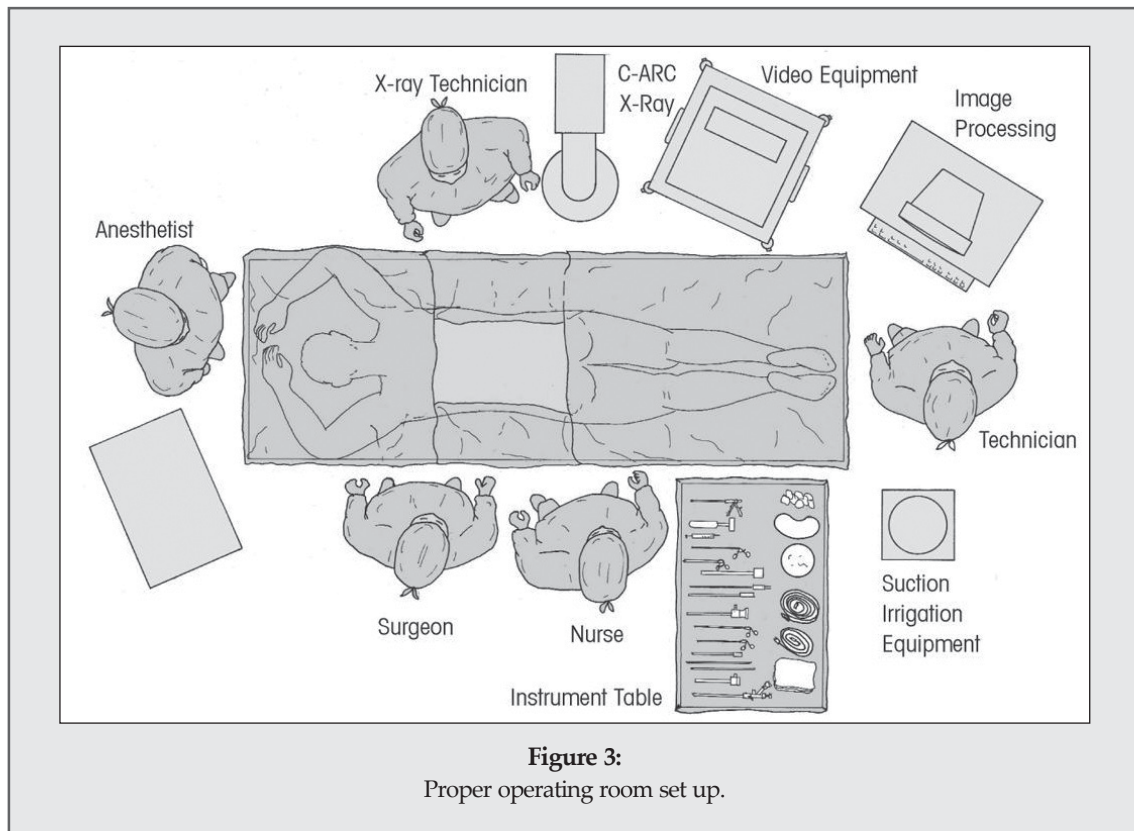
3.c. Patient Positioning

The patient is placed prone on the radiolucent hyperkyphotic frame (Kambin frame, US Surgical) with the arms away from the side of the body. Care is taken to line up the patient with the C-arm to ensure a perfect posterior-anterior and lateral view on the fluoroscopy. The spinous processes should be centered between the pedicles on the PA view and the endplates parallel on the lateral view. The surgical level must be centered to avoid parallax error. Anesthesia consists of ½ percent local lidocaine infiltration, supplemented by versed and fentanyl for conscious sedation.

3.d. Step-by-Step Surgical Techniques with Relevant Surgical Anatomy

3.d.1. Protocol for Optimal Needle Placement

Utilizing a thin metal rod as a radio-opaque marker and ruler, lines are drawn on the skin to mark surface topography for guidance in free hand biplane



C-arm needle placement. These surface markings help identify three key landmarks for needle placement: the anatomic disc center, the annular foraminal window (centered within the medial and lateral borders of the pedicles), and the skin window (needle entry point). (Figure 4)

- Utilizing a metal rod as radio-opaque marker and ruler, draw a longitudinal line over the spinous processes to mark the midline on the PA view.
- Draw a transverse line bisecting the targeted disc space to mark the transverse disc plane on the PA view. The intersection of these 2 lines marks the anatomic disc center.
- On the lateral view draw the disc inclination plane from the lateral disc center to the posterior skin. This line should bisect the disc and be parallel to the endplates. This line determines the cephalad/caudal position of the needle entry point. When drawing this disc inclination line, the tip of the metal rod should be at the lateral anatomic disc center. The distance from the rod tip to the plane of the posterior skin is measured by grasping the rod at the point where the posterior skin plane intersects it.
- This distance is then measured on the posterior skin from the midline along the transverse plane line.
- At the lateral extent of this measurement a line parallel to the midline is drawn to intersect the disc inclination plane line. This intersection marks the skin entry point or skin window for the needle.

The skin window's lateral location from the midline determines the trajectory angle into the foraminal annular window. Utilizing the above method, a 45 degree trajectory to the disc should place the needle tip in the true anatomic disc center. Since most of the pathology being treated is located posteriorly, placement in the posterior one third of the disc is optimal. Thus one needs to "fudge" 1-2 cm laterally for the optimal skin window placement to access the posterior one third of the disc. This allows one to avoid the facet joint with a shallower needle trajectory (about 30 degrees in the coronal plane) to the disc. Alternatively one can place the rod tip at the anterior portion of the disc when measuring the disc inclination plane. This produces a longer measurement to the posterior skin plane, thus placing the

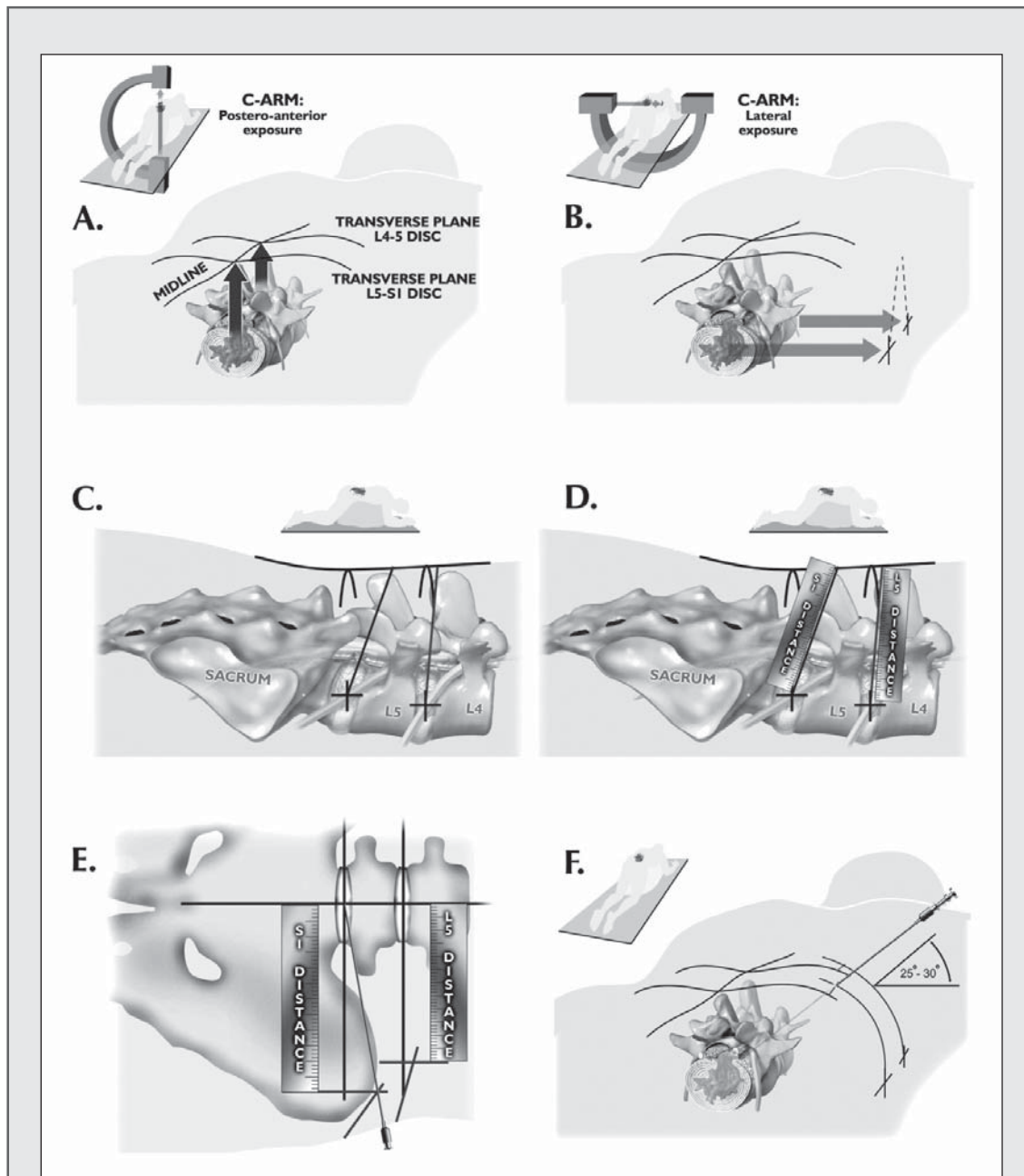


Figure 4:

Protocol for optimal needle placement. A. PA fluoroscopic view enables topographic location of the midline and the transverse disc plane. The intersection of these lines is the PA anatomic disc center. B. Lateral fluoroscopic view enables topographic location of the disc inclination plane. C. The inclination plane of each target disc is drawn on the skin from the lateral disc center. D. The distance from the lateral disc center to the posterior skin plane is measured along the inclination plane. E, F. This same distance is measured from the midline along the transverse disc plane for each target disc. At the end of this measure a line parallel to the midline is drawn to intersect the disc inclination line. This is the skin entry point or "skin window" for the needle.

skin window more lateral. This is actually the preferred method. This coordinate system of finding the optimal anatomical landmarks for instrument placement will help decrease the steep learning curve for needle placement and eliminate the less accurate “down the tunnel” method favored by radiologists and pain management physicians.

The positive disc inclination plane of the L5-S1 disc is noteworthy. A steep positive inclination line (lordosis) will position the optimal skin window more cephalad from the transverse plane line, avoiding the “high iliac crest”. A flatly inclined L5-S1 disc will position the optimal skin window with the iliac crest obstructing the trajectory of the needle. The skin window will have to start more medial to avoid the iliac crest, and sometimes the lateral ¼ of the facet joint must be resected to allow for posterior needle placement in the disc.

The first neutrally aligned disc inclination plane is usually at L4-L5 or L3-L4. A neutrally aligned disc inclination plane is in the same plane as the transverse plane line, thus the skin window is in line with the transverse plane line. A negatively inclined disc, often at L1-L2 and L2-L3, places the skin window caudal to the transverse plane line.

3.d.2. Needle Placement

Infiltrate the skin window and subcutaneous tissue with one half percent lidocaine. Insert a six inch long, 18 gauge needle from the skin window at a 25-30 degree angle from the coronal plane (reciprocal of 60-65 degrees from the parasagittal plane), anteromedially toward the anatomic disc center. Infiltrate the needle tract with one half percent lidocaine as you are advancing the needle. The superficial portion of the needle trajectory is usually outside of the c-arm viewing perimeter. Once the needle tip is visible within c-arm viewing perimeter, tilt the c-arm, beam parallel to the disc inclination plane, the Ferguson view. Advance the needle toward the target foraminal annular window. If minor directional adjustments are necessary, use the plane of the needle bevel and hub pressure to navigate. At the first bony resistance or before the needle tip is advanced medial to the pedicle, turn the c-arm to the lateral projection. Do not advance the needle tip medial to the pedicle during the initial approach. Doing so risks inadvertent traversing nerve root and dural puncture.

Most frequently the first bony resistance encountered is the lateral facet. Increase the trajectory angle

to aim ventral to the facet and continue the approach toward the foraminal annular window. Turning the needle bevel to face dorsal helps the needle tip skive off the undersurface of the facet. The c-arm lateral projection should confirm the needle tip’s correct annular location. In the lateral view the correct needle tip position should be just touching the posterior annulus surface. In the postero-anterior view the needle tip should be centered in the foraminal annular window. The above two views of the c-arm confirm that the needle tip has engaged, the safe zone, the center of the foraminal annular window.

While monitoring the postero-anterior view, advance the needle tip through the annulus to the midline (anatomic disc center). Then check the lateral view. If the needle tip is in the center of the disc on the lateral view you have a central needle placement, which is good for a central nucleotomy. Ideally the needle tip will be in the posterior one third of the disc indicating posterior needle placement. This is ideal for accessing the herniations.

3.d.3. Evocative Chromo-discography

Perform confirmatory contrast discography at this time. The following contrast mixture is used: nine cc of Isovue 300 with one cc of indigo carmine dye. This combination of contrast ratio gives readily visible radio-opacity on the discography images, and intra-operative light blue chromatization of pathologic nucleus and annular fissures which help guide the targeted fragmentectomy.

Discography is an integral part of selective endoscopic discectomy. The literature on discography is currently considered controversial. It is controversial partly because of the high inter-observer variability by discographers in reporting the patient’s subjective pain as well as the ailing patient’s inability to give a clear response, especially if pain response is altered by the use of analgesics or sedation during the procedure. The surgeon who is accomplished in endoscopic spine surgery should do the discography himself in order to decrease the inter-observer variability in interpreting the patient’s response and thus better select for appropriate patients.

3.d.4. Instrument Placement

Insert a long thin guide wire through the 18 gauge needle channel. Advance the guide wire tip, one to two centimeters deep into the annulus, then remove

the needle. Slide the bluntly tapered tissue dilating obturator over the guide wire until the tip of the obturator is firmly engaged in the annular window. An eccentric parallel channel in the obturator allows for four quadrant annular infiltration using small incremental volumes of one half percent lidocaine in each quadrant, enough to anesthetize the annulus, but not the nerves. Hold the obturator firmly against the annular window surface and remove the guide wire. Infiltrate the full thickness of the annulus through the obturator's center channel using lidocaine.

The next step is the through-and-through fenestration of the annular window by advancing the bluntly tapered obturator with a mallet. Annular fenestration is the most painful step of the entire procedure. Advise the anesthesiologist to heighten the sedation level just prior to annular fenestration. Advance the obturator tip deep into the annulus and confirm on the c-arm views. Now slide the beveled access cannula over the obturator toward the disc. Advance the cannula until the beveled tip is deep in the annular window. Remove the obturator and insert the endoscope to get a view of the disc nucleus and annulus.

Alternatively if you are worried about further extruding a large disc herniation or you want to inspect the outer annular fibers before fenestrating the annulus, the surgeon can engage the outer annulus with the blunt obturator. Then the beveled cannula is advanced over the obturator to the annulus. The obturator is removed and the endoscope is inserted. The outer annular fibers can be inspected to ensure that no neural structures are in the path of the cannula prior to the annulotomy. Then an annulotome or a cutting trephine can be used for the annular fenestration under direct vision. Prominent disc tissue can be removed prior to entering the disc with the cannula.

The foraminal annular window is an easily identifiable c-arm and intraoperative anatomic landmark and is the starting location for endoscopic disc excision. Through the endoscope, the surgeon may see various amounts of blue stained nucleus pulposus. The general purpose access cannula has a bevel hypotenuse of 12 mm and outside diameter of 7 mm. When the cannula is slightly retracted to the midstraddle position in relationship to the annular wall, the wide angle scope visualizes the epidural space, annular wall and the intradiscal space in the same field.

3.d.5. Performing the Discectomy

The basic endoscopic method to excise a non-contained paramedian extruded lumbar herniated disc via a uniportal technique is described here. First enlarge the annulotomy medially to the base of the herniation with a cutting forcep. The side-firing Holmium-YAG laser can also be utilized to enlarge and widen the annulotomy. This is performed to release the annular fibers at the herniation site that may pinch off or prevent the extruded portion of the herniation from being extracted. Directly under the herniation apex a large amount of blue stained nucleus is usually present, likened to the submerged portion of an iceberg. The nucleus here represents migrated and unstable nucleus. The endoscopic rongeurs are used to extract the blue-stained nucleus pulposus under direct visualization. (Figure 5) The larger straight and hinged rongeurs are used directly through the cannula after the endoscope is removed. Fluoroscopy and surgeon feel guides this step. By grabbing the base of the herniated fragment, one can usually extract the extruded portion of the herniation. Initial medialization and widening of the annulotomy reduce the prospect of breaking off the apex of the herniation. The traversing nerve root is readily visualized after removal of the extruded herniation. (Figure 6,7,8)

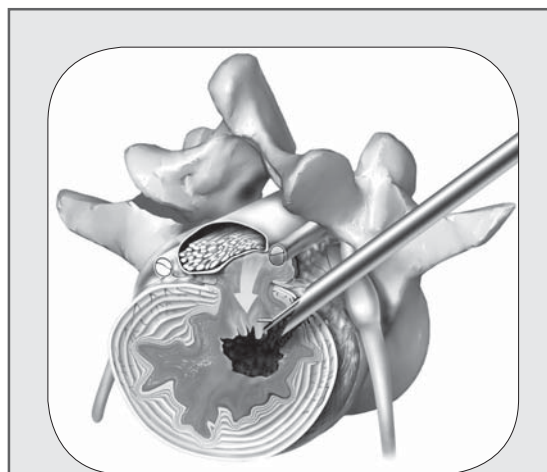

Figure 5:

Uniportal technique for selective endoscopic discectomy. Rongeurs are used for visualized fragmentectomy. The beveled cannula can be positioned to view the intradiscal cavity, annular wall, and epidural space in the same field of vision.

Next perform a bulk decompression by using a straight and flexible suction-irrigation shaver (Endius MDS). This step requires shaver head c-arm localization before power is activated to avoid nerve/dura injury and anterior annular penetration. The cavity thus created is called the working cavity. The debulking process serves two functions. First it decompresses the disc, reducing the risk for further acute herniation. Second it removes the unstable nucleus material to prevent future reherniation.

Inspect the working cavity. If a non-contained extruded disc fragment is still present by finding blue stained nucleus material posteriorly, then these fragments are teased into the working cavity with the endoscopic rongeurs and the flexible radio-frequency trigger-flex bipolar probe (Ellman) and removed. Creation of the working cavity allows the herniated disc tissue to follow the path of least resistance into the cavity. The flexible radio-frequency bipolar probe is used to contract and thicken the annular collagen at the herniation site. It is also used for hemostasis throughout the case.

The vast majority of herniations can be treated via the uniportal technique. Sometimes for a large central herniations the disc needs to be approached from both sides, biportal technique.

4. Potential Complications and Avoidance

As with arthroscopic knee surgery, the risks of serious complications or injury are low—about 1-3% in the author's experience. The usual risks of infection, nerve injury, dural tears, bleeding, and scar formation are always present as with any surgery. Transient dysesthesia, the most common post-op complaint, occurs about 5%-15% of the time and is almost always transient. Its cause is still incompletely understood and may be related to nerve recovery, operating adjacent to the dorsal root ganglion of the exiting nerve, or a small hematoma adjacent to the ganglion of the exiting nerve, as it can occur days or even weeks after surgery. Transient dysesthesia can occur even in cases where no adverse events were detected with continuous EMG and SEP neuromonitoring. Thus it cannot be completely avoided. The symptoms are like a variant of complex regional pain syndrome (CRPS), but less severe, and without the skin changes that accompany CRPS. Dysesthesia is readily treated by

transforaminal epidural blocks, rarely sympathetic blocks, and the use of Neurontin titrated up to 1800-3200 mg /day if needed.

Avoidance of complications is enhanced by the ability to clearly visualize normal and patho-anatomy, the use of local anesthesia and conscious sedation rather than general or spinal anesthesia, and the use of a standardized needle placement protocol. The entire procedure is usually accomplished with the patient remaining comfortable during the entire procedure and should be done without the patient feeling severe pain except when expected, such as during evocative discography, annular fenestration, or when instruments are manipulated past the exiting nerve. Local anesthesia using half percent xylocaine allows generous use of this dilute anesthetic for pain control and still allows the patient to feel pain when the nerve root is manipulated. Continuous EMG and SEP can also help monitor and prevent nerve irritation. This usually correlates well with the patients' intraoperative feedback.

5. Discussion

Endoscopic spine surgery has a very high learning curve, but is within the grasp of every endoscopic surgeon with proper training. As with any new procedure, the complication rate may be higher during the learning curve, and may vary with each surgeon's skills and experience. The endoscopic technique is safer for the patient since he is conscious and able to provide immediate input to the surgeon when pain is generated. The surgeon's ability to perform the surgery without causing the patient undue pain will self select for surgeons who can master the technique to the extent that the surgeon will prefer endoscopic over traditional surgery for the same condition. For most contained disc herniations and discogenic pain, the experienced endoscopic spine surgeon will opt for the endoscopic approach as the treatment of choice for his patients.

6. Case Presentation

6.a. History

A 22 year old male with a two year history of low back pain and intermittent right leg pain sustained an acute worsening of his right leg pain 12 days

prior to evaluation. He proportionalized his pain to 5% back and 95% leg pain. He complained of a new onset of weakness, tingling, and constant numbness. The pain and numbness radiated down the posterolateral leg to the dorsum of the right foot. He was unable to bear weight on the right leg and was using a walking pole for support. He was unable to sleep supine and had to sleep in a recliner to minimize the pain. Sitting provided some relief. He denied bowel or bladder incontinence, but had constipation for the last 12 days.

6.b. Physical Exam

Physical exam revealed an antalgic gait, limited lumbar extension to 10 degrees, tenderness in the right sciatic notch, positive straight leg raising (SLR) and Lasegue's tests, positive contralateral SLR, 2+ bilateral patella and Achilles deep tendon reflexes, decreased sensation to light touch over the dorsum of the foot and to a lesser extent the lateral border of the foot, and weakness. The right sided weakness was graded as 4/5 anterior tibialis, 2/5 EHL, 3/5 hip abductor, 4/5 gastroc-soleus.

6.d. Imaging

MRI revealed a large right paracentral/foraminal extruded herniated nucleus pulposus with slight cau-

dal migration causing compression of both the exiting and traversing nerve roots (Figure 9).

6.e. Treatment

Surgery was recommended due to the acute onset and progressive neurologic deficits. After a full discussion of his risks, benefits, and alternatives the patient elected to undergo outpatient selective endoscopic posterolateral discectomy. The patient experienced over 80% pain relief immediately post-op. He had some mild dysesthetic burning over the L4 distribution that started a few days post-op. This completely resolved by 4 weeks with the aid of neurontin 300mg TID. A post operative MRI was ordered when the patient had a acute worsening of his leg pain 11 days post op. (Figure 10) He said he "over did it". The patient's leg weakness was improving, but since some weakness was still present, we wanted to make sure he did not have a recurrent herniation. The MRI revealed excellent herniation removal without any retained fragments. The patient's acute pain resolved within 24 hours and he had no pain at all by 4 weeks. His weakness continued to improve grading 4/5 EHL, 4+/5 hip abductor, 4/5 anterior tibialis, and 5-/5 gastroc-soleus at his last follow up 2 months post-op.

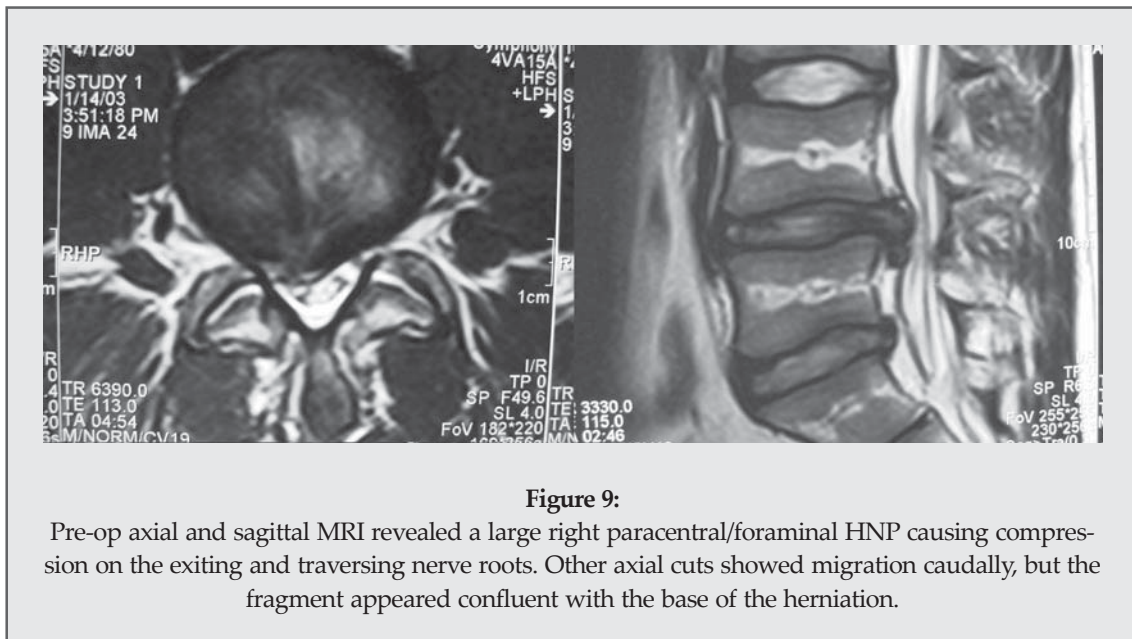
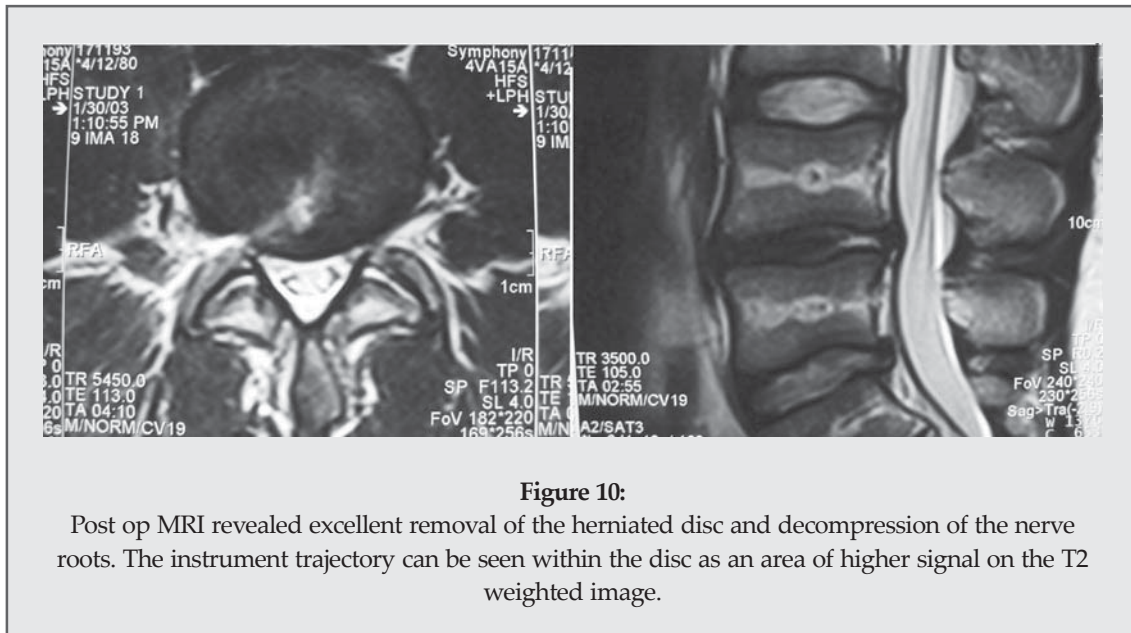


Figure 9:

Pre-op axial and sagittal MRI revealed a large right paracentral/foraminal HNP causing compression on the exiting and traversing nerve roots. Other axial cuts showed migration caudally, but the fragment appeared confluent with the base of the herniation.



7. References

- Bogduk N. The Innervation of the Intervertebral Disc. Chapter 5: 135-149. *The Biology of the Intervertebral Disc, Vol I.* Ghosh P ed. CRC Press, Boca Raton, FL. 1988.
- Luomaa K, Kilkka R, Luukkonen R, et al. Low Back Pain in Relation to Lumbar Disc Degeneration. *Spine* 2000;25:487-492
- Boden S, Herzog R, Rauschnig W, Rydevik B. Instructional Course Lecture #249: Lumbar Spine. *The Herniated Disc.* AAOS 67th Annual Meeting, 2000.
- Hadjipavlou AG, Simmons JW, Gaitanis IN, Goel VK. Etiopathogenesis of Disc Degeneration and Clinical Implication. In: Savitz MH, Chiu JC, Yeung AT, eds. *The Practice of Minimally Invasive Spinal Technique.* First edition. Richmond, VA. AAMISMS Education, LLC; 2000;16:149-170
- Farfan H. *Mechanical Disorders of the Low Back.* Philadelphia, PA: Lea & Febiger; 1973
- Bogduk N. *Clinical Anatomy of the Lumbar Spine and Sacrum,* 2nd Ed. Melbourn, Australia: Churchill Livingstone; 1996
- Adams MA, Hutton WC. Gradual Disc Prolapse. *Spine* 1985;10:524-531
- Adams MA, Hutton WC. Prolapsed Intervertebral Disc—A Hyperflexion Injury. *Spine* 1982;7:184-191
- Chaffin DP, Anderson GBJ. *Occupational Biomechanics.* New York, NY: Wiley Interscience; 1984:369-412
- Herzog RJ, Rydevick B, Boden SD. Instructional Course Lecture #310: Lumbar spine. *The Herniated Disc.* AAOS 70th Annual Meeting; February 7, 2003; New Orleans, LA
- Hermantin FU, Peters T, Quartararo L, Kambin P. A Prospective, Randomized Study Comparing the Results of Open Discectomy with those of Video-Assisted Arthroscopic Microdiscectomy. *JBJS* 1999; 81-A:958-965
- Hijikata S, Yamagishi M, Nakayma T. Percutaneous Discectomy: A New Treatment Method for Lumbar Disc Herniation. *J. Tokyo Den-ryoku Hosp* 1975;5:39-44
- Hijikata S. Percutaneous Nucleotomy. A New Concept Technique and 12 Years' Experience. *Clin. Orthop* 1989;238:9-23
- Kambin P, Gellman H. Percutaneous Lateral Discectomy of the Lumbar Spine. A Preliminary report. *Clin. Orthop* 1983;174:127-132
- Kambin P, Sampson S. Posterolateral Percutaneous suction-excision of Herniated Lumbar Intervertebral Discs. Report of Interim Results. *Clin. Orthop* 1986;207:37-43
- Kambin P, Brager MD. Percutaneous Posterolateral Discectomy. Anatomy and Mechanism. *Clin. Orthop* 1987;223:145-154. 1987.
- Kambin P, Schaffer JL. Percutaneous Lumbar Discectomy. Review of 100 Patients and Current Practice. *Clin. Orthop* 1989;238:24-34
- Kambin P. Arthroscopic Microdiscectomy. *Arthroscopy* 1992;8:287-295

19. Kambin P, O'Brien E, Zhou L, Schaffer JL. Arthroscopic Microdiscectomy and Selective Fragmentectomy. *Clin Orthop* 1998;347:150-167
20. Mathews HH. Transforaminal Endoscopic Microdiscectomy. *Neurosurg Clin N Am* 1996;7:59-63.
21. Mayer HM, Brock M: Percutaneous Endoscopic Discectomy: Surgical Technique and Preliminary Results Compared to Microsurgical Discectomy. *J Neurosurg* 1993;78: 216-225
22. Onik G, Helms CA, Ginsberg L, Hooglund FT, Morris J. Percutaneous Lumbar Discectomy Using a New Aspiration Probe. *Am. J. Roentgenol* 1985;144:1137-1140
23. Schaffer JL, Kambin P. Percutaneous Posterolateral Lumbar Discectomy and Decompression with a 6.9-Millimeter Cannula. Analysis of Operative Failures' and Complications. *JBJS* 1991;73-A 822-831
24. Schreiber A, Suezawa Y, Leu H. Does Percutaneous Nucleotomy with Discoscopy Replace Conventional Discectomy? Eight Years of Experience and Results in Treatment of Herniated Lumbar Disc. *Clin. Orthop* 1989;238:35-42
25. Tsou PM, Yeung AT. Transforaminal Endoscopic Decompression for Radiculopathy Secondary to Non-contained Intracanal Lumbar Disc Herniation. *Spine Journal* 2002; 2:41-48
26. Yeung AT. The Evolution of Percutaneous Spinal Endoscopy and Discectomy: State of Art. *Mt. Sinai J Med* 2000; 67:327-332
27. Yeung, AT. Minimally Invasive Disc Surgery with the Yeung Endoscopic Spine System (Y.E.S.S.). *Surgical Technology International VIII* 1999;1-11
28. Yeung AT, Tsou PM. Posterolateral Endoscopic Excision for Lumbar Disc Herniation. The Surgical Technique, Outcome and Complications in 307 Consecutive Cases. *Spine* 2002;27:722-731
29. Gogan WJ, Fraser RD. Chymopapain. A 10-Year, Double Blind Study. *Spine* 1992;17:388-94
30. Javid MJ, Norby E. Safety and Efficacy of Chymopapain (Chymodiactin) in Herniated Nucleus Pulposus with Sciatica – Results of a Randomized, Double Blind Study. *JAMA* 1983;249:2489-2494
31. Smith L. Chemonucleolysis. Personal History, Trials, and Tribulations. *Clin Orthop* 1993;287:117-124
32. Hoogland T, Scheckenbach C. Percutaneous Lumbar Nucleotomy with Low-dose Chymopapain, an Ambulatory Procedure. *Z Orthop Ihre Grenzgeb* 1995;133(2):106-13. German
33. Van de Belt H, Franssen S, Deutman R. Repeat Chemonucleolysis is Safe and Effective. *Clin Orthop* 1999;363:121-5
34. Deutman R. The Case for Chemonucleolysis in Discogenic Sciatica. A review. *Acta Orthop Scand.* 1992;63(5):571-5. Review
35. Yasargil MG. Microsurgical Operation of Herniated Lumbar Disc. In: Wullenweber R, Brock M, Hamer J, Klingler M, Spoerri O, eds. *Advances in Neurosurgery*, vol 4. Berlin, New York:Springer-Verlag; 1977:81-94
36. Williams RW. Microlumbar Discectomy: A conservative Surgical Approach to the Virgin Herniated Lumbar Disc. *Spine* 1978;3:175-82
37. Perez-Cruet MJ, Foley KT, Isaacs RE, et al. Microendoscopic Lumbar Discectomy: Technical Note. *Neurosurgery* 2002;51(5 Suppl):129-36
38. Knight MTN, Goswami AKD. Endoscopic Laser Foraminoplasty. In: Savitz MH, Chiu JC, Yeung AT, eds. *The Practice of Minimally Invasive Spinal Technique*. First edition. Richmond, VA. AAMISMS Education, LLC; 2000;42:337-40
39. Osman SG, Nibu K, Panjabi MM, Marsolais EB, Chaudhary R. Transforaminal and posterior decompressions of the lumbar spine. A comparative study of stability and intervertebral foramen area. *Spine* 1997;22(15):1690-5
40. Ito M, et.al. Transforaminal Surgery for Pyogenic Thoracolumbar Spondylodiscitis. Paper presented at: the American Academy of Minimally Invasive Spinal Medicine and Surgery 3rd World Congress; Dec 8-11, 2002; Phoenix, Arizona

5d

MICROENDOSCOPIC DISCECTOMY USING METRX SYSTEM

Mehmet Zileli MD, Vehbi Gulmen MD

1. Introduction:

Microendoscopic discectomy system (MED) was first introduced in 1997 by Foley and Smith ⁽¹⁾. Metrx system is the next generation of MED system. It allows surgeon to perform discectomy in a minimally invasive fashion ^(1,2). It also offers some advantages over other minimally invasive techniques ⁽³⁾. Thanks to this system, nerve roots are exposed directly, even far sequestered disc fragments may be decompressed effectively, while minimally affecting the surrounding tissues. Interlaminar space is approached by splitting paravertebral muscles with a small incision, approximately 1,5-2 cm long. By using tubular retractor system, contained lumbar disc herniations even sequestered disc fragments can be removed unlike other percutaneous approaches. The root that is compressed by lateral recess stenosis can also be decompressed by this system. A lateral approach may also be used so far lateral disc herniations can be removed effectively. A prospective clinical study has shown that treatment of lumbar disc herniation is effective by using microendoscopic technique ⁽⁴⁾.

2. Indications:

Lumbar disc herniation with or without sequestration is the most common indication of endoscopic discectomy. If the pain from one nerve root compression by disc herniation is not relieved by conservative treatment, endoscopic discectomy can be considered. Absolute indication for lumbar disc herniation is progressive muscle weakness. The common indication of discectomy is to obtain quick

relief of pain and disability ⁽⁵⁾. Endoscopic discectomy provides both rapid recovery and returning routine life as soon as possible. One level lumbar stenosis and lateral recess stenosis can be decompressed by the surgeon who is experienced in microendoscopic discectomy ⁽⁶⁾. High speed drill must be available to challenge for hypertrophied facet joints. MED system can also be used for foraminal or extraforaminal sequestration ⁽⁷⁾. We preferred to set the tubular retraction system lateral to the spinal channel between transvers processes. Isthmic part of lamina must be shaved to expose the foraminal sequestrations. The lateral and upper part of facet joint which is caudal from sequestration must be removed for exposing the extraforaminal disc herniations. MED system can be used for central, mediolateral, foraminal and extraforaminal disc herniations from L2-3 level to the L5-S1 level. MED system has also been used for posterior cervical foraminotomy, discectomy and thoracic discectomy and also for recurrent lumbar disc herniations ^(8,6,9).

3. Contraindications:

Contraindications are similar to standard discectomy. Coagulation disorders, using antiaggregant and anticoagulant drugs are main contraindications. Lumbar spinal stenosis is relatively contraindicated. Transverse and anterior-posterior length of the spinal canal must be measured preoperatively. Diameter of spinal canal lower than 15 mm is considered a contraindication for using tubular retraction system.

4. Surgical Procedures:

4.a. Surgical Equipments:

Surgical equipment can be classified according to their function.

- I. Visualization and illumination equipments
- II. Tissue retraction equipments
- III. Laminotomy and discectomy equipments

Visualization is obtained by endoscopic assembly of METRx system. Camera head and light cable is connected to endoscope via clockwise rotation. Camera head is connected to the video recorder and monitor. Light cable is connected to the cold light source. After connection is completed, white balance must be performed. For white-balancing, a white object is placed 1 cm apart from the lens of endoscope while pressing white balance button on video recorder. Now endoscopic system is ready to visualization.

Tissue retraction equipments include Kirshner wire, 5 muscle splitting tubes, one working tube and one flexible arm which can be fixed to the operating table. Diameters of the splitting tubes increases to the diameter of the working tube. Working tube has two accessory processes. One process is for connection to the flexible arm, the other one is for attachment of endoscopic system. If operating microscope is preferred for visualization, second process is not necessary. Flexible arm can be fixed by turning the circle clockwise for tube to be positioned. Circle is turned counter clockwise to release the arm and then positioning of the working tube. Endoscopic system is placed into the tube via a plastic ring tightened by an arm. This plastic ring has an aspiration part to remove the blood from operation field. Aspiration port can be used as an irrigation port to clean endoscopic eye.

Surgical instruments are similar to standart discectomy. Instruments used in MED are longer, thinner, bayonet-design and non-reflecting dark. However, surgeon has lost the skill of 3-D visualization while performing discectomy by MED system. That's why the disc remover has numbers which show the depth of disc remover tip. This is very important nuance to avoid injuring paravertebral tissues. Kerrison punch must have a 3 mm footplate. Both Kerrison punches oblique and straight must be available on the operation table. High speed drill is helpful for medial fac-

tectomy. Drill handle must be angled and must be the longest choice (Figure 1a).

4b. Operating room setup:

Operating room is arranged for surgeon to view both video monitor and fluoroscopy monitor. Surgeon stands on the same side of disc herniation. C-arm of fluoroscopy is placed under operation table. This allows fluoroscopic visualization in whole operation. C-arm is placed not to discomfort the surgeon (Figure 1b). Anesthesia is placed at the head side of the patient.

4.c. Patient positioning:

Operation can be performed under general or spinal anesthesia. Patient is positioned in prone with lumbar flexion. Silicon rolls or frames are advised to put on the anterior crista iliaca. Rolls must not compress both left and right femoral arteries. Silicon-made rolls help to prevent meralgia paresthetica. Care must be taken not to compress the abdomen by rolls to prevent epidural bleeding which can make the operation uncomfortable (Figure 1b).

4.d. Surgical Technique:

After surgical field is prepared by antiseptis rules, it is dried and draped. A 20-gauge needle is inserted into aimed level, just 1.5 cm lateral to the midline. The level is confirmed by fluoroscopic imaging (Figure 1c). If the level is correct, a K-wire is inserted after the needle is removed. K-wire must be aimed to the intervertebral disc space. Care must be taken not to enter the K-wire into the interlaminar space and then penetrate the spinal canal (Figure 1d-f). Skin is incised 1.6 cm for 1.6 m working tube (Figure 1g). Fasia can then be incised. Fasia incision makes it easy for dilator tubes to insert into the paravertebral muscles. Initial tube is inserted over the K-wire (Figure 1h). Surgeon feels the bone tissue through the muscles. Sequential insertion of dilator tubes splits muscles. Tip of dilator tubes dissect muscle which cover the lamina by medial to lateral, rostral to caudal movements. Finally, working tube is inserted over the dilator tubes (Figure 1i-m). After confirming the level by fluoroscopy, working tube is connected to flexible arm which is fixed to operating table. When appropriate position is obtained, flexible arm is tightened (Figure 1n-p).

Endoscope which was connected to the light source and camera cable before, is secured to the working

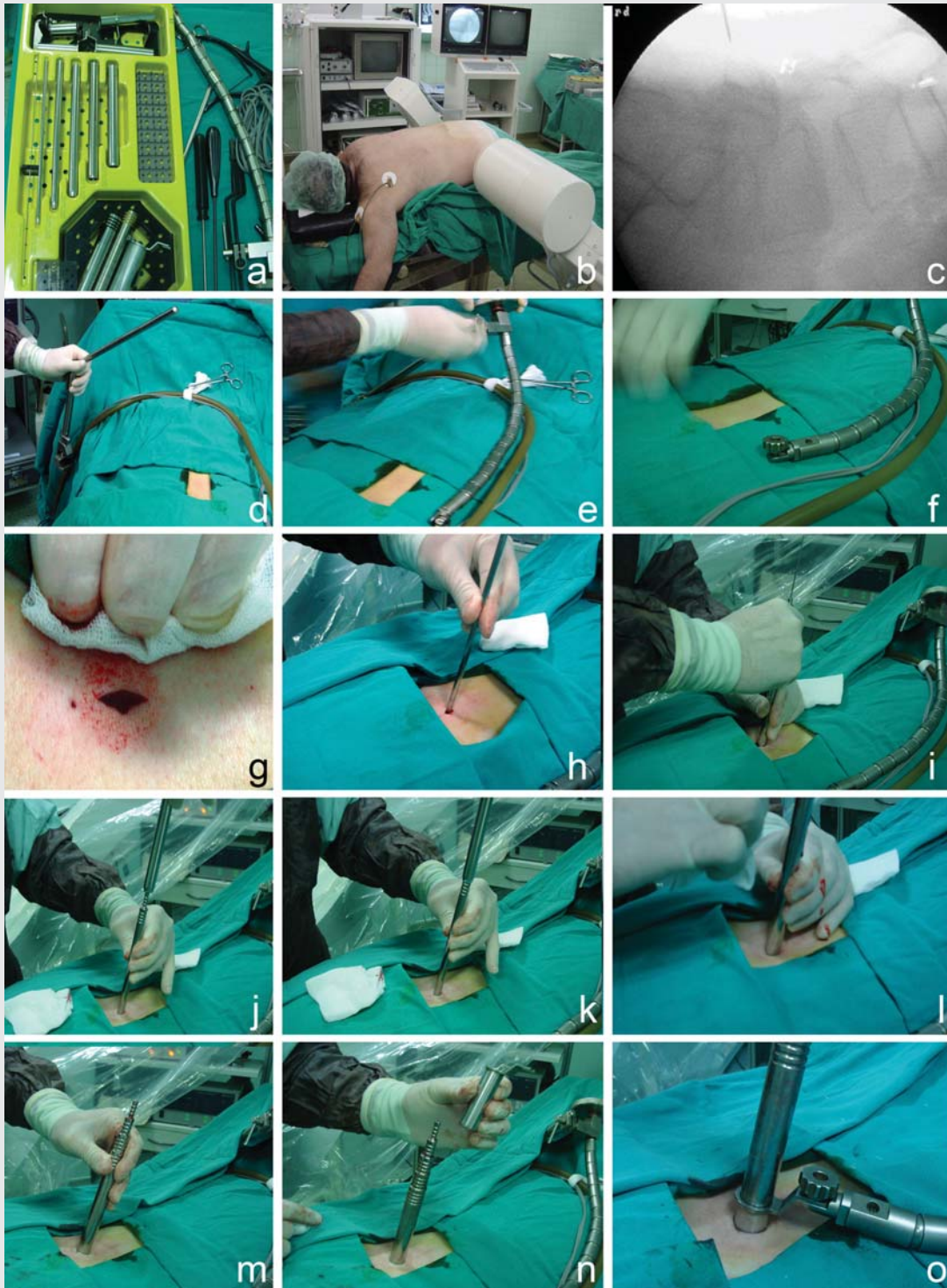


Figure 1:

Stages of the endoscopic discectomy using METRx system. METRx instruments set (a); Set-up of the surgical room must be prepared so that the surgeon can look the C-arm and monitor at the same time (b); A needle will help to learn the proper level (c); After sterile covers, retractor arm is fixed to the table (d); The flexible arm is placed on the tip of the arm and fixed (e,f); A 1.5 cm incision is done (g); The first dilator is inserted onto the K-wire (h); Other dilators are inserted and muscles are separated from the lamina by feeling of the surgeon (i,j,k,l,m); Working tube with 1.6 cm diameter is inserted around the last dilator (n,o).

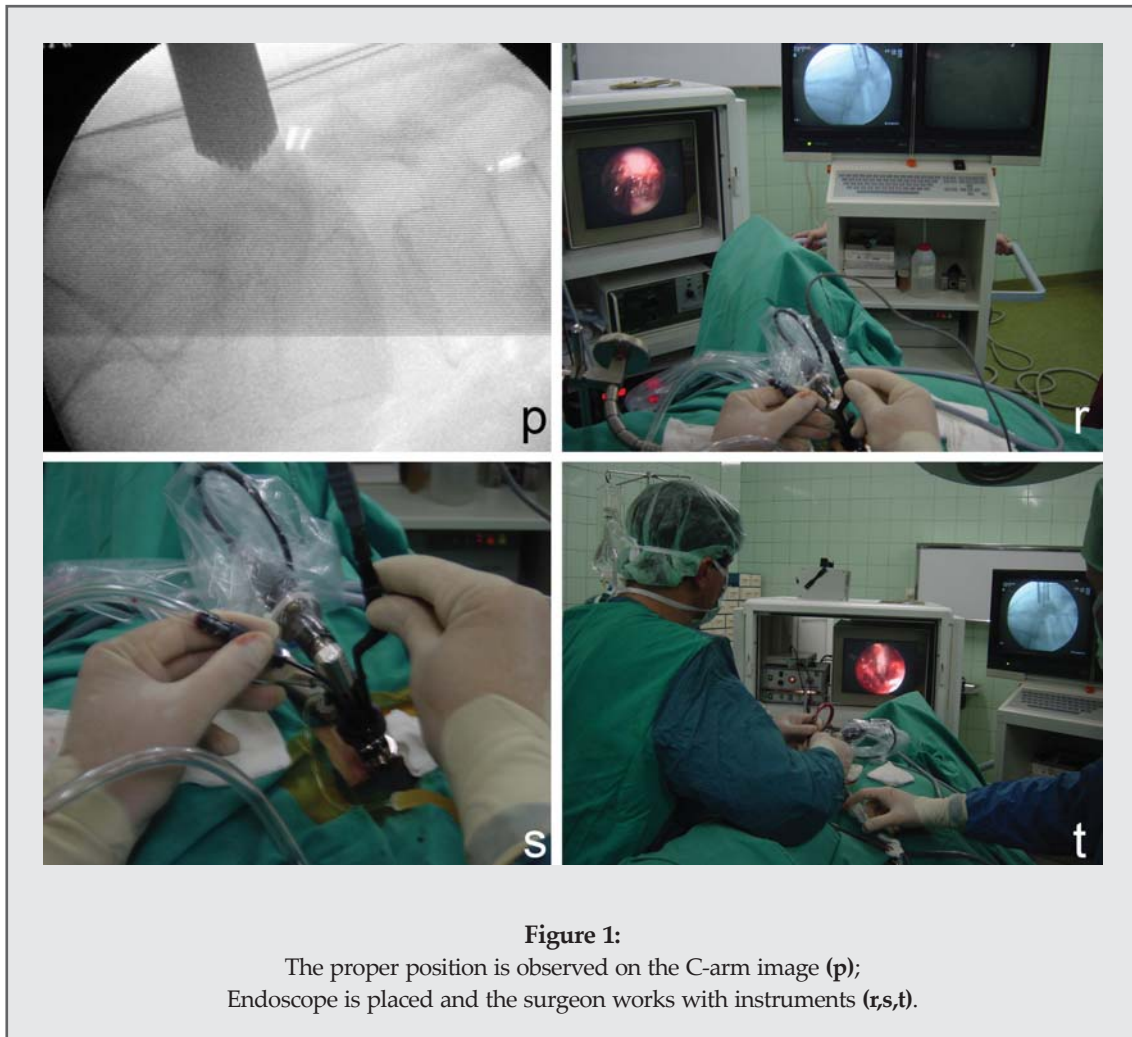


Figure 1:
The proper position is observed on the C-arm image (p);
Endoscope is placed and the surgeon works with instruments (r,s,t).

tube with a plastic ring. Arm of plastic ring is tightened for endoscope not to turn. Now it is ready to watch the operation from the monitor (Figure 1r-t).

Endoscopic view is focused by turning black ring on the MED endoscope. Yellow ring on the endoscope turns the image on video monitor. It is advised to arrange the view as in the standard discectomy. Lateral side is positioned in 6 o'clock, medial side is positioned in 12 o'clock on the monitor. A 'V' shaped recess is observed in the monitor. This recess shows the position of the endoscopic eye within the working channel. Orientation is confirmed with a curette. The curette must be observed in 12 o'clock position when it is directed to the midline. If it is correct, discectomy can be performed like as standard discectomy.

Muscles overlaying lamina, facet and interlaminar space must be removed. Bipolar cautery and scissors are used for this purpose. First, muscles are cauterized by bipolar, then dissected by scissors in Kerrison shape which is available in METRx endoscopic set. Using this method reduces bleeding. Lamina, facet and ligamentum flavum are exposed to maximize the visualization.

Laminectomy and medial facetectomy are performed. Laminectomy must not be enlarged up to the ligamentum flavum ending. If it is performed to the end of the ligamentum flavum, removing free ligamentum flavum will be difficult. Ligamentum flavum is removed in layers. A curette or No.15 scalpel may be used for this purpose. Each layer is removed by Kerrison punch. Dura and root are exposed. If

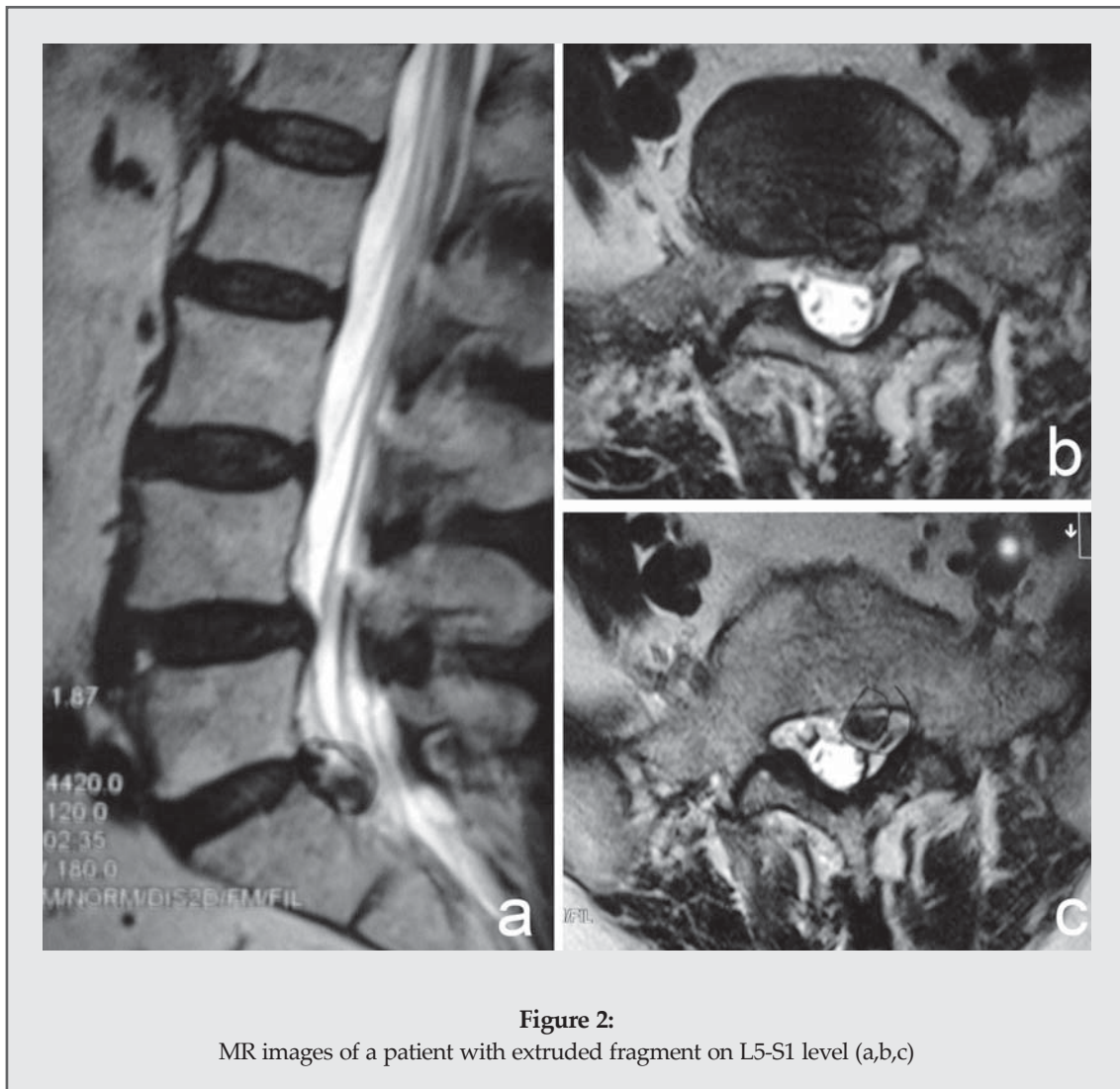
it is needed to angle the working tube, flexible arm can be released. At that time, working tube must be kept underpressure not to miss the muscles that were retracted before. Root is retracted by a hook to search the disc herniation. When the herniation or fragment is visualized, suction is performed by a specially designed retractor-suction tip. If posterior longitudinal ligament is intact, it is incised with a no 15 scalpel. Then discectomy is performed, up to root is well decompressed (Figure 2a-c). If there is a free fragment, other free fragments must be searched. The root is moved by hook for searching other fragments. Disc space may be irrigated by saline solution. Sometimes disc tissue is found by this maneuver. We prefer using local antibiotics to

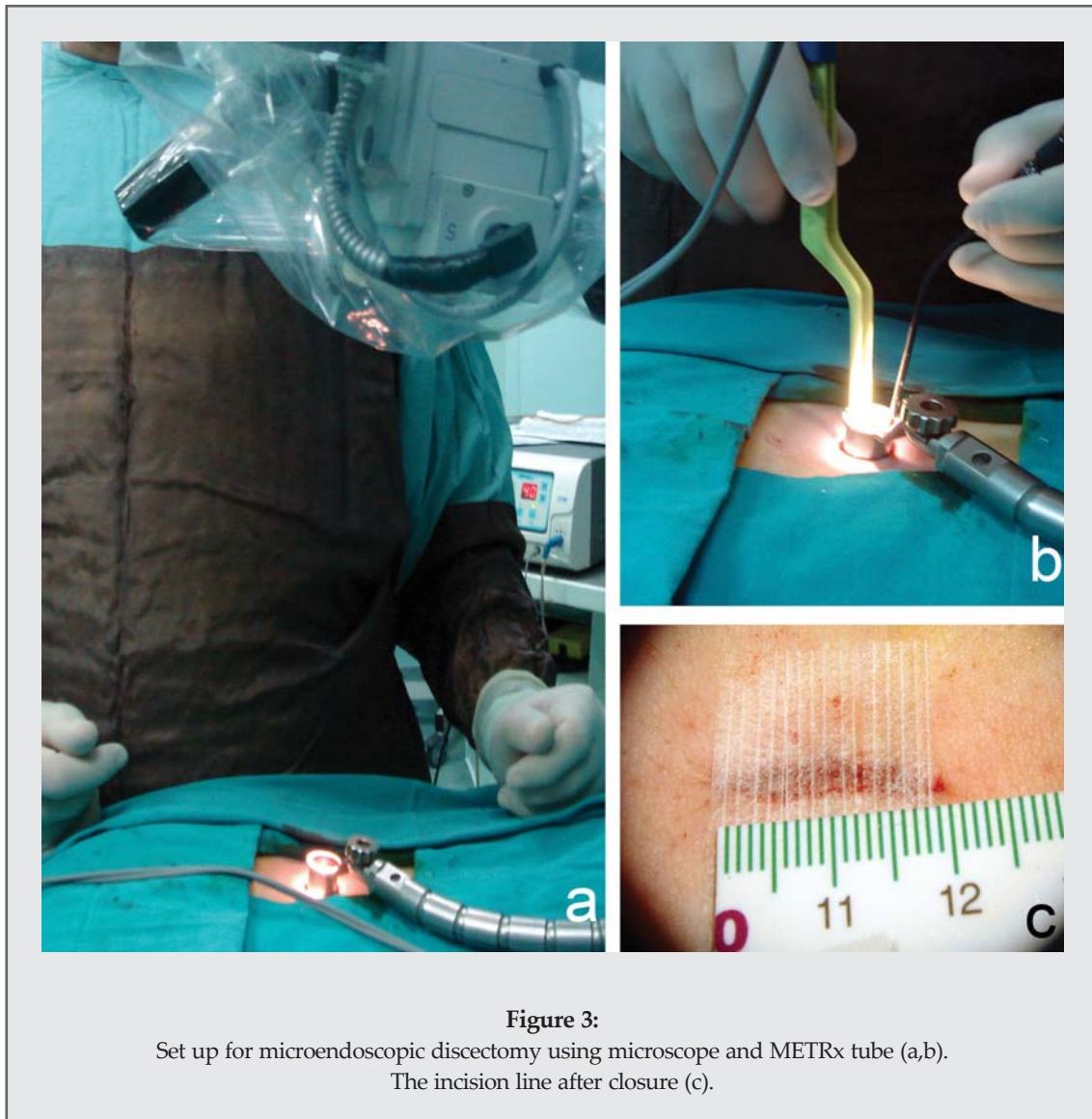
the disc space at the end of discectomy and never faced a discitis after irrigating the disc space with rifampicin. Bleeding is controlled by bipolar cautery or application of spongostan.

Flexible arm is released, working tube is withdrawn. Fascia is closed by interrupted one or two absorbable sutures. Skin is reapproximated with subcutaneous sutures or sterile skin adhesives.

Tubular Retraction System with Microscope

The METRx tubular retraction system can also be combined with an operation microscope, so a three dimensional imagination can be obtained (Figure 3a). Microscopic visualization in tubular retraction system gives a 90 degree working angle. On the other hand





endoscopic discectomy is performed by a 30 degree angle. Some surgeons believe that 30 degree angle has advantages⁽¹⁰⁾. It is useful for decompressing to contralateral lateral recess stenosis from an ipsilateral approach. However, it is possible to decompress contralateral recess stenosis by using microscopic discectomy with giving angle to the tubular retractions. Main disadvantage of using a microscope is reflection from tubular system. Arrangement of light source of microscope to the diameter lower than 1.5 cm can solve this problem (Figure 3b). Another disadvantage of using the microscope is touching the surgical instruments to the microscope's lens apparatus. The lens focussed more than 350 mm must be preferred when perform-

ing microscopic discectomy. Optic lens of endoscopic system sometimes becomes dirty with blood and with smoke from bipolar coagulation. In that instance, removing and cleaning the optic system is necessary. This increases the duration of the surgery and causes a disorientation in operation field.

5. Postoperative care:

After operation, patient is followed at postoperative care unit. If the vital functions are stable, patient is sent to his or her room. Family members are allowed to stay with patient at the room. Patient is

informed about the operative findings and what he or she must do. We advise the patient to lay in the bed for six hours in supine position. After the patient has wakened spontaneously and effect of spinal anesthesia has resolved, he or she is ambulated at postoperative eight hours. If there is no problem, patient is discharged with a family member or a friend or with a vehicle.

6. Complications and Avoidance:

Complications of endoscopic microdiscectomy are similar to those of standart discectomy. Dura laceration, root injury, epidural venous bleeding, injury to the paravertebral vessels and abdominal tissue, infections and neurological deterioration are the complications that may be seen.

Although it is not easy to repair dural tear via 16 mm tube, it may be performed using a microneedle holder. Atraumatic suture with maximum 12 mm round needle is advised for repairing. Dural graft matrixes like Dura Gen can also be used for covering dural tears. Fibrin glue can be placed on dural graft matrix. In that instance, fascia must also be approximated in a watertight fashion. In spite of all these measures, if CSF leakage occurs, lumbar external drainage must be considered for 3 to 4 days.

Microendoscopic discectomy is an instrument dependent operation. These instruments are fragile and must be handled with care. Angle of the working tube must not be changed unless flexible arm is fully released. Flexible arms and cables of light and endoscope must be placed away from surgeon's working corridor. Tip of the endoscope is cleaned with a soft and wet sponge. Handling of the tip of the endoscope must be very careful and crashing the endoscope tip to the metal faces should be avoided. While illumination, temperatures may exceed 41°C at the tip of the endoscope and 8 mm beyond. To avoid tissue burning, irrigation of the operation field must be done in intervals.

7. Conclusions:

Endoscopic microdiscectomy is an effective and safe choice for surgical treatment of lumbar disc herniation. It's not superior to the microdiscectomy in terms of clinical results. But it is not lower, either. Endoscope provides the surgeon working with a 30 de-

gree angle. But it doesn't have three dimensional imaging. Learning curve is longer for the surgeon who used to use operating microscope in the other spinal operations. Experienced surgeons can also overstep recurrent disc herniations, lumbar stenosis, cervical foraminotomy, discectomy for lateral lumbar disc herniation, thoracic discectomy by using METRx endoscopic system. Surgeon has a chance to unite tubular retractor system with operating microscope. It will be three dimensional visualization with minimally invasive fashion as we performed nowadays.

8. References:

1. Foley KT, Smith MM. Microendoscopic discectomy. *Tech Neurosurg* 1997; 3: 301-307.
2. Perez-Cruet MJ, Smith M, Foley K. Microendoscopic lumbar discectomy. In: Perez-Cruet MJ, Fessler RG (eds): *Outpatient Spinal Surgery*. St. Louis, Quality Medical Publishing, Inc. 2002, pp 171-183.
3. Gangi A, Dietemann JL, Ide C, Brunner P, Klinkert A, Warter JM: Percutaneous laser disk decompression under CT and fluoroscopic guidance: Indications, techniques and clinical experience. *Radiographics* 1996; 16: 89-96.
4. Brayda-Bruno M, Cinella P. Posterior endoscopic discectomy (and other procedures) *Eur Spine J* 2000; 9 (Suppl 1): S24-9.
5. Gibson JNA, Waddell G. Surgical interventions for lumbar disc prolapse *Spine* 2007; 32: 16: 1735-1747.
6. Khoo LT, Khoo KM, Isaacs RE, Fessler RG. Endoscopic lumbar laminotomy for stenosis. In: Perez-Cruet MJ, Fessler RG (eds): *Outpatient Spinal Surgery*. St. Louis, Quality Medical Publishing, Inc. 2002, pp 197-215.
7. Gupta S, Foley K. Endoscopic far lateral lumbar microdiscectomy. In: Perez-Cruet MJ, Fessler RG (eds): *Outpatient Spinal Surgery*. St. Louis, Quality Medical Publishing, Inc. 2002, pp 185-195.
8. Adamson TE. Microendoscopic posterior cervical laminoforaminotomy for unilateral radiculopathy: Results of a new technique in 100 cases. *J Neurosurg* 2001; (Suppl 1) 95: 51-57.
9. Khoo LT, Perez-Cruet MJ, Laich DT Fessler RG. Posterior cervical microendoscopic foraminotomy. In: Perez-Cruet MJ, Fessler RG (eds): *Outpatient Spinal Surgery*. St. Louis, Quality Medical Publishing, Inc. 2002, pp 71-93.
10. Perez-Cruet MJ, Foley K, Isaacs RE: Microendoscopic lumbar discectomy: Technical note. *Neurosurgery* 2002; 51 (Suppl 2) 129-136.

5 PERCUTANEOUS TRANSPEDICULAR SCREW INSERTION TECHNIQUE (SEXTANT)

Ahmet Levent Aydın MD, Mehdi Sasani MD

1. Introduction:

Boucher was the first to use screws that crossed through the strongest point of attachment of the facet joint into the pedicle and the body of the vertebra below. He declared a pseudarthrosis rate of 14% to 17% including multilevel fusions ⁽¹⁾.

The use of pedicle screw-assisted spinal stabilization has become increasingly popular worldwide. Pedicle screw systems engage all three columns of the spine and can resist motion in all planes. Analysis of several studies suggests that pedicle screw fixation is a safe and effective treatment for many spinal disorders ^(2,3). The pedicle screw-bone junction provides the strongest point of attachment of the instrument to the spine. Thus, pedicle screw fixation systems can resist motion in all planes ⁽¹⁾.

Pedicle screws have dramatically improved the outcomes of spinal reconstruction requiring spinal fusion. Short-segment surgical treatments based on the use of pedicle screws for the treatment of neoplastic, developmental, congenital, traumatic, and degenerative conditions have been proved to be practical, safe, and effective ⁽⁴⁾. The funnel technique provides a straightforward, direct, and inexpensive way to very safely apply pedicle screws in the cervical, thoracic, or lumbar spine. Carefully applied pedicle-screw fixation does not produce severe or frequent complications. Pedicle screw fixation can be effectively and safely used wherever a vertebral pedicle can accommodate a pedicle screw—that is, in the cervical, thoracic, or lumbar spine. Pedicle-screw fixation represents the so-called gold standard of spinal internal fixation ⁽⁴⁾.

Pedicular fixation is a relatively safe procedure and is not associated with a significantly higher com-

plication risk than non-pedicular instrumentation. It provides short, rigid segmental stabilization that allows preservation of motion segments and stabilization of the spine in the absence of intact posterior elements, which is not possible with non-pedicular instrumentation ⁽⁵⁾. The stiffness of the pedicle fixation allows for the incorporation of fewer normal motion segments to achieve stabilization of an abnormal level. Fusion rates and clinical outcome in the treatment of thoracolumbar fractures appear to be superior to that achieved using other forms of treatment. For the correction of spinal deformity (i.e., scoliosis, kyphosis, spondylolisthesis, tumor), pedicular fixation provides the theoretical benefit of rigid segmental fixation and of facilitated deformity correction by a posterior approach, but the clinical relevance so far remains unknown ⁽⁵⁾.

2. Disadvantages and Complications:

Disadvantages and complications of percutaneous transpedicular systems are more or less the same with conventional pedicular screw applications. Some of the complications are less with the sextant system because of applying it under fluoroscopic control. So complications as misplaced screws, nerve root injury, spinal cord injury, pedicular fracture, CSF fistula, damage to retroperitoneal structures are less with this system. But considering the percutaneous systems, a more steep learning curve is required. Caudal or medial penetration of the pedicle cortex may result in durotomy or neural injury.

As in the conventional pedicle screw systems, screw pullout, breakage and toggle, hardware failure or failure at the screw-bone junction are the

most frequently encountered problems in percutaneous transpedicular screw systems.

In general, early complications of transpedicular stabilization of the spine are unusual and are infrequently associated with permanent morbidity. There is however a high proportion of postoperative radiographic failures, of about 40% rate (Mostly screw loosening, angulation or fracture). Implant removal was required in about 15% of the cases within a year. However, traditional open surgical methods for the insertion of posterior instrumentation have several disadvantages including the risk of significant blood loss, the potential for serious infections, and the need for extensive paraspinous muscular dissection. Extensive dissection may lead to muscular denervation and necrosis resulting in prolonged postoperative pain and disability. For these reasons, the development of minimally invasive techniques to achieve spinal fixation would appear desirable.

Although methods of percutaneous pedicle screw and rod fixation have been developed, these techniques become more difficult to apply between three adjacent pedicle screws and in the presence of bony impediments to rigid rod passage. In addition, the precurved metal rods used in these techniques do not allow for rod shaping. Postoperative imaging techniques (especially MRI) are in part obscured by the implant. Rigid fixation can accelerate adjacent motion segment degeneration⁽¹⁾.

Due to its minimally invasive insertion, the new pedicle screw and rod fixation system may potentially reduce procedural morbidity, decrease paraspinous muscle denervation and necrosis, and speed postoperative recovery^(6,7). Infection rate is lower than the conventional pedicle fixation systems because of less retraction of the muscle tissue decreases muscle necrosis and lessens the risk of infection⁽⁸⁾.

In 1977 the technique of percutaneous pedicle screw placement in the lumbar spine was introduced by Magerl⁽⁹⁾. Although initially described for the management of spinal fractures and infections,⁽¹⁰⁾ the indications for the technique changed with the rapid improvement of more sophisticated internal fixation devices. Therefore, during the last decade the percutaneous technique of pedicle screw placement has been used almost exclusively for the temporary stabilization of spinal segments during an external fixation test. With the increasing popularity of pedicle screw fixation devices for sev-

eral indications, the safety and reliability of screw insertion in the small pedicle has become a major issue. Many studies have investigated the accuracy of screw placement by a conventional open approach using simple radiograph, computed tomography (CT) scan or magnetic resonance imaging (MRI)^(11,12).

With integration of robotic, endoscopic, and image-guided systems, we are embarking on exciting new frontiers with minimally invasive spine surgery. Complex spinal instrumentation can then be accomplished with more precision through small portals, thus reducing morbidity, lessening postoperative discomfort, reducing time in the intensive care unit, reducing hospitalization, decreasing medication, creating less disability, and reducing expenses⁽¹¹⁻¹³⁾.

The insertion of percutaneous lumbar pedicle screws has been previously reported⁽¹³⁾. But a minimally invasive technique involving insertion of a longitudinal connector for these screws has proven more challenging. The Sextant system (*Sextant; Medtronic Sofamor Danek, Memphis, TN*) allows for the straightforward placement of lumbar pedicle screws and rods through percutaneous stab wounds. Although percutaneous lumbar pedicle screw placement has been described previously, longitudinal connector (rod or plate) insertion has been more problematic. The sextant device allows for straightforward placement of lumbar pedicle screws and rods through percutaneous stab wounds. Paraspinous muscle trauma is minimized. The quality of spinal fixation is similar to the conventional techniques. An existing multiaxial lumbar pedicle screw system was modified to allow screws to be placed percutaneously by using an extension sleeve that permits remote manipulation of the polyaxial screw heads and remote engagement of the screw-locking mechanism. A unique rod-insertion device was developed that linked to the screw extension sleeves, allowing for a precut and contoured rod to be placed through a small stab wound. The insertion device relies on the geometrical constraint of the rod pathway through the screw heads⁽¹¹⁾. So, minimal manipulation is required to place the rods in a standard submuscular position and there is essentially no muscle dissection, and the need for direct visual feedback is avoided. The screws and rods in this system are placed in an anatomical position similar to that achieved by an analogous open surgical approach. Paraspinous tissue trauma is greatly

minimized without sacrificing the quality of the spinal fixation.

One advantage of percutaneous screw placement over the conventional open procedure, however, is that it is much easier to achieve the required medial angulation because extensive soft-tissue and muscle retraction is avoided ⁽¹¹⁾.

3. Surgical Procedure:

3.a. Operating Room Set up:

The surgical team setup consists of spine surgeon, anesthesiologist, scrub nurse and technician for the fluoroscopy. The fluoroscopy is wrapped with sterile cover and the C arm is located around the lumbar spine of the prone patient for real time imaging. The surgical table must be radiolucent so that both lateral and anterior-posterior imaging is possible.

3b. Surgical Equipment and Patient Positioning:

Usually preoperative plain radiographs and a CT scan should be examined to determine bone quality, pedicle transverse diameter and screw trajectory. Surgical radiolucent spinal frames are useful, particularly for AP radiographs.

Posterior percutaneous lumbar fixation system can be performed after induction of either general or epidural anesthesia (Figure 1a, b). The patient is positioned prone on top of chest rolls so that the abdomen free. C-arm fluoroscopy device should be used for percutaneous screw guidance (Figure 2a, b). It is important to determine whether adequate AP and lateral fluoroscopic images of the lumbar spine can be obtained before preparing and draping the patient.

3.c. Surgical Technique:

After cleaning and clotting the operation area, a dynamic reference array is first used to determine the projections of pedicle under biplanar fluoroscopy. The targetting of the pedicle is done and approximately 15-mm incision is made at the skin entry point and extended into the underlying subcutaneous tissue. A K-wire is used to perforate the fascia, and a series of sequential dilators are then used to dilate the fascia and to separate bluntly the underlying paraspinous muscles down to the spine at the

one side of the vertebrae (Figure 3a,b). The dilators are removed, and both a tracked awl and a pedicle probe are used to create a pedicle pilot hole under virtual fluoroscopic guidance (Figure 3c).

Using real-time multiplanar virtual fluoroscopy image guidance, the chosen pedicles are tapped and screws are placed (Figure 3d,e). A thorough knowledge of pedicle-related anatomy and the sagittal and axial angulation of the individual pedicles is mandatory for safe percutaneous screw placement. These angles are best judged using preoperative computerized tomography or magnetic resonance imaging of the lumbar region. Alternatively, the pedicle can be navigated by using a conventional C-arm fluoroscope that is alternated between AP, lateral, and oblique views. If this technique is chosen, one must obtain multiple sequential images of the pedicle probe in at least two planes as it is advanced down the pedicle. It is important to keep these trajectories in mind to ensure the accuracy of the percutaneous screw placement (One advantage of percutaneous screw placement over the conventional open procedure, however, is that it is much easier to achieve the required medial angulation because extensive soft-tissue and muscle retraction is avoided) ⁽¹²⁾.

The multiaxial Sextant pedicle screws are attached to screw extenders, which have inner and outer sleeves. The inner extender sleeve is designed to be preloaded with a lock plug, which will eventually connect the screw to the rod. The outer sleeve actually extends over the multiaxial screw head. The inner sleeve starts in a first position that allows the lock plug to be partially advanced into the multiaxial screw head, by which the screw is connected to the extender-sleeve combination. The screw head remains mobile on its shank. Thus, the screw head can be manipulated remotely (rotated and angulated) by moving the far end of the screw extender even after the screw has been placed within the pedicle ⁽¹²⁾

After a pair of pedicle screws, together with their attached extenders, has been inserted, a Sextant rod is placed. The Sextant rods are precontoured into a curvilinear shape that precisely matches the contour of the Sextant rod inserter. The rods are designed to fix rigidly to the inserter, forming a smooth arc. Additionally, the Sextant inserter attaches to the screw extenders. The resulting arrangement resembles the navigational device of the same name ⁽¹²⁾.




Figure 1a, 1b:
The surgical equipment is seen.

The screw extenders are aligned at their proximal ends. This maneuver arranges the distal ends, which are connected to the multi-axial screw heads, in a way that allows the openings in the screw heads to fit the same curvilinear path of the precontoured rod. The geometrical configuration is such that this path is identical to the arc created by the rod–Sextant rod inserter union. In fact, once the joined screw extenders are attached to the rod inserter, this geometrical relationship is constrained. The arc, subtended by the inserter–rod combination, must now follow the path connecting both screw heads⁽¹²⁾ (Figure 3f,g).

After the screw extenders have been connected to the Sextant rod inserter, a trochar tip is attached to the inserter. The skin is marked where this tip intersects it, and a small stab wound is made using a No. 15 blade. The trochar tip serves to open the underlying fascia. Once the fascia has been penetrated, the tip is removed and a Sextant rod is attached. The rod is inserted through the same stab wound and intersects the screw heads. This is checked fluoroscopically. Appropriate forces (compression and/or distraction) can be applied to the construct prior to final tightening. The inner sleeves are now advanced to their second position, allowing a hex driver to be in-

serted and to permit tightening of the lock plugs^(12,13). The lock plugs are designed with a torque-limiting breakoff, which allows simultaneous locking of the rod to the screw while the extension sleeve detaches. The Sextant itself serves as a counter-torque device. The rod is remotely released from the Sextant inserter, and the latter is removed from the field, leaving a percutaneous rod–screw combination in place. The procedure can be repeated on the contralateral side of the spine (Figure 3h,i,j,k,l), after which the stab incisions are irrigated and closed. The operative time ranges from 90 to 220 minutes; the longer times occur early in the learning curve^(12,13).

4. Discussion:

Percutaneous fixation of the lumbar spine was first described by Magerl⁽⁹⁾. He used an external fixator. Mathews and Long⁽¹³⁾ described and performed a wholly percutaneous lumbar pedicle fixation procedure in which they used plates as the longitudinal connectors. They noted a high rate of nonunion⁽¹¹⁾. Lowery and Kulkarni⁽⁸⁾ subsequently described a similar procedure in which rods were placed. They reported a high success rate. In all cases, the longitudinal connectors were placed either externally or superficially, just beneath the skin where the hardware can be irritating and requires routine removal. Also longer screws (and thus longer moment arms) are required, producing less effective biomechanical stabilization than that achieved using standard pedicle fixation systems and thus leading to a higher implant failure–related potential.

The use of the Sextant system, with or without virtual fluoroscopy, offers several distinct advantages over conventional pedicle screw fixation. The system eliminates the need for a large midline incision and significant paraspinous muscle dissection. Both the pedicle screws and the precontoured rod are placed through stab incisions. The paraspinous muscles are bluntly split rather than divided, leading to potentially shorter periods of hospitalization and recovery. Blood loss and tissue trauma are minimized. An ideal lateral-to-medial screw trajectory is much more easily accomplished, especially in larger patients, because significant paraspinous tissue retraction is avoided.

Compared with previously used percutaneous techniques, the Sextant procedure allows the screw–rod system to be placed in a standard anatomical position. This optimizes the biomechanics of the fixation and keeps the hardware in place without irri-

tating the superficial tissues of the low back, thus avoiding routine hardware removal. In addition, this technique minimizes much of the “fiddle factor” related to connecting a percutaneous rod or plate to pedicle screws. The inserter geometrically constrains the rod’s pathway, simplifying insertion of the rod. The cannulated extension sleeves allow the lock plugs to be quickly and easily seated against the rod and thereby simplifies screw–rod connection. Because the Sextant inserter remains connected to the screws and rods, appropriate forces (compression and distraction) can be applied to the construct prior to final tightening⁽¹¹⁻¹³⁾.

The technique involved in placing the Sextant system follows these same principles, allowing the surgeon to perform biomechanically sound internal spinal fixation with minimal tissue trauma. Minimally invasive approaches for performing lumbar fusion are in their infancy. The goal of these surgeries, as for all minimally invasive procedures, is to minimize approach related morbidity while achieving the same result as more traditional, invasive approaches⁽¹⁴⁾.

5. Postoperative Care:

There is no special consideration regarding postoperative care after this procedure. After completion of the operation, the stab incisions are irrigated and closed. The patient is extubated at the end of the operation and transferred to his/her bed. The feeding of the patient can be started after the sounds of intestinal movements. The appropriate analgesics and anti inflammatory drugs can be inserted if the patient needs. Patients could be mobilized within the five –six hours after this minimal invasive surgery. Fifty percent of the patients are discharged on postoperative day 1 or 2. The patient can return his job 2 weeks after operation.

6. Case Illustrations:

A 45 year-old male, admitted to our emergency department with back pain after falling down the stairs. The neurological examination of the patient was normal except severe back pain. The thoracic and lumbar direct graphies and MRI images revealed L2 vertebra compression fracture. There were no compression to the spinal cord at the lumbar CT and MRI and posterior wall of the vertebra corpus was intact (Figure 4a,b).

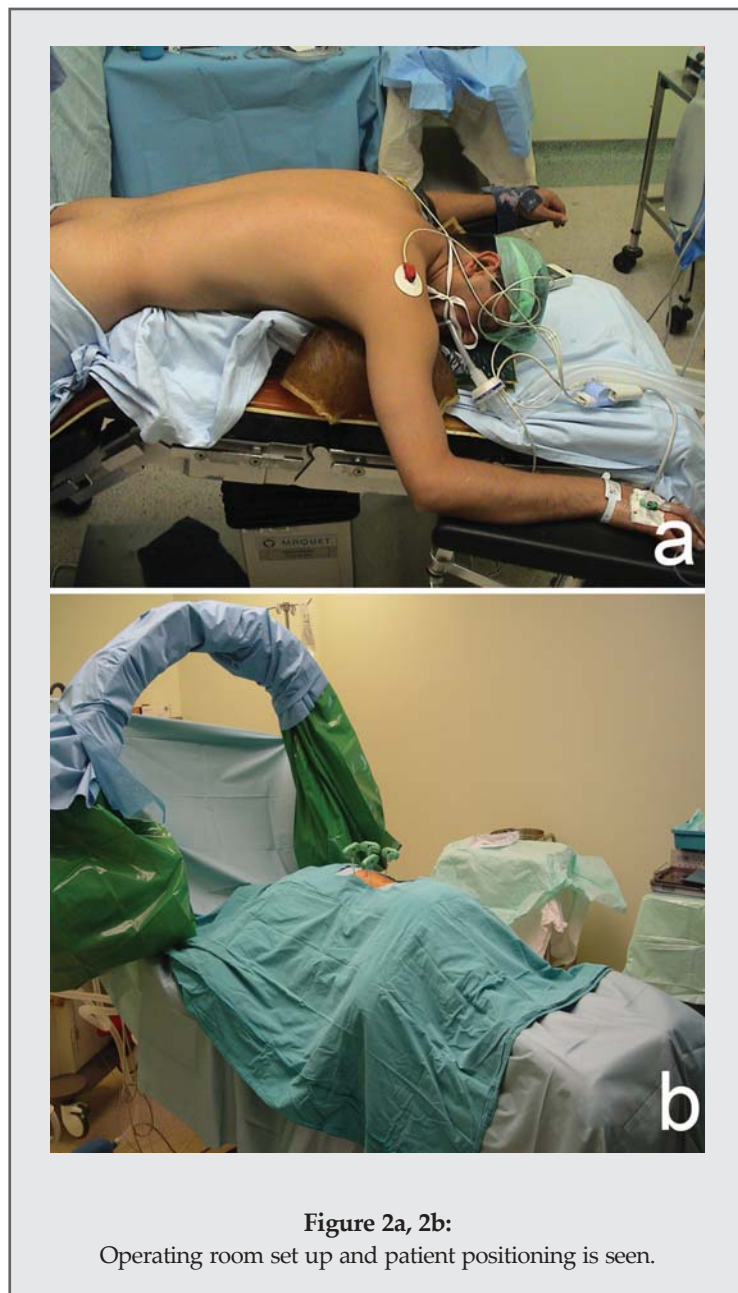

Figure 2a, 2b:

Operating room set up and patient positioning is seen.

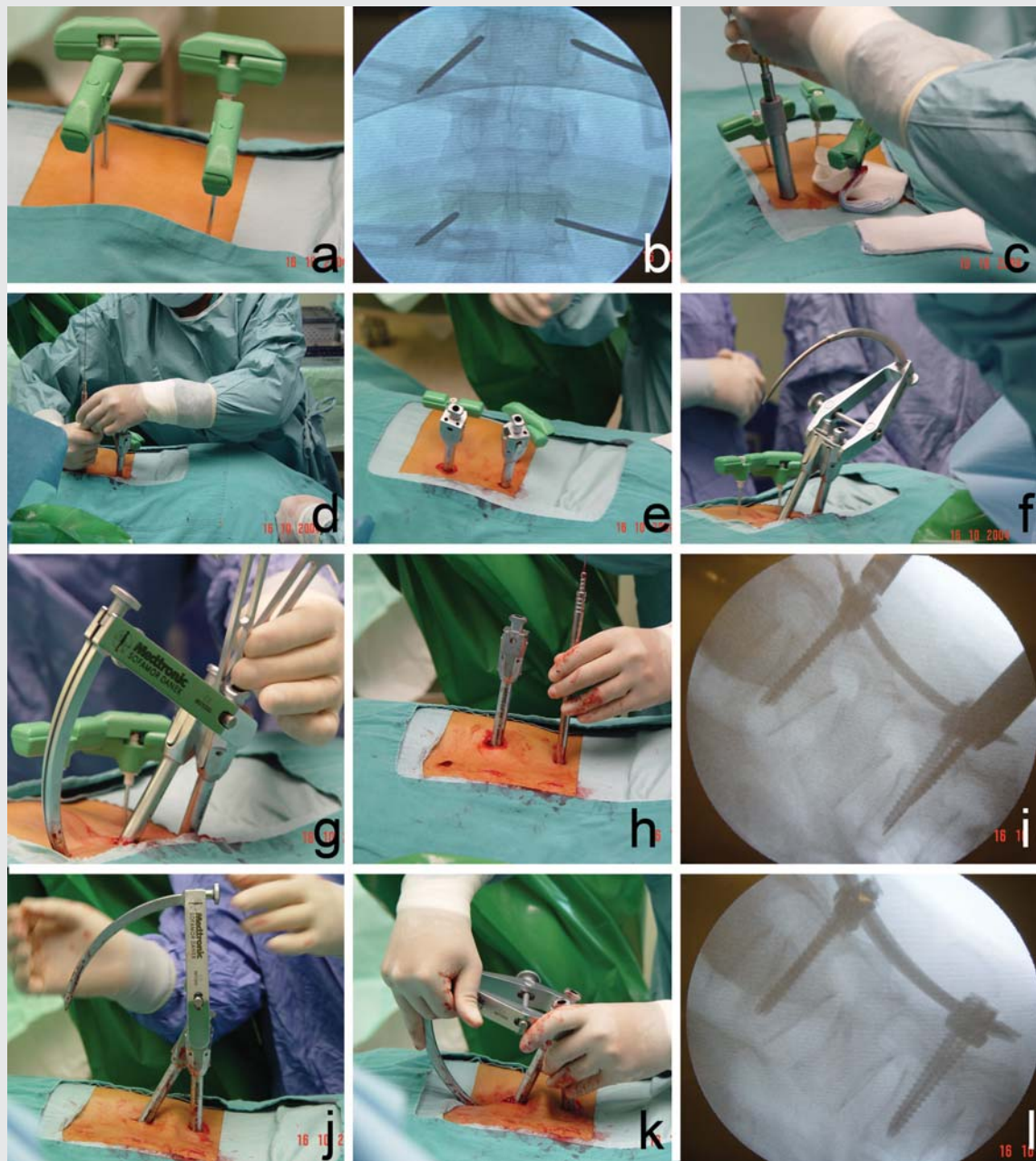


Figure 3:

a,b) The K-wires are used to perforate the fascia and underlying paraspinal muscles and also the pedicles are targeted under fluoroscopy, **c)** A series of sequential dilators are then used to dilate the fascia and paraspinal muscle, **d,e)** The screw extender, after the screw has been placed within the chosen pedicle, **f,g)** The arc, subtended by the inserter-rod combination and the rod is inserted through the stab wound, **h,i)** A series of sequential dilators are used to the opposite side and the screws are placed with the screw extender, **j,k)** The arc, subtended by the inserter-rod combination and the rod is inserted to the opposite side, **l)** The lateral fluoroscopy view after the operation.

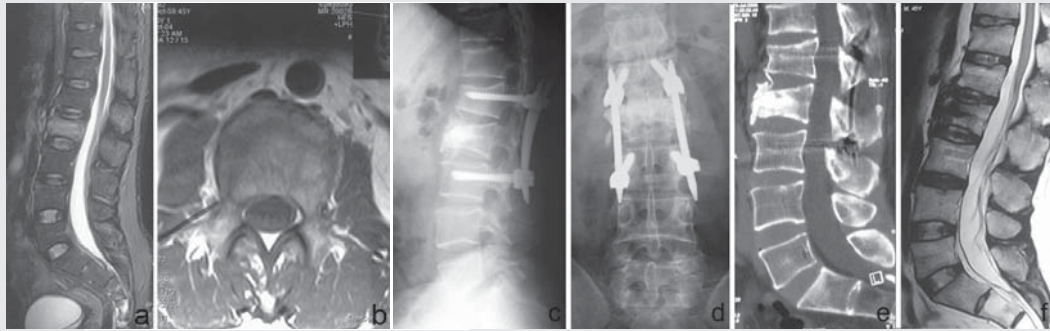


Figure 4:

a,b) Preoperative T2 weighted sagittal and axial MRI images of the patient showing the L2 vertebra compression fracture, **c,d)** Postoperative AP and lateral X-ray graphies of the patient showing the L2 vertebra kyphoplasty and L1-3 percutaneous transpedicular stabilization, **e,f)** Postoperative sagittal CT reconstruction and sagittal T2 weighted MRI images showing the L2 vertebra kyphoplasty and L1-3 percutaneous transpedicular stabilization.

Percutaneous kyphoplasty was performed to the L2 vertebra corpus with posterior percutaneous stabilization to the L1-3 vertebrae (Figure 4c,d,e,f). The patient was mobilized the day after operation and discharged at the second day after the operation. The follow-up of the patient was unevenful.

7. References:

- Halliday AL, Zileli M, Stillerman CB, Benzel EC: Dorsal Thoracic and Lumbar Screw Fixation and Pedicle Fixation Techniques. In Spine Surgery: Techniques, Complication Avoidance, and Management. Benzel EC (ed). Churchill Livingstone, Philadelphia. 2004 pp. 1053-1065.
- Gaines RW Jr. The use of pedicle-screw internal fixation for the operative treatment of spinal disorders. J Bone Joint Surg 2000; 82:1458-1476.
- Yuan HA, Garfin SR, Dickman CA, et al. A historical cohort study of pedicle screw fixation in thoracic, lumbar, and sacral spinal fusions. Spine 1994; 19: 2279-96,
- Gaines RW Jr. The use of pedicle-screw internal fixation for the operative treatment of spinal disorders. Review. J Bone Joint Surg 2000; 82: 1458-76,
- Boos N, Webb JK. Pedicle screw fixation in spinal disorders: A European view. Review. Eur Spine J 1997; 6: 2-18.
- Teitelbaum GP, Shaolian S, McDougall CG, Preul MC, Crawford NR, Sonntag VK. New Percutaneously Inserted Spinal Fixation System. Spine 2004; 29: 703-709.
- Thomsen K, Christensen FB, Eiskjaer SP. The effect of pedicle screw instrumentation on functional outcome and fusion rates in posterolateral lumbar spinal fusion: A prospective, randomized clinical study. Spine 1997; 22: 2813-2822.
- Lowery GL, Kulkarni SS. Posterior percutaneous spine instrumentation. Eur Spine J 9: 126-130, 2000.
- Magerl F. Verletzungen der Brust- und Lendenwirbelsäule. Langenbecks Arch Chir 1980; 352: 428-33.
- Magerl F. Stabilization of the lower thoracic and lumbar spine with external skeletal fixation. Clin Orthop 1984; 189: 125-41.
- Foley KT, Gupta SK. Percutaneous pedicle screw fixation of the lumbar spine: preliminary clinical results J Neurosurg (Spine 1) 2002; 97:7-12.
- Foley KT, Gupta SK, Justis BS, Sherman MC. Percutaneous pedicle screw fixation of the lumbar spine. Neurosurg Focus 2001; 10 (4): Article 10.
- Mathews HH, Long BH: Endoscopy assisted percutaneous anterior interbody fusion with subcutaneous suprafascial internal fixation: evolution, techniques and surgical considerations. Orthop Int Ed 1995; 3: 496-500.



TRANSLAMINAR FACET SCREW FIXATION

Kamil Cagri Kose MD, Isador H Lieberman MD

1. Introduction:

Although the new era in spine surgery is highly focused on preserving mobility, fusion is still an accepted way of treatment for a variety of spinal disorders. To stabilize the spine until a fusion consolidates, spine surgeons have used combinations of hooks, wires and pedicle screws. The main problem with these implants is the need for an extensive soft tissue dissection which potentially contributes to increased number of and more significant complications. To implant pedicle screws in a safe and anatomically correct position, the proximal facet joint of the segment to be fused needs to be exposed and may well be damaged by the screw. In addition, pedicle screw constructs are expensive and the screws and rods form a bulky hardware mass in the back of the patients, which may be disturbing and lead to implant removal which means another operation.

The use of translaminar facet screws may eliminate many of these issues. Contrary to popular belief facet screw fixation is not new. King described his method of transfacet fixation as early as 1948⁽¹⁾. This technique was modified by Boucher in 1959⁽²⁾. Both techniques were transfacet but not translaminar. Magerl in 1984 revised a new transfacet screw fixation technique which was also truly translaminar⁽³⁾. He used the contralateral side of the spinous process as the starting point of drilling for this procedure. The use of this implantation trajectory increases screw length and the potential stability of the fixation. In addition to decreased operative costs, the application of this technique required a limited soft tissue dissection only to the outer side of the facet

joint and required only exposure of the facet joint of the involved level. The implants are not bulky and are less likely to disturb the patients. The earlier applications were performed by using 4.5 mm regular cortical bone screws but today special sets are designed for this technique.

With the advent of less invasive surgical techniques and increased imaging and guidance capabilities translaminar screws can be employed in a much less invasive fashion through small stab wounds⁽⁴⁾.

2. Indications:

- a) Degenerative conditions with a stable anterior column (degenerative listhesis, stenosis, segmental instability).
- b) Posterior stabilization after interbody reconstruction.
- c) To provide additional contralateral fixation in thoracolumbar fractures treated with unilateral posterior instrumentation⁽⁵⁾.

3. Contraindications:

The contraindications of the translaminar facet screw fixation are:

- a. Isthmic spondylolysis or listhesis greater than grade 1.
- b. Deficient posterior elements (lamina and spinous process)
- c. Anterior column deficiency
- d. Severe osteoporosis

4. Surgical Procedures:

4.a. Surgical Equipment:

Although there are specifically designed sets ((Universal Cannulated Screw Set [UCSS]; Sofamor-Danek) or The Discovery Translaminar Facet Screw Set (DePuy AcroMed, Raynham, MA)), this procedure was originally performed and still can be with standard 4.5 mm cortical bone screws.

4b. Patient Positioning:

The patient position is prone on a typical spinal surgery frame to facilitate the exposure and any use of guidance or fluoroscopy. The preparation and draping is completed with the surgeon's typical preference. Intra-operative fluoroscopy or plain radiographs are used to identify the level of concern and may also be used throughout the operation to judge positioning of the implants (Figure 1).

4.c. Surgical Technique:

The technique utilizes a basic less invasive exposure approach. Although the application of translaminar screws may be accomplished with fluoroscopically guided less invasive applications, for the first few cases, we recommend some experience with an open approach to gain familiarity with the anatomy and with the "feel".

Through a small vertical midline incision, the spinous processes, laminae and the facet joints are exposed in a standard fashion. If decompression is needed, care should be taken to preserve the lamina arch and 50% of the facet joints. Consideration may even be given to first implanting the screws then proceeding with the decompression. Once exposed, the facet capsule is opened and the joint surfaces are denuded of their cartilage. Bone graft of the surgeons's choice is then packed into the facet joint.

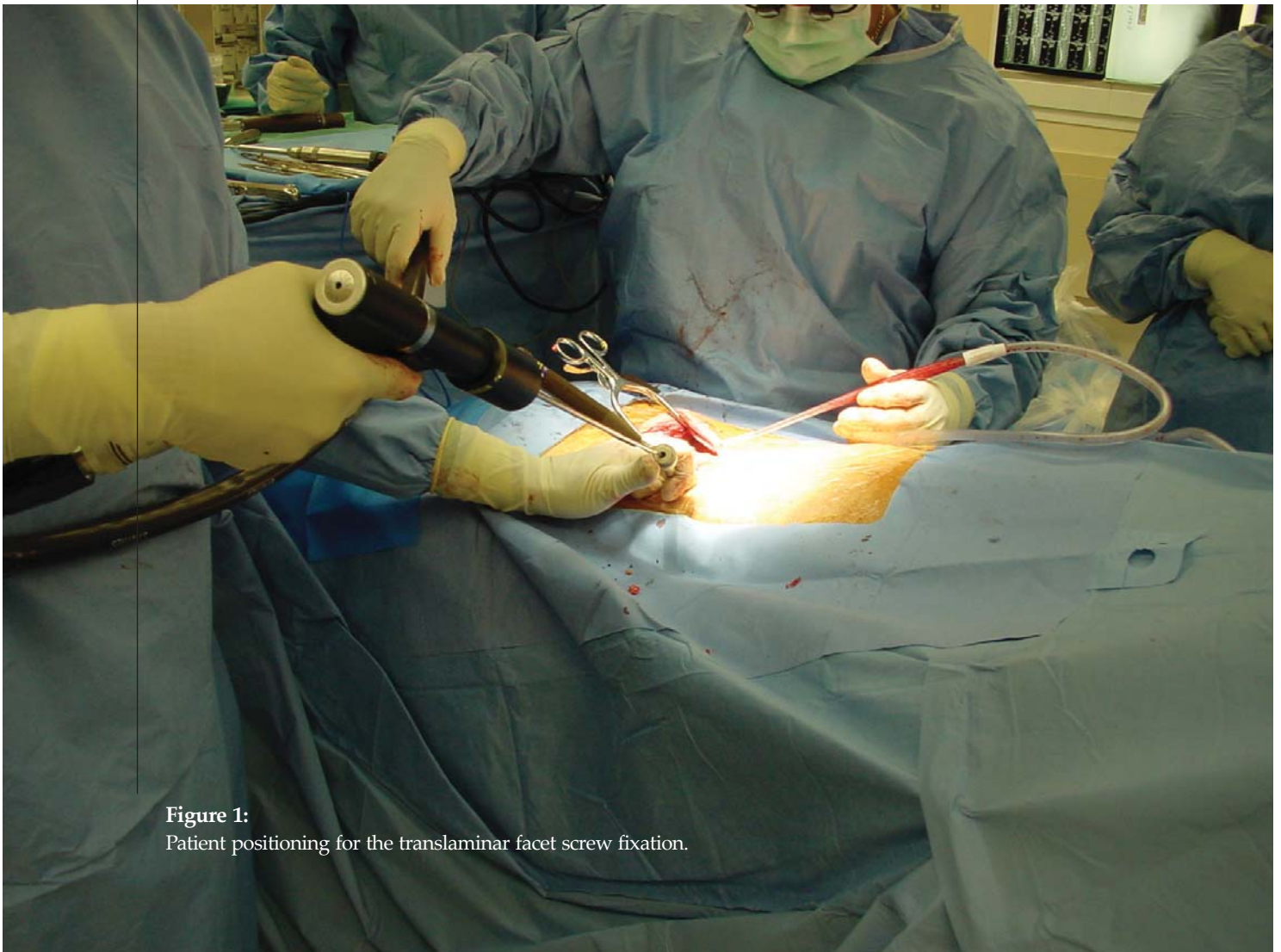

Figure 1:
Patient positioning for the translaminar facet screw fixation.

A 3.2 mm drill bit is used to drill the base of the spinous process towards the facet joint. This drilling can be done through the incision or through a second stab opening. It should be remembered that in order to place 2 screws through one spinous process, without the screws hitting each other, one screw should be placed a bit more caudal and the other a bit more cranial. If the trajectory of the lamina is followed the risk of penetrating the epidural space is minimal and the risk of injuring the dura or neural structures is negligible. After drilling with the 3.2mm drill bit a 4.5mm tap is used to tap the hole and then the length of the hole should be measured with a depth gauge. Finally an appropriate length 4.5 mm screw is placed across the facet joint through the hole in the lamina (Figure 2a, b, c). The translaminar screw is not meant to be a lag screw; it is a stabilization neutralization screw. As such compressing the facet joint will only result in either facet fracture or spinous process fracture.

Anterior vertebra corpus support or instrumentation is necessary for most of the cases additional to the translaminar facet screw fixation. Anterior femur bone graft insertion via anterior abdominal approach into the disc space increase the stabilization of the vertebrae. The anterior bone graft may stabilize with an additional screw into the inferior or posterior vertebra corpus (Figure 3a, b, c) (Figure 4a, b, c, d).

5. Postoperative Care:

There is no need for a special postoperative care. The patient is generally discharged in 1-2 days. A neoprin lumbar corset can be used to provide immobilization for 4-6 weeks. Return to work is generally dependent on the patient motivation and job specifications.

6. Complications and Avoidance:

Although translaminar facet screw fixation is a relatively simple fixation technique, as with all surgical procedures, it is not free of complications. The potential complications include:

- Foraminal violation and nerve root irritation by the drills or tools if the trajectory is not ideal or by screw malposition. In this case, if the imaging studies show impingement of the nerve root,

the screw should be removed and replaced (either using an open or percutaneous approach)

- Inadequate decompression:

The spine surgeon should never sacrifice a good decompression in order to preserve bone for fixation. If too much bone is resected other methods of spinal fixation should be employed.

Regardless of the type of complications the patient should be informed prior to the procedure about

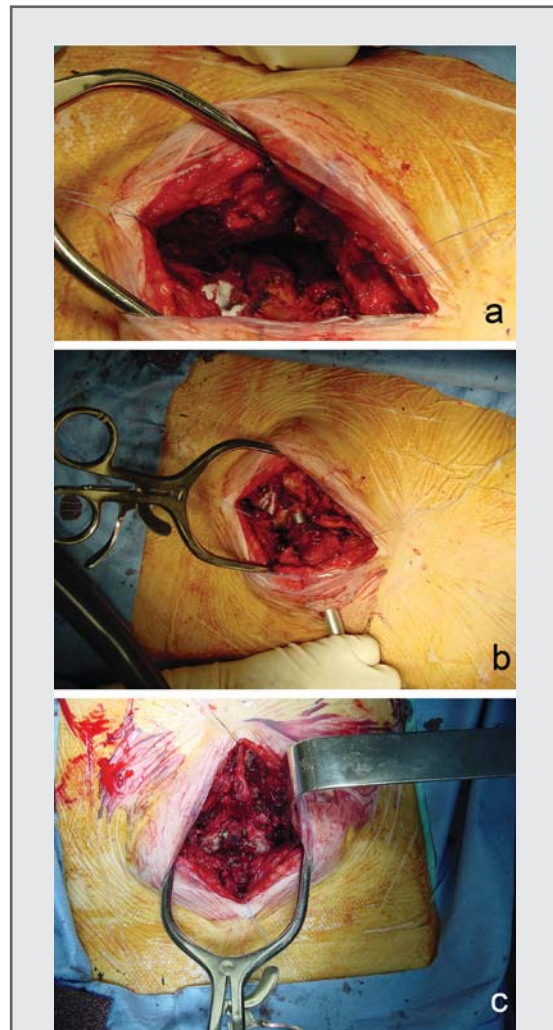


Figure 2:

Intraoperative views showing: **a)** exposure of the laminae and posterior structures of the vertebrae **b)** placement of the working cannula through the lamina. **c)** final position of the bilateral translaminar screws.

the possibility of converting to transpedicular instrumentation. If the surgeon feels uncomfortable while redirecting a malpositioned screw, or is concerned about doing an inadequate decompression, conversion to transpedicular instrumentation is the appropriate alternative

7. Clinical Studies:

There are increasing reports about the clinical and biomechanical outcomes of translaminar facet screw fixation.

Below are various clinical studies about TLFS fixation and their clinical results:

Author/year	No of patients	Follow-up	Clinical result	Fusion Rate	Fusion Time	Complications
Jacobs et al 1989 ⁽⁶⁾	43	16 mo	93% improvement	91	6 mo	None neurological
Grob et al 1992 ⁽⁷⁾	72	24.4 mo	76% satisfied	94.5	-	Screw breakage-5 5 screws were not transfacet Discitis 1 Back pain 2 Dural tear 1 Wrong level 1 None neurological
Reich et al 1993 ⁽⁸⁾	61	24 mo	93.4 % excellent to good, 6.6% unsatisfied	98.4	5 mo	None neurological
Grob et al 1998 ⁽⁹⁾	173	68 mo	99 good, 70 satisfactory, 4 bad	94	-	3%loosening, Screw breakage 2 Discitis 1 Dural tear 1 Temporary quadriceps weakness 1 Wrong level 1 Nerve root irritation 1
Thalgott et al 2000 ⁽¹⁰⁾	46	24 mo	75.5% good, excellent or total pain relief	93.2		None neurological
Yin et al 2004 ⁽⁵⁾	30	10 mo	97% anterior, 98% posterior edge restoration	100%	4.3 mo	%3.4 correction loss
Best et al 2006 ⁽¹¹⁾	43	>24 mo	-	95.3%	-	4.7% reoperation
Jang et al 2003 ⁽¹²⁾	18	6 mo	100% excellent or good	-	-	No malpositions and no other complications
Shim et al 2005 ⁽¹³⁾	20	19.5 mo	80%good to excellent 20%fair to poor	100%		10.8% lamina violation, 15.4% minimal screw, malposition Articular process fracture in 1 level

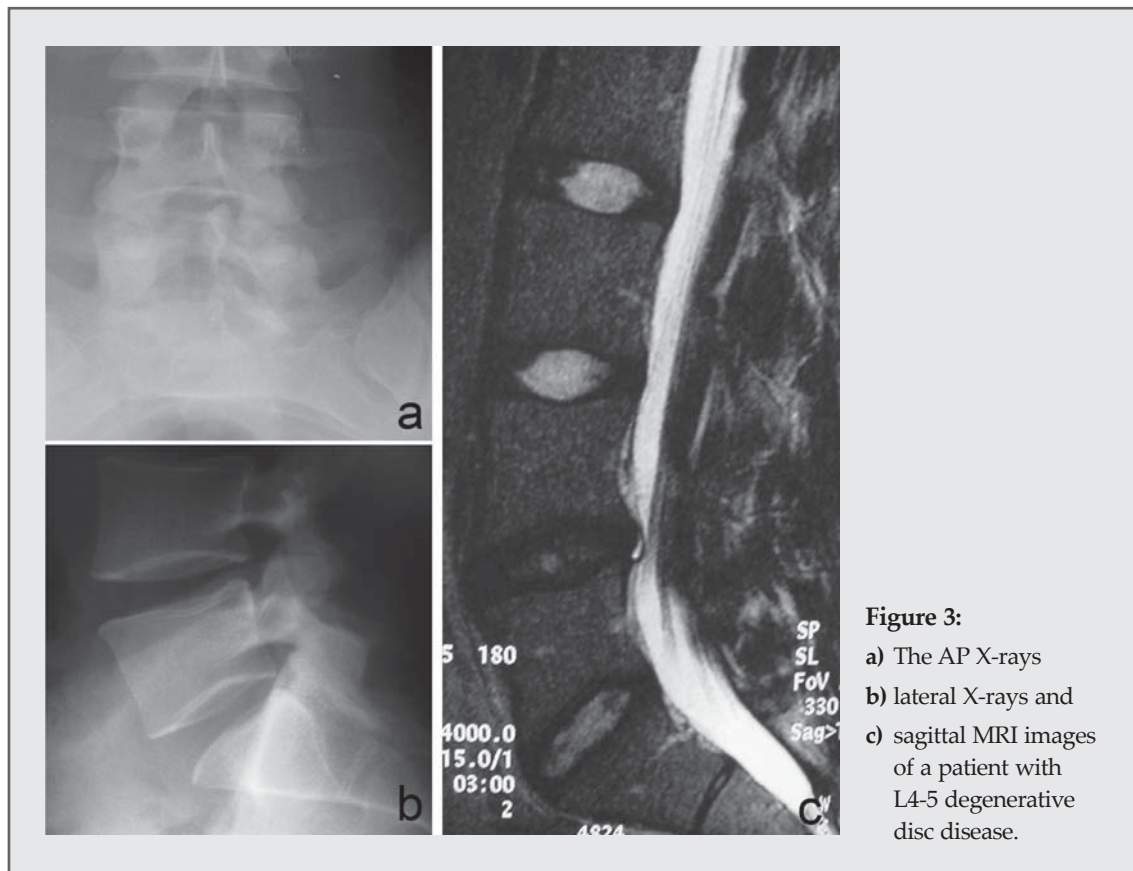


Figure 3:
 a) The AP X-rays
 b) lateral X-rays and
 c) sagittal MRI images
 of a patient with
 L4-5 degenerative
 disc disease.

It can be seen from the table that translamina facet screw fixation has proven to be a safe method of posterior stabilization with high rates of fusion.

8. Future Perspectives:

Following the minimally invasive trend in the whole world, spine surgeons also have gained interest into these methods. As new types of minimally invasive procedures evolve, surgeons face new complications. Decreasing invasiveness of these procedures can only be accomplished by increasing the safety and accuracy of these techniques.

Three dimensional fluoroscopy navigation systems have been used for these purposes. These still rely on the interpretation of the digital data by a machine and application of the procedure by the surgeon. There still exists a way for a mistake as final mechanical application is made by the surgeon.

In order to decrease the error at the mechanical phase of these surgeries robotic guidance systems which direct the surgeon to a further step in the op-

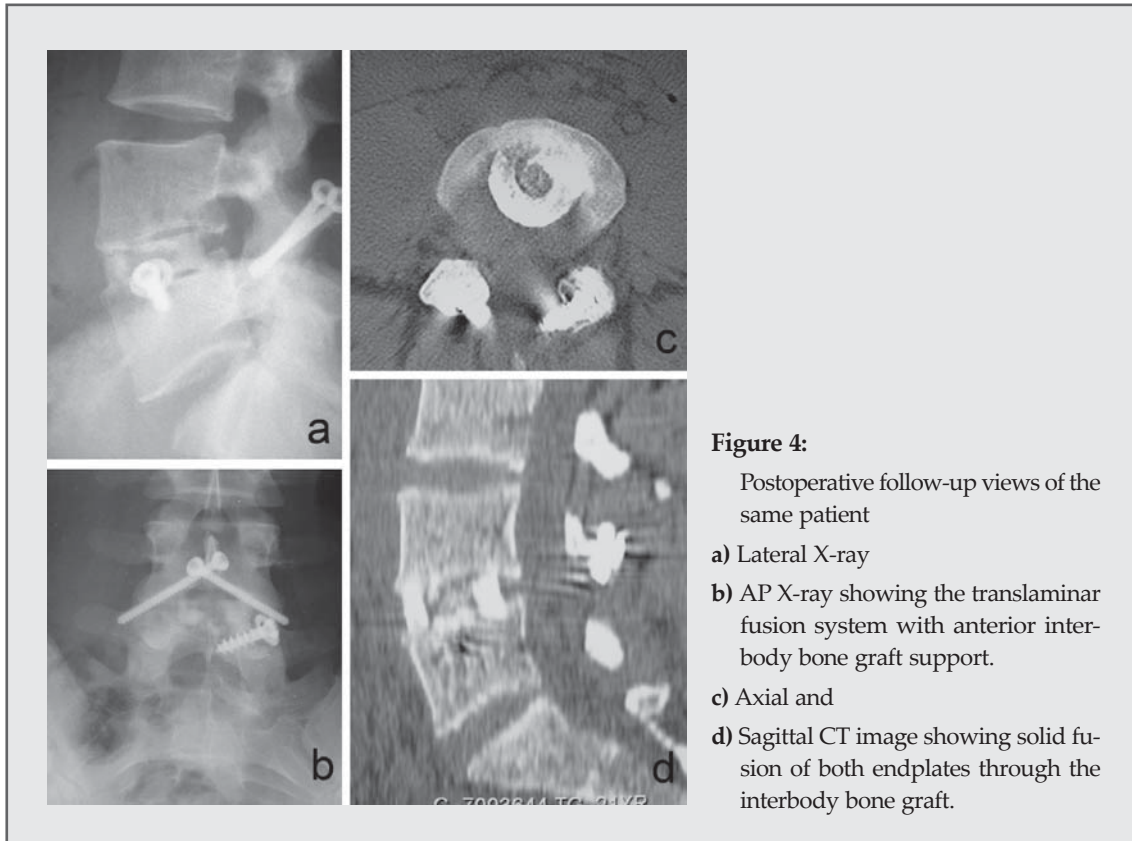
eration are being developed. So far the test results are promising and demonstrate a safe method of inserting pedicle screws and translamina facet screws.

In the near future we believe that the robotic guidance systems will be available in our daily practice to increase the safety and accuracy of these surgeries ⁽¹⁴⁻¹⁶⁾.

9. References:

1. King D. Internal fixation for lumbosacral fusion. *J Bone Joint Surg Am* 1948; 30: 560-5.
2. Boucher HH. A method of spinal fusion. *J Bone Joint Surg Br* 1959; 41: 248-59.
3. Magerl FP. Stabilization of the lower thoracic and lumbar spine with external skeletal fixation. *Clin Orthop* 1984; 189: 125-41.
4. Shim CS, Lee SH, Jung B, Sivasabaathi P, Park SH, Shin SW. Fluoroscopically assisted percutaneous translamina facet screw fixation following anterior lumbar interbody fusion: technical report. *Spine* 2005; 30(7): 838-43.
5. Yin QD, Zheng ZG, Cai JP. Pedicle screw fixation with translamina facet joint screws for the treat-

- ment of thoracolumbar fracture. *Chin J Traumatol* 2004; 7(6): 354-7.
6. Jacobs RR, Montesano PX, Jackson RP. Enhancement of lumbar spine fusion by use of translaminar facet joint screws. *Spine* 1989; 14:12-5
 7. Grob D, Rubeli, Scheier HJ, Dvorak J. Translaminar screw fixation of the lumbar spine. *Int Orthop* 1992; 16: 223-6.
 8. Reich SM, Kuflik P, Neuwirth M. Translaminar facet screw fixation in lumbar spine fusion. *Spine* 1993; 18: 444-9.
 9. Grob D, Humke T. Translaminar screw fixation in the lumbar spine: technique, indications and results. *Eur Spine J* 1998; 7: 178-86.
 10. Thalgott JS, Chin AK, Ameriks JA, Jordan FT, Giuffre JM, Fritts K, Timlin M. Minimally invasive 360 degrees instrumented lumbar fusion. *Eur Spine J* 2000; 9 (Suppl 1): S51-6.
 11. Best NM, Sasso RC. Efficacy of translaminar facet screw fixation in circumferential interbody fusions as compared to pedicle screw fixation. *J Spinal Disord Tech* 2006; 19(2): 98-103.
 12. Jang JS, Lee SH, Lim SR. Guide device for percutaneous placement of translaminar facet screws after anterior lumbar interbody fusion: Technical note. *J Neurosurg* 2003; 98(1 Suppl): 100-3.
 13. Shim CS, Lee SH, Jung B, Sivasabaapathi P, Park SH, Shin SW. Fluoroscopically assisted percutaneous translaminar facet screw fixation following anterior lumbar interbody fusion: technical report. *Spine* 2005; 30(7): 838-43.
 14. Lieberman IH, Togawa D, Kayanja MM, Reinhardt MK, Friedlander A, Knoller N, Benzel E: Bone-Mounted Miniature Robotic Guidance For Pedicle Screw and Translaminar Facet Screw Placement; Part I - Technical Development and a Test Case Result. *Neurosurg* 2006; 59 (3): 641-650.
 15. Togawa D, Lieberman IH, Kayanja MM, Reinhardt MK, Friedlander A, Knoller N, Shoham M, Balter A, Benzel E: Bone-Mounted Miniature Robotic Guidance For Pedicle Screw and Translaminar Facet Screw Placement; Part II – Evaluation of System's Accuracy. *Neurosurg* 2007; 60 (2 Suppl 1): 129-39.
 16. Shoham M, Lieberman IH, Benzel EC, Togawa D, Zehavi E, Zilberstein B, Roffman M, Bruskin A, Friedlander A, Joskowicz L, Brink-Danan S, Knoller N. Robotic assisted spinal surgery—from concept to clinical practice. *Comput Aided Surg* 2007; 12(2): 105-15.



58

PERCUTANEOUS TRANSPEDICULAR FIXATION AND TLIF (ABBOTT SPINE)

Farbod Asgarzadie MD, Larry T Khoo MD

5 ANTERIOR MICROENDOSCOPIC DISCECTOMY AND FUSION

A Fahir Ozer MD, Senol Carilli MD

1. Introduction:

Anterior microendoscopic discectomy was appeared in literature in 1991 by Obenchain ⁽¹⁾. It was accomplished in an outpatient setting with minimal use of oral narcotics. Anterior endoscopic fusion was published by Onimus *et al.* in 1995 ⁽²⁾. A small vertical incision made on the umbilicus and extraperitoneal way is used to approach L4-5 and L5-S1 level. Percutaneous anterior endoscopic discectomy was published as a case series by Cloyd DW *et al.* and Zelko JR *et al.* in 1995 ^(3,4). Transperitoneal route were used in these to separate series.

Mathews HH *et al.* accomplished fusion with endoscopic approach using transperitoneal route in 1995 ⁽⁵⁾. With endoscopic approach both retroperitoneal and transperitoneal routes were successfully used in discectomy and fusion cases. After these, Mayer HM was described mini ALIF technique in 1997 ⁽⁶⁾. This operation technique started a question about "which one of them is superior?" Regan *et al.* published a prospective multicenter study in 1999. They claimed that the laparoscopic procedure is associated with a learning curve, but once mastered it is effective and safe when compared with open techniques of fusion ⁽⁷⁾.

At that time, BAK cages was very popular in the treatment of painful discs ^(8,9) and the same authors who advocate superiority of laparoscopic approach published successful results ⁽¹⁰⁾. Zdeblick TA and Davis SM was published an article about fusion of L4-5 level. They used both techniques and prospective comparison of 50 conservative patients who underwent L4-5 anterior lumbar interbody fusion (ALIF) and they concluded that there does not appear to be a significant advantage at the L4-5 level of the transperitoneal lap-

aroscopic surgical approach when compared with an open mini ALIF retroperitoneal technique ⁽¹¹⁾.

Kaiser MG *et al.* reported a retrospective review in 98 patients who underwent ALIF procedures in which either a mini open or a laparoscopic approach was used. They concluded that the mini open approach possesses a number of theoretical advantages; however the individual surgeon preference ultimately is likely to be the dictating factor ⁽¹²⁾. One year later a comparative study was published by Chong SK *et al.* ⁽¹³⁾. In this study 54 consecutive patients underwent surgery using with both technique for L5-S1 level. They reported that the laparoscopic approach for L5-S1 showed similar clinical and radiological outcome when compared with open mini ALIF, but significant advantages were not identified despite its technical difficulty.

In our experience, we used both techniques equally in our clinical practice, however we did not detected any differences of outcome. In endoscopic surgery, learning curve is longer than mini ALIF.

2. Patient Selection:

Painful disc disease, grade I spondilolisthesis, and lumbar disc prosthesis are the main indications of anterior microendoscopic discectomy and fusion. Additionally, if the anterior part of L5-S1 disc level is decided to join the fusion, these approaches can be used.

Previous abdominal surgery is the main contraindication of the endoscopic surgery because of the possible adhesions. Additionally, the general contraindications of routine anterior approaches must be evaluated before anterior microendoscopic discectomy and fusion.

3. Surgical Procedures:

3.a. Surgical Equipment:

Scopy is necessary to detect the lumbar disc levels and anterior and posterior parts of the vertebrae to avoid from the neural and vascular injuries. Laparoscopic devices for anterior microendoscopic approach are seen in (Figure 1).

3b. Operating Room Set-up:

Patient is positioned 30 degrees trandelenburg in supine position. Although the main surgeon can be positioned between the legs of the patient, we prefer the right side of the patient for right handed surgeons. The assistant is positioned just opposite and the scrub is positioned at the right side of the surgeon. Monitor is on the other side beyond the shoulder of the patient. The scopy is localized at the foot and anesthesia is localized at the head of the patient (Figure 2).

3.c. Patient Positioning:

As we mentioned above, the patient is in supine position with open legs (surgeon between the legs) or

closed legs. A pillow under the lumbar spine or bending the operating table will help to raise the promontorium during surgery (Figure 3a, b).

3.d. Surgical Technique:

3.d.1. Laparoscopic Discectomy:

20After the insertion of the first trocar with open technique pneumoperitoneum is accomplished then other two trocars are inserted. Sigmoid colon is pushed to patient's left and small intestines are right upward from the mesentery to reach the peritoneum on the vertebral colon. Peritoneum is cut by a scissors in vertical axis while it is hanged by a grasper to prevent an injury of underlying vessels. After sweeping off the retroperitoneal fat and coagulating and cutting the median sacral vessels lying on the anterior surface of the vertebra L5-S1 level, the patient is ready for lumbar discectomy. Mobilization of the great vessels is essential for the surgeries on upper levels dissections.

Anterior discectomy is performed after cutting the anterior longitudinal ligament (ALL) (Figure 4b). During this process, the herniated disc materials located between the teared parts of posterior annulus fibrosus must be cleared. Additionally, posterior and anterior osteofites are removed via kerison rongeurs to allow the localization of bone grafts into the disc space. The bone graft is placed on the prepared disc level and hammered into the disc space (Figure 4c). Hemosthesis is performed after completing the discectomy (Figure 4d).

Posterior peritoneal defect is closed with continuous 3/0 mono filament suture. After removal of the trocars holes below the umbilicus level larger than 10 mms are required facial closure.

3.d.2. Mini ALIF:

Mini ALIF approach is another minimally invasive technique for anterior approaches of lumbar spine. We mostly use open window laparotomy technique which is a modification of mini ALIF approach⁽¹⁴⁾. Detailed explanation of the open window laparotomy technique which helps to reduce the risks of anterior approach is given in the chapter 5L of this book.

After reaching to the anterior part of lumbar spine via open window laparotomy technique, the disc level is confirmed under scopy. Microsurgical



Figure 1: Surgical equipment

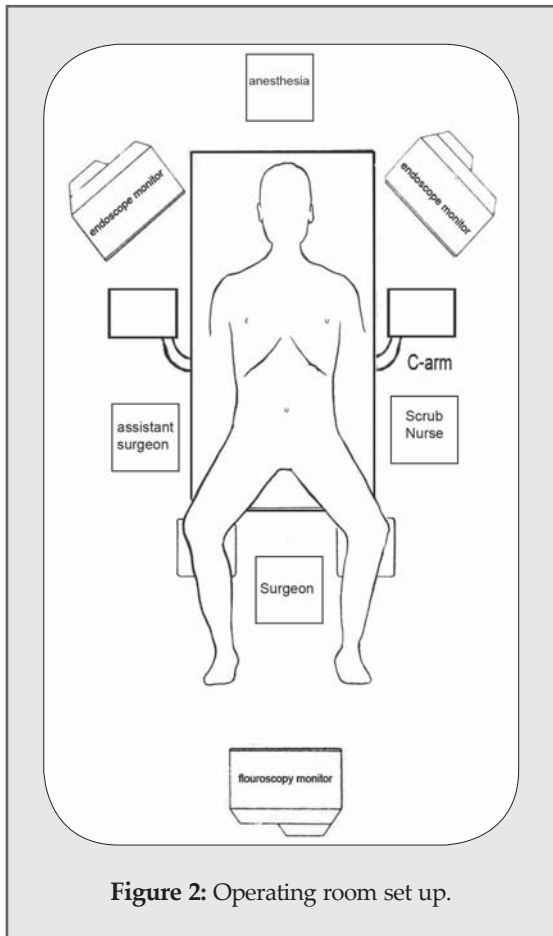


Figure 2: Operating room set up.

discectomy is performed after cutting the ALL under microscope. The lower and upper cartilage endplates of the disc level is curetted and posterior osteofites are removed. After preparing the disc level, the prepared bone graft is hammered into the disc space. Because of the high pseudoarthrosis risk of stand alone bone grafts, the system may be supported with posterior percutaneous transpedicular minimally invasive systems.

The fusion may be achieved with BAK cages. However, the height of the BAK cages must be longer than the height of disk level. So, the anatomical structure of cartilage endplates is destroyed and the spongy bone of the vertebra corpus and bone graft inside the cage meet each other for fusion (Figure 5a-e).

If the surgeon decides to perform disc prosthesis inside the discectomy level, the disc level is prepared with appropriate tools and lumbar disc prosthesis is inserted.

3.d.3. Conclusion:

Both these techniques are still used today. Our experience and reviewing the literature we can not say that one technique is superior against the other. Surgical skill, learning curve and surgeons decisions are determined which surgical technique is preferred.

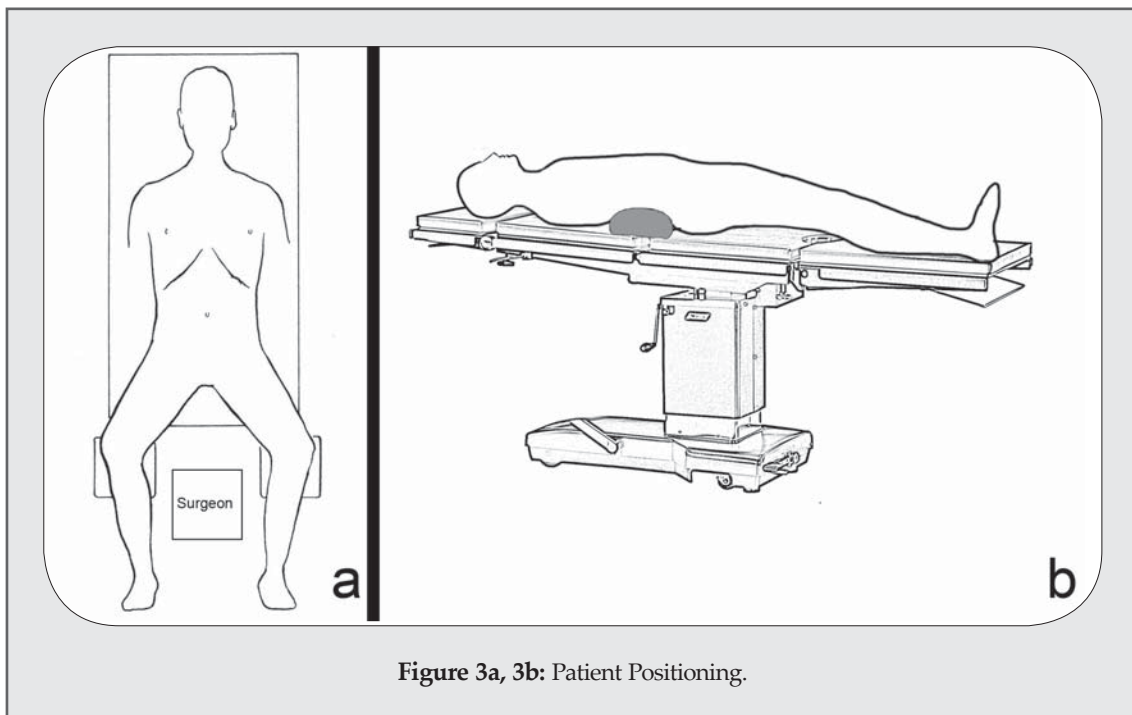
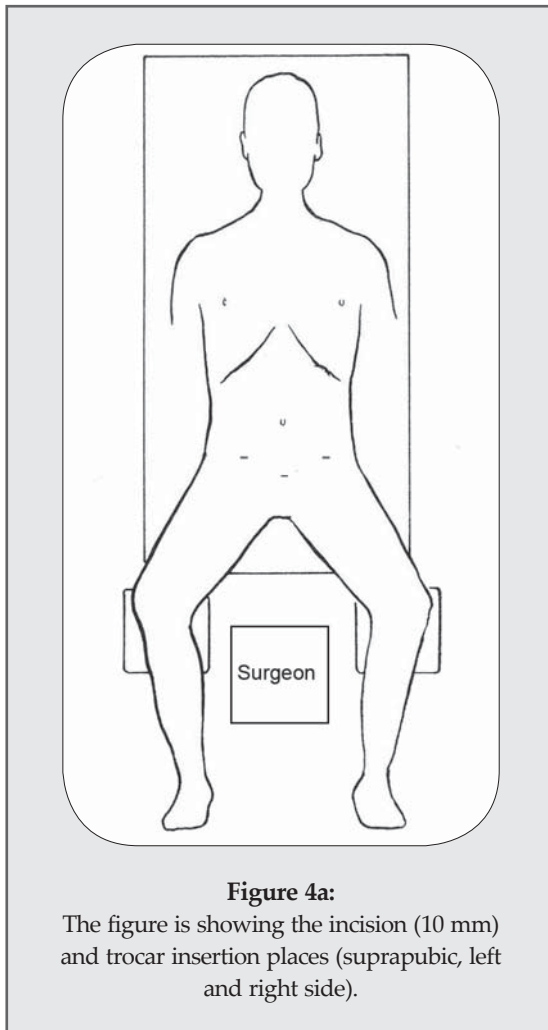


Figure 3a, 3b: Patient Positioning.

**Figure 4a:**

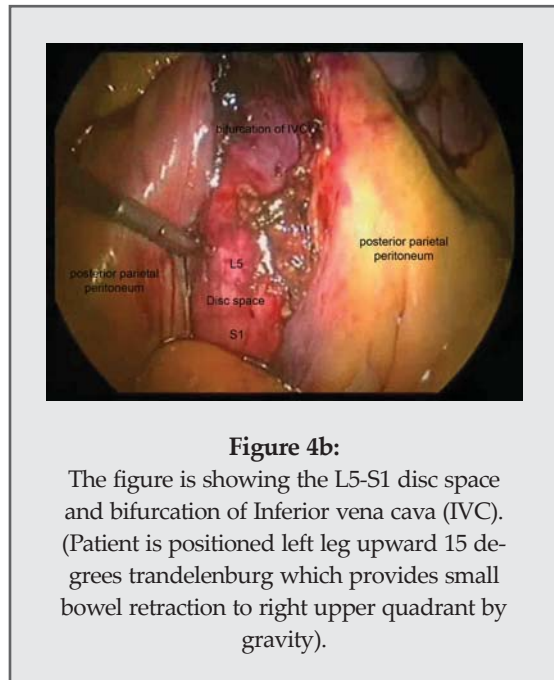
The figure is showing the incision (10 mm) and trocar insertion places (suprapubic, left and right side).

4. Postoperative Care:

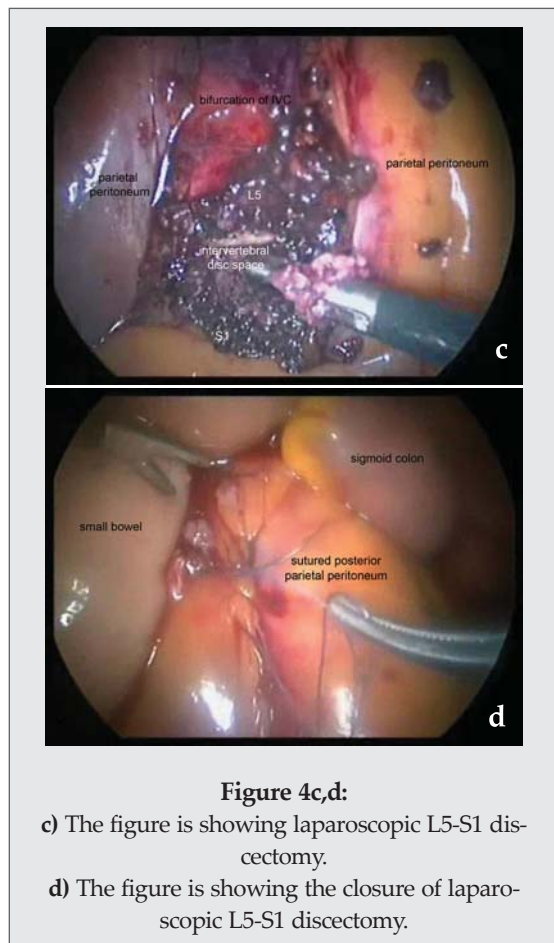
The patient is taken to the recovery room after the anesthesia period. The feeding of the patient can be started after the sounds of intestinal movements. The appropriate analgesics and anti-inflammatory drugs can be inserted if the patient needs. The patient is stood up and walked the day after surgery and discharged 3 days after the operation. The patient can return his job 2 weeks after operation.

5. Complications and avoidance:

Great vessel injury, sympathetic chain injury and perforations of intestines and other abdominal organs are the main complications of anterior microendoscopic approaches. The extending learning curve and experienced hands will decrease these complications.

**Figure 4b:**

The figure is showing the L5-S1 disc space and bifurcation of Inferior vena cava (IVC). (Patient is positioned left leg upward 15 degrees trandelenburg which provides small bowel retraction to right upper quadrant by gravity).

**Figure 4c,d:**

c) The figure is showing laparoscopic L5-S1 discectomy.

d) The figure is showing the closure of laparoscopic L5-S1 discectomy.

6. Case Illustrations:

Case Report:

42 years old woman was applied to our hospital complaining with severe back and right lower extremity pain. Her pain and numbness are immediately begun when she tried to walk and stand up. Her neurologic examination was normal. Direct X-ray and MRI showed degenerative disc disease at the L5-S1 disc space (Figure 5a,b). Anterior microendoscopic discectomy was performed and BAK cages inserted to the L5-S1 disc space with laparoscopic approach (Figure 5b,c,d). Post operative course of the patient was uneventful and discharged at the 3 rd day after operation.

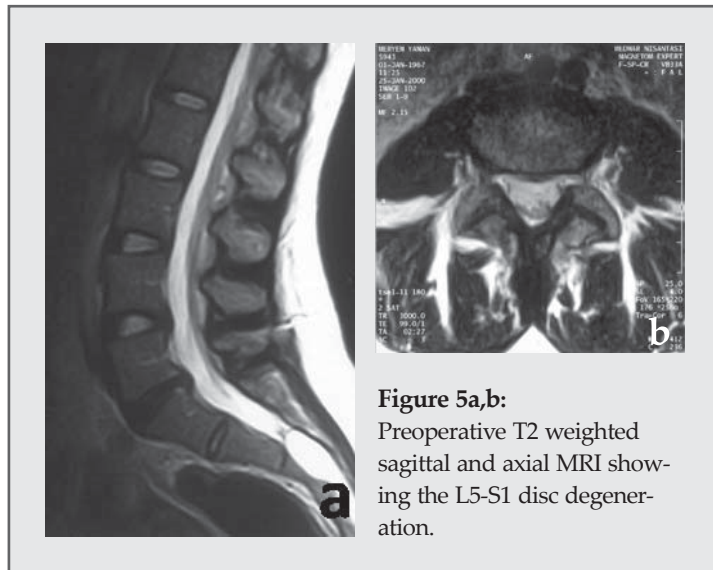


Figure 5a,b:
Preoperative T2 weighted sagittal and axial MRI showing the L5-S1 disc degeneration.

7. References:

1. Obenchain TG. Laparoscopic lumbar discectomy: Case report. *J Laparoendosc Surg* 1991; 1(3):145-9.
2. Onimus M, Papin P, Gangloff S, Baliqne JG. Video-assisted anterior extra-peritoneal approach of the inferior lumbar spine [Article in French]. *Rev Chir Orthop Reparatrice Appar Mot* 1995; 81(3): 257-63.
3. Cloyd DW, Obenchain TG, Savin M. Transperitoneal laparoscopic approach to lumbar discectomy. *Surg Laparosc Endosc* 5(2):85-9, 1995.
4. Zelko JR, Misko J, Swanstrom L, Pennings J, Kenyon T. Laparoscopic lumbar discectomy. *Am J Surg* 1995; 169(5): 496-8.
5. Mathews HH, Evans MT, Molligan HJ, Long BH. Laparoscopic discectomy with anterior lumbar interbody fusion. A preliminary review. *Spine* 1995; 20(16):1797-802.
6. Mayer HM. A new microsurgical technique for minimally invasive anterior lumbar interbody fusion. *Spine* 1997; 22(6): 691-9.
7. Regan JJ, Yuan H, McAfee PC. Laparoscopic fusion of the lumbar spine: minimally invasive spine surgery. A prospective multicenter study evaluating open and laparoscopic lumbar fusion. *Spine* 24(4): 402-11, 1999.
8. Ray CD. Threaded titanium cages for lumbar interbody fusions. *Spine* 22: 667-79, 1997.
9. Kuslich SD, Ulstrom CL, Griffith SL, Ahern JW, Dowdle JD. The Bagby and Kuslich method of lumbar interbody fusion. History, techniques, and 2-year follow-up results of a United States prospective, multicenter trial. *Spine* 1998; 23(11): 1267-78.
10. Regan JJ, Aronoff RJ, Ohnmeiss DD, Sengupta DK. Laparoscopic approach to L4-L5 for interbody fusion using BAK cages: experience in the first 58 cases. *Spine* 1999; 24(20): 2171-4.

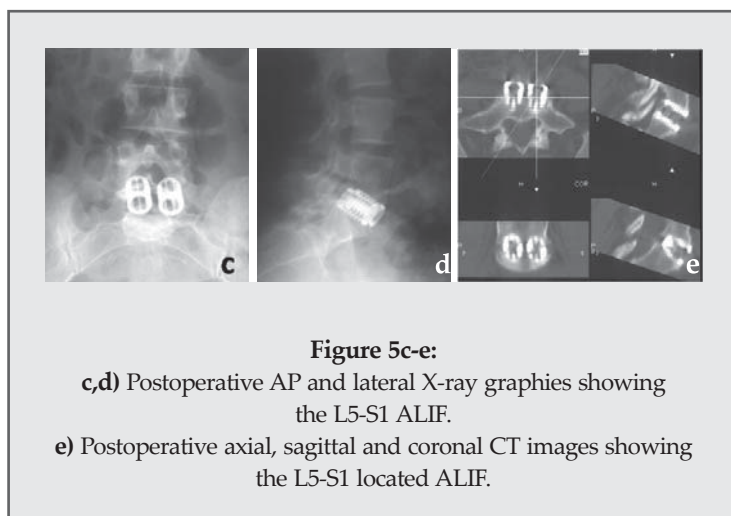


Figure 5c-e:
c,d) Postoperative AP and lateral X-ray graphies showing the L5-S1 ALIF.
e) Postoperative axial, sagittal and coronal CT images showing the L5-S1 located ALIF.

11. Zdeblick TA, David SM. A prospective comparison of surgical approach for anterior L4-L5 fusion: Laparoscopic versus mini anterior lumbar interbody fusion. *Spine* 2000; 25(20): 2682-7.
12. Kaiser MG, Haid RW Jr, Subach BR, Miller JS, Smith CD, Rodts GE Jr. Comparison of the mini-open versus laparoscopic approach for anterior lumbar interbody fusion: a retrospective review. *Neurosurgery* 2002; 51(1): 97-105.
13. Chung SK, Lee SH, Lim SR, Kim DY, Jang JS, Nam KS, Lee HY. Comparative study of laparoscopic L5-S1 fusion versus open mini-ALIF, with a minimum 2-year follow-up. *Eur Spine J* 2003; 12: 613-617.
14. Carilli S, Oktenoglu T, Ozer AF. Open-Window Laparotomy during a Transperitoneal Approach to the Lower Lumbar Vertebrae: New Method for Reducing Complications. *Minim Invasive Neurosurg* 2006; 49: 227-229.



MINIMALLY-INVASIVE LUMBOSACRAL AXIAL INSTRUMENTATION TECHNIQUE

Murat Cosar MD, Larry T Khoo MD

1. Introduction:

Lumbar fusion is a frequently used technique to treat spinal disorders including symptomatic instability due to traumatic and iatrogenic causes, stenosis, spondylolisthesis and scoliosis ⁽¹⁾. Traditional anterior or posterior approaches are chosen for direct exposure of the lumbosacral spine. These kind of traditional approaches are often poorly tolerated by patients, because they require significant muscle dissection and retraction, ligamentous disruption, osseous stripping, neural retraction, annular disruption, sympathetic dysfunction and bowel injury and sometimes with the additional risk of vascular injury in a anterior approaches ^(2,3). Additionally, traditional anterior spinal approaches place the abdominal viscera, ureters, retroperitoneal structures, sympathetic plexi, and great vessels at risk. However, the advent of minimally invasive spinal surgical techniques made the surgeons to perform interbody fusion and screw placement with less pain, damage of muscles, blood loss, postoperative length of stay, and medications than open surgery ^(1,2,4,5).

Degenerative disease of the lumbar disc space frequently affects the anterior column of lower lumbosacral spine as normal loading of the lumbar spine directs over 80% of the axial load over the anterior column in the lower levels. As such, traditional open fusion treatment of spinal instability and back pain at the L4-5 and L5-S1 segments is extremely common ⁽³⁾. Because of the potential risks of open surgical approaches, technological advances employing small incisions and portals have allowed surgeons to perform lumbosacral fusion via posterolateral or anterior approaches through more minimally invasive

techniques ⁽⁶⁻⁹⁾. Recently, a soft tissue sparing minimally invasive approach to the axial lumbosacral spine has been developed ^(1,3,10). The AxialLif (Trans-1; Wilmington, NC; USA) system combines the advantages of minimal invasive spinal surgical techniques with a novel corridor of approach. Via a 2 cm paracoccygeal incision, a trocar is advanced along the anterior surface of the sacrum using biplanar fluoroscopy, until a proper trajectory into the center of the L5-S1 intervertebral space is obtained. This minimally invasive approach to the lumbosacral spine also preserve the integrity of the muscles, ligaments, blood vessels and disc annulus ^(1,3,10).

Through the naturally existing presacral fat pad, ready access can be gained to the disc space while avoiding the anterior abdominopelvic cavity, great vessels, neural elements, facets, lamina, and the dorsal musculoligamentous complex completely. Significant segmental stiffness is immediately afforded by distraction across the disc space. As the ligaments and annulus are completely intact, this provides the strongest possible ligamentotaxis thereby affording the best interbody fusion construct stiffness ⁽³⁾.

Additionally, there is no need for retraction of the vascular or neural elements to place the prosthesis as the size is limited only by the diameter of the working portal. As distraction is achieved by the differential screw pitch of the ends of the cage, a wide variety of distraction heights can be obtained by simply altering the design of the implant. When combined with percutaneous pedicle screw instrumentation system, additional distraction, compression, and reduction maneuvers can also be applied to the spine as needed prior to threading the cage across the interspace ⁽³⁾. Similar to trans-sacral fibular dowel struts in the

stabilization of high grade isthmic spondylolisthesis, axially placed cages such as the AxialLif trans-sacral cage provide excellent resistance to shear, translation, flexion, and extension that is far superior to traditional interbody constructs ^(3,8).

This paracoccygeal, trans-sacral approach to the L5-S1 interspace allow the surgeon to perform a near-total discectomy without violation of the annulus or surrounding ligaments thereby significantly increasing the stiffness of the motion segment with distraction. Additionally, this leaves the area around the disc, great vessels, and neural elements untouched and thus free of surgical scarring which is attractive for future cases that may require revision or adjacent level surgery ⁽³⁾.

2. Indications:

Degenerative disc disease, pseudoarthrosis, post-laminectomy instability, spondylolisthesis (grade 1 or 2), and unsuccessful previous fusion are the main indications of this transsacral approach.

3. Contraindications:

Spondylolisthesis (grade 3 and 4), pararectal infection, etc. are the main contraindications for transsacral approach.

We must be care on the thin patient and the flat sacrum. Because, thin patient has no much presacral fat so the surgeon may use monitor relationship between introducer and rectal air shadow on lateral view. Additionally, to gain the trajectory is much difficult on the flat and hooked sacrum, so manually advance may be used for these patients.

4. Surgical Procedures

4.a. Surgical Equipment

Several items of equipment are needed to perform a transsacral AxialLif fusion. First, draped C-arm fluoroscopy and monitor are essential for verifying the position and localization of the patient during surgery. Transsacral AxialLif set is necessary to perform the operation. Additionally, posterior lumbar minimal invasive surgery instruments are essential for the operation (Figure 1).




Figure 1: The AxiaLif instrumentation set

- a) Guide pin, serial dilators and etc.
- b) The cutting-loop devices and disc extractors
- c) A special wire brush type capture device
- d) The 3D-Axial Rod prosthetic device (AxiaLif cage).

4b. Operating room set up

A standard set up for posterior lumbar surgery is used with the spine surgeon standing on the left or right side of the patient with a operation technician and a surgical assistant. The C- arm and monitor is placed according to the localization of the surgeon (Figure 2a, 2b).

4.c. Patient positioning:

The patient is positioned under general anesthesia prone on a suitable radiolucent spine operative table (Figure 2c). A 20-French catheter may be inserted into the rectum and the balloon insufflated with 10-12 ml air to provide visualization of the rectum and to minimize the risk of bowel injury during the process under lateral fluoroscopy. The anus is covered with an occlusive dressing that to separate it from the paracoccygeal working area which is more dorsal. Intraoperative EMG and/or SSEP may be used for neurophysiological monitoring for surveillance of neural integrity during decompression, interbody

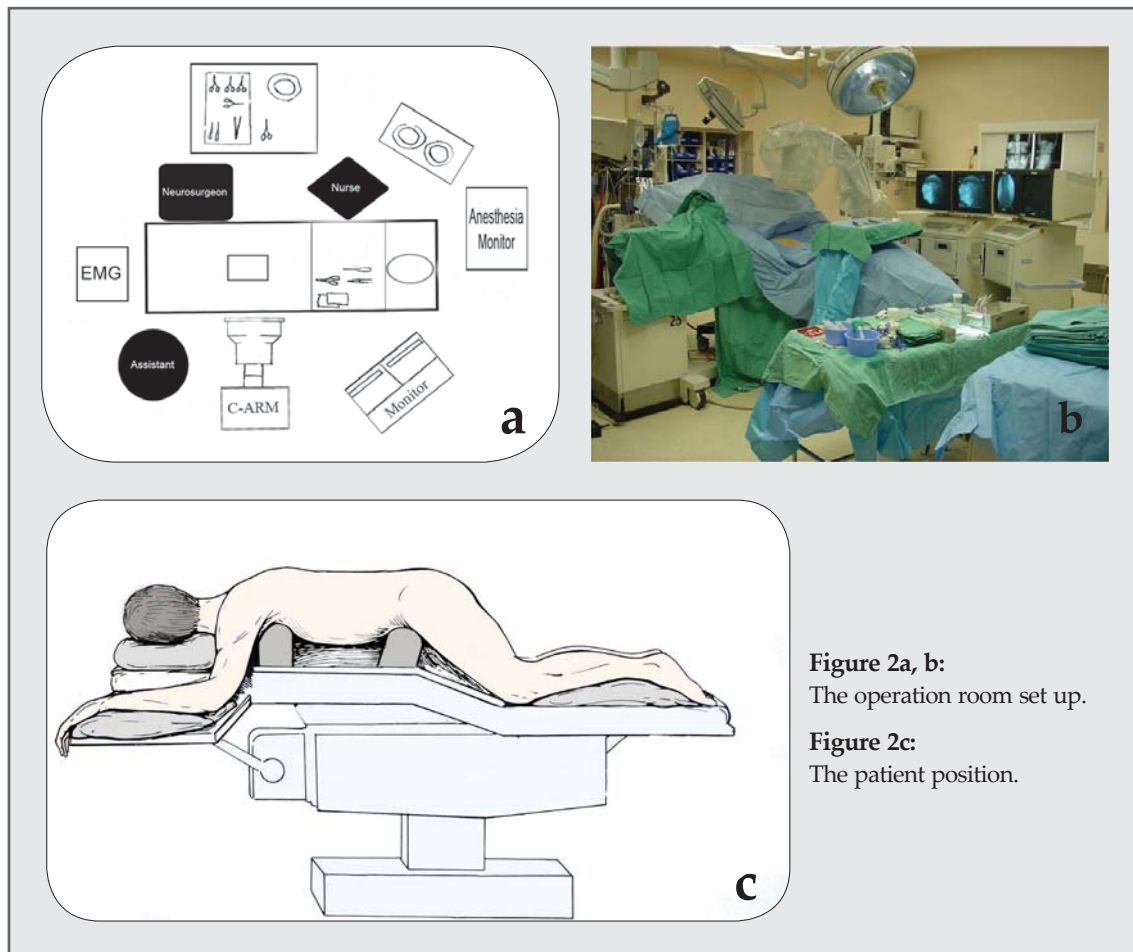


Figure 2a, b:
The operation room set up.

Figure 2c:
The patient position.

distraction, and screw placement. A fluoroscopic C-arm is located into the surgical field to provide for real-time lateral and A-P imaging. The operation area is then washed and draped in the usual sterile fashion.

4.d. Surgical Technique:

A 15-20 mm incision is performed 20 mm caudal to the left or right paracoccygeal notch after local anesthesia (Figure 3a-1, 3a-2). A finger dissection may be used to ensure that the fascia is appropriately opened. The Guide Pin Introducer/Stylet Assembly is inserted into the incision with a suitable angle and slowly advanced along the anterior midline of the sacrum. Direct tactile feedback is obtained from the stylet to control continuous bony contact of the introducer tip. The presacral fat and anterior contents are swept off away from the bony floor of the pelvis with a rhythmic little oscillating movement under

biplanar fluoroscopic control (Figure 3b-1,2,3,4). The Guide Pin Introducer is then engaged properly on the anterior cortex of the S1-S2 junction. After preliminary contact with the inferior aspect of the S1-S2 junction, a trajectory plan is made through the sacrum, L5-S1 disc space, and the L5 body under biplanar fluoroscopy, that will be the final path for placement of the AxiaLLif threaded cage. The trajectory of the stylet will pass through the middle and anterior portions of the L5-S1 intervertebral disc space while still ending in the anterior column of the L5 body. The A-P plane of the fluoroscopy must provide that the ultimate trans-discal trajectory will be near the midline and not too far off laterally in either direction. After the planning of optimal trajectory, the blunt guide introducer is exchanged for the sharp guide pin on a handle and then docked on the S1-S2 junction.

After the confirmation of trajectory, the Guide Pin is inserted through the sacrum (Figure 3c) with

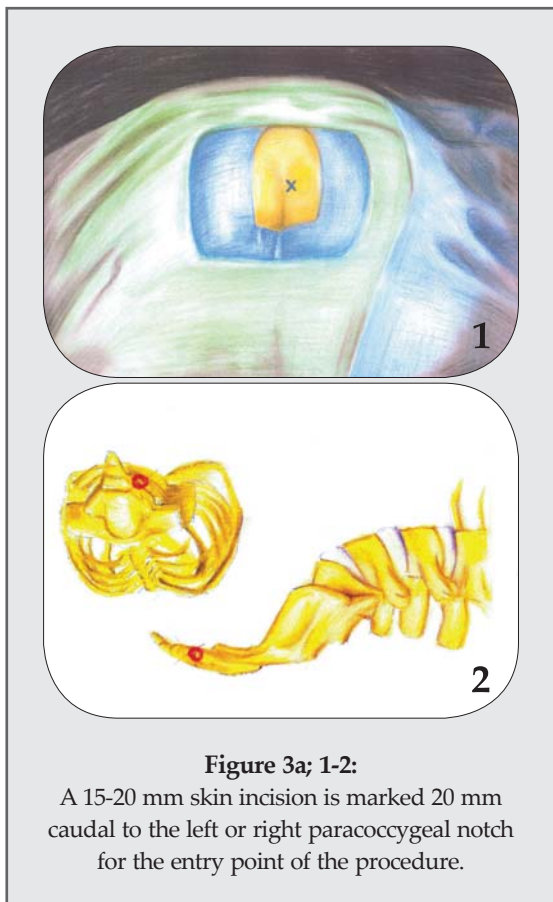


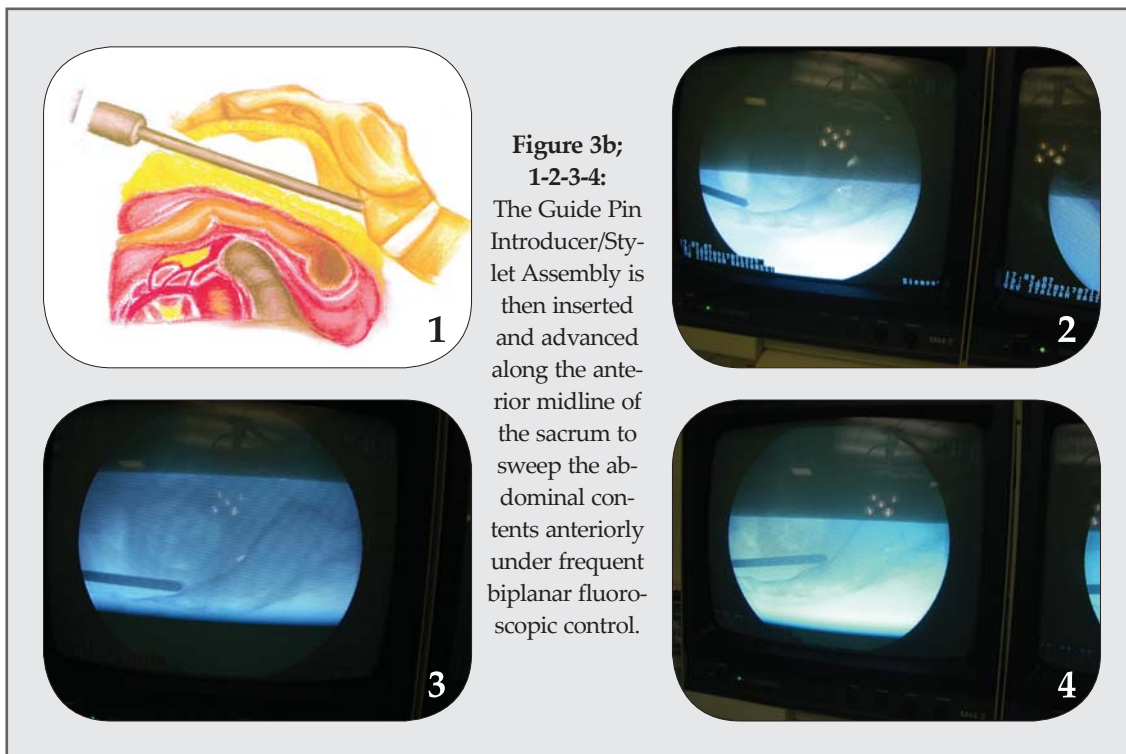
Figure 3a; 1-2:

A 15-20 mm skin incision is marked 20 mm caudal to the left or right paracoccygeal notch for the entry point of the procedure.

a cannulated slap-hammer. Serial dilators are used which will dilate the presacral soft tissue as well create the bony working channel the sacrum itself after the removing of the guide pin and handle.

At first, the bevelled 6 mm tubular dilator is slid over the Guide Pin using the Slap Hammer with the bevel facing ventrally to move the visceral contents anteriorly and away. When the dilator is contacted to the sacrum, it is rotated 180-degrees to match the bevel with the inclination of the sacrum. It is then inserted directly through the sacral surface and countersunk several mm to firmly seat it within the sacrum. The 6 mm dilator is removed and changed with a 8 mm dilator to repeat the same series of steps. A 10 mm dilator is inserted after removal of the 8 mm dilator (Figure 3d). Finally, a thin walled Dilator Sheath is inserted over the 10 mm Dilator Body to assemble the dilators. This Dilator Sheath is anchored firmly in the sacrum using the slap-hammer under biplanar fluoroscopic confirmation. All assembly is removed except dilator sheath thereby establishing the safe, secure presacral, trans-sacrum working corridor for subsequent intervertebral access, discectomy, reaming, distraction, and threaded cage placement.

A 9 mm threaded reamer is inserted down the working portal into the sacrum to create the bony



**Figure 3b;
1-2-3-4:**

The Guide Pin Introducer/Styler Assembly is then inserted and advanced along the anterior midline of the sacrum to sweep the abdominal contents anteriorly under frequent biplanar fluoroscopic control.

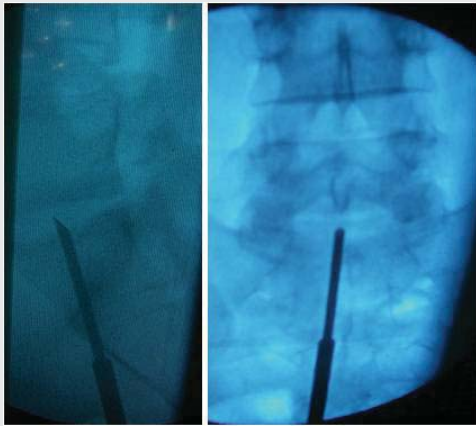


Figure 3c:

Once the position of the introducer trocar is confirmed under biplanar fluoroscopy, the blunt tip is exchanged for the sharp stylet which is then impacted into the sacrum.

channel into the L5-S1 disc space (Figure 3e). Superior endplate of S1 and L5-S1 disc space is passed with gently rotation of the reamer and then stopped on the inferior endplate of L5 without penetrating it at this moment. The reamer is then removed with the bone contained in the threads saved for later use as autologous bone graft material. The cutting-loop devices and disc extractors made from Nitinol memory-metal is specifically designed for a transsacral approach and it is used to perform a partial volumetric discectomy (Figure 3f-1,2,3). These cutting loops are passed into the L5-S1 sequentially with a preset angle and curvature to allow for a variety of cutting angles and lengths under fluoroscopic guidance to complete a rotational type discectomy. Additionally, cartilaginous endplates are carved off to create bleeding for the arthrodesis of cortical

surfaces with forward and back-angled rotation of loops under manual pressure. The fragmented disc material is captured with a special wire brush type capture device (Figure 3g-1,2). So, radial removal of the disc nucleus is achieved while maintaining outer annular integrity.

After discectomy, a funnel-type cannula is inserted into the disc space to introduce the bone graft material. It will be better if the graft material is chosen with the combination of autologous bone obtained during reaming, iliac crest bone marrow aspiration with or without concentration into a carrier matrix, demineralized bone matrices, and calcium triphosphates. After the impaction of 10-15 cc of graft material directly into the interbody space (Figure 3h), a smaller 7.5 mm diameter drill is inserted through the working sheath and penetrated directly into the L5 vertebral body. The 7.5 mm bit is then rotated and advanced to within 1 cm of the superior L5 endplate under biplanar fluoroscopy (Figure 3i). A final guide pin is inserted through the dilator sheath after removing the reamer.

A larger cannula is then slid over the final guide pin to allow placement of the 3D-Axial Rod prosthetic

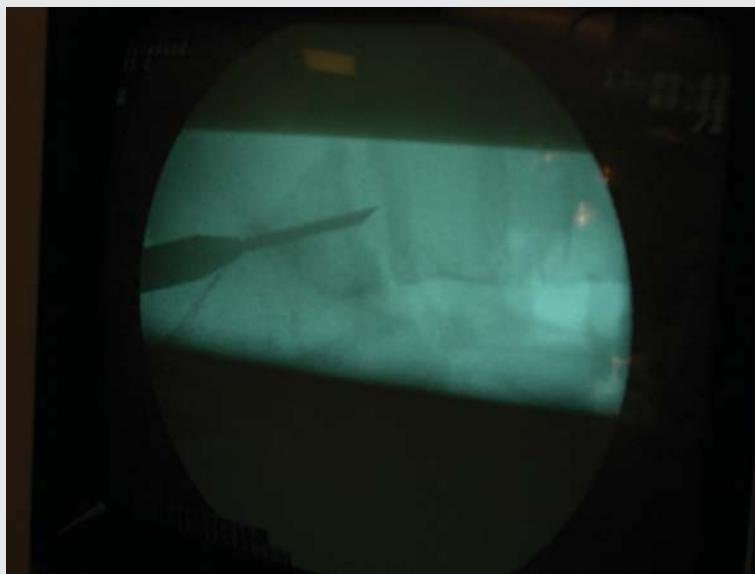


Figure 3d:

The partial volumetric discectomy is performed using a variety of proprietary cutting-loop devices specifically designed for a trans-sacral approach. These are inserted co-axially, deployed and then rotated to cut and fragment the disk nucleus.

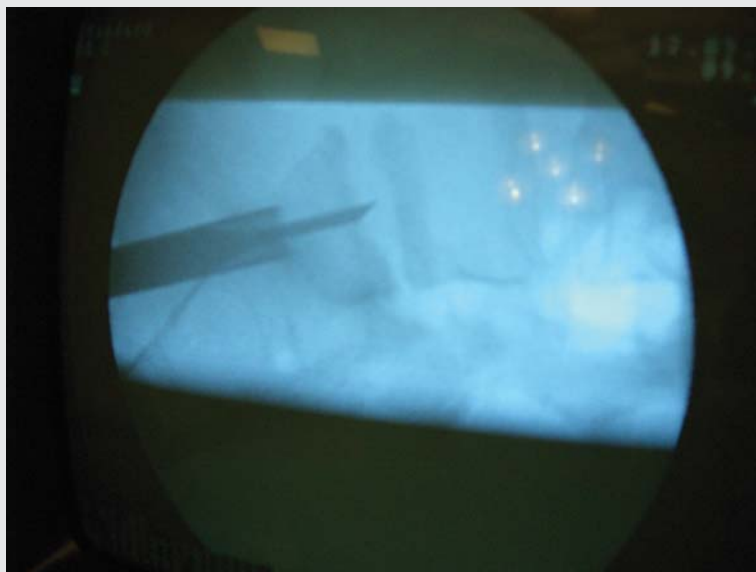


Figure 3e:

A 9 mm threaded reamer is inserted down the working portal into the sacrum to create the bony channel into the L5-S1 disc space.

device (Figure 3j). It is specially fabricated titanium prosthesis such that the threaded rod has two portions with different thread pitches. The superior part of the threaded cage that will engage into the L5 body has a diameter of 11 mm with a wider thread pitch as compared to the inferior S1 portion of the device which has a larger 14 mm diameter and a narrower thread pitch. The different diameter and thread pitch leads to distraction of the intervertebral disc space height as it is threaded between the S1 and L5 bodies. Appropriate sized screw is also used by measuring the distance off the guide-pin as well as by adding the amount of desired segmental distraction.

The appropriate sized 3D-Axial Rod is then cautiously inserted with a gentle movement over the previously introduced guide pin. It is then gradually rotated through the sacrum and into the intervertebral space with a T-handle. The differential pitch creates the distraction mechanism across the disc space as it enters the L5 body. The guide pin is then removed, when the 3D-Axial rod is advanced to the L5-superior endplate under biplanar fluoroscopy. Additional injection of iliac crest bone marrow aspirate, bone morphogenic protein, or other material can be injected through the center of the rod into the intervertebral

space. The injection portal is then disengaged with an inserted threaded plug to prevent graft extrusion. The working incision is then irrigated with antibiotic impregnated irrigation after removing the rod introducer cannula. After this processes, the incision is closed gently.

L5-S1 minimally invasive screw fixation is performed after anterior L5-S1 interbody fusion. The pedicles of L5 and S1 are localized and marked with an 11-gauge bone under A-P and lateral fluoroscopy guidance. The skin and fascia is incised with 2 bilateral small incisions. The #11 jamshidi needle is located at the top of the pedicle and advanced

into the pedicle through the muscles under biplanar fluoroscopic confirmation. The trocar is removed and exchanged for a kirschner-wire ^(3,11).

The pedicle is tapped and an appropriately-sized cannulated Pathfinder (Abbott Spine; Austin, TX; USA) screw and extender sleeve is placed into the pedicle and vertebral body under fluoroscopic control after the sequential dilators are placed. The other three screws are placed with the same steps. The bilateral appropriately sized rods are then placed down the minimally invasive pathfinder extender sleeves and locked into place. The small incisions closed primarily with 0-vicryl in the fascia and 3-0 vicryl subcutaneously after removing the sleeves. Biplanar fluoroscopic confirmation of the construct is then obtained finally ^(3,11) (Figure 3k).

5. Postoperative Care:

The patient is returned to the upright position immediately after the operation. A muscle relaxant given systematically. The day after surgery, rehabilitation is begun to mobilize the lumbar spine and relax the paravertebral muscles. The patient is discharged 2 days after surgery. The waterproof bandage permits

female. Although the hypogastric nerves are located several centimetres laterally at S1-S2, the surgeon must care on these neural structures⁽³⁾.

Vascular structures in the presacral space are the middle sacral artery and veins. Bleeding from the transverse sacral vein or the midline sacral artery is also possible, but at S2 the midline sacral artery is often small or non existent. The risk of venous bleeding is low as the technique begins with sweeping the soft tissues off the sacrum with a blunt dilator⁽³⁾.

Spinal infection is one of the possible complication but we believe the risk of infection related to the paracoccygeal approach has been low because the procedure is brief, percutaneous, and results in very

little devitalized tissue and anatomic dead space⁽³⁾.

Bowel perforations, re-operations, and implant breakage are potential complications but we have not encountered yet.

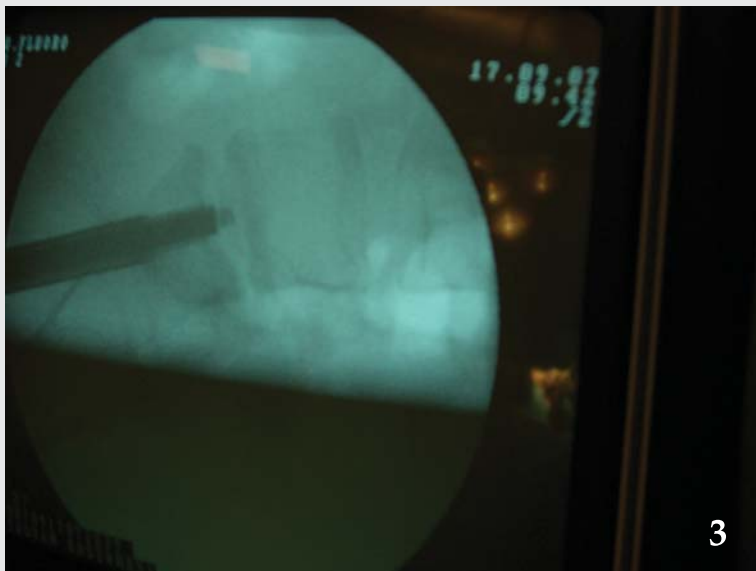
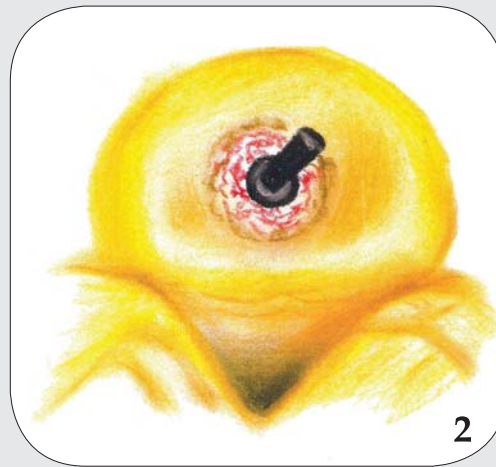

Figure 3f; 1-2-3:

The cutting-loop devices and disc extractors made from Nitinol memory-metal is specifically designed for a transsacral approach and it is used to perform a partial volumetric discectomy.

the patient to bath or take a shower normally. The resumption of previous activities and normal life activities is encouraged as soon as possible. The patient may return his job in 3 weeks after surgery.

6. Complications and Avoidance:

A number of complications are possible with this technique, but with care and anticipation, most can be avoided.

Neural structures in presacral space are hypogastric nerves 1 cm lateral to the midline at the sacral promontory, parasympathetic nerves that arise from the ventral roots of S3-S4 in the male and S2-S4 in the

7. Case illustrations:

Case 1:

A 62-year-old obese male with severe low back pain admitted to the neurosurgery department. There was no history of prior back surgery or trauma. Physical examination revealed no abnormalities. Plain radiographs, CT and MRI of the lumbosacral spine revealed narrowing and degeneration at the




Figure 3g: 1-2:

Cartilaginous endplates are carved off to create bleeding for the arthrodesis of cortical surfaces with forward and back-angled rotation of loops under manual pressure. The fragmented disc material is captured with a special wire brush type capture device.

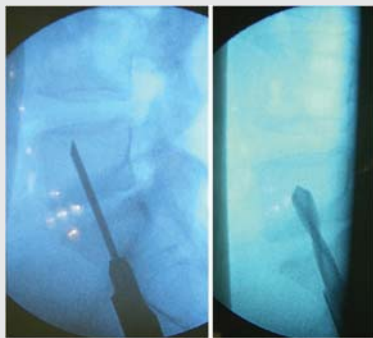


Figure 3i:

A smaller 7.5-mm diameter drill is inserted through the working sheath and intervertebral space and penetrated directly into the L5 vertebral body.

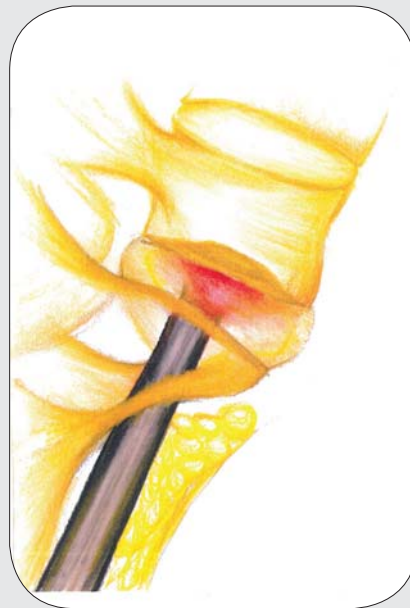

Figure 3h:

10-15 cc of graft material is impacted directly into the interbody space.

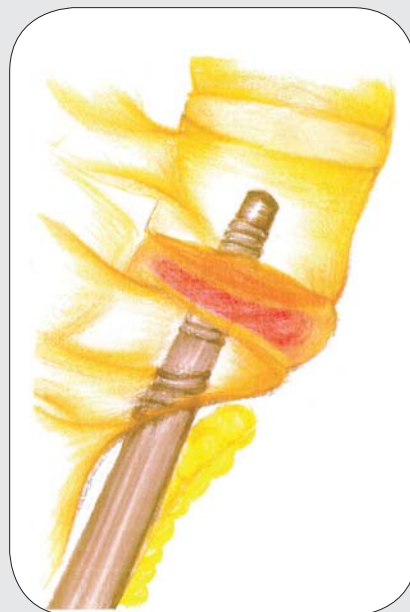

Figure 3j:

A larger cannula is then slid over the final guide pin to allow placement of the 3D-Axial Rod prosthetic device.

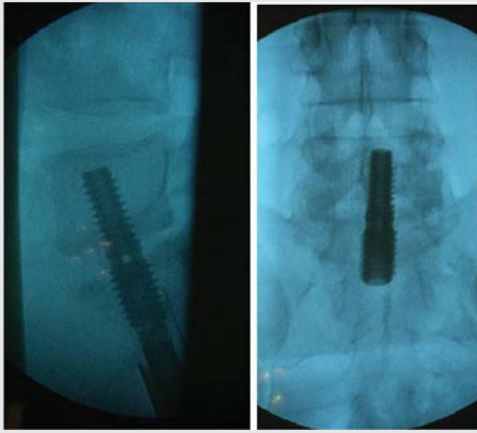


Figure 3i:

A smaller 7.5-mm diameter drill is inserted through the working sheath and intervertebral space and penetrated directly into the L5 vertebral body.

L5-S1 disc space without motion in flexion and extension (Figure 4a,b). Additionally, discography was positive at L5-S1 level and negative at L4-5 level. The patient underwent a transsacral fusion with AxialLif, Trans-1; Wilmington, NC; USA) system with the combination of posterior minimal invasiv stabilization (Pathfinder, Abbott Spine; Austin,TX;

USA). Surgery was completed in 3 hours; blood loss estimated at 100 cc. He was discharged from the hospital 2 days following the surgery. Three weeks after surgery, he was off narcotic pain medications and had returned to work.

8. References

1. Yuan PS, day TF, Albert TJ, Morrison WB, Pimenta L, Cragg A, Weinstein M. Anatomy of the percutaneous presacral space for a novel fusion technique. *J Spinal Disord Tech* 2006; 19: 237-241.
2. Perin NI: Complications of minimally invasive spinal surgery. *Neurosurgery* 2002; 51 (suppl 6): 26-36.
3. Marotta N, Cosar M, Pimenta L, Khoo LT. A New minimally invasive presacral approach and instrumentation technique for anterior L5-S1 intervertebral discectomy and fusion. *Neurosurg Focus* 2006; 20: E9.
4. Khoo LT, Fessler RG: Microendoscopic decompressive laminotomy for the treatment of lumbar stenosis. *Neurosurgery* 2002; 51 (Suppl 2): 144-51.
5. Khoo LT, Palmer S, Laich DT, Fessler LG: Minimally invasive percutaneous posterior lumbar interbody fusion. *Neurosurgery* 2002; 51 (Suppl 2): 166-181.

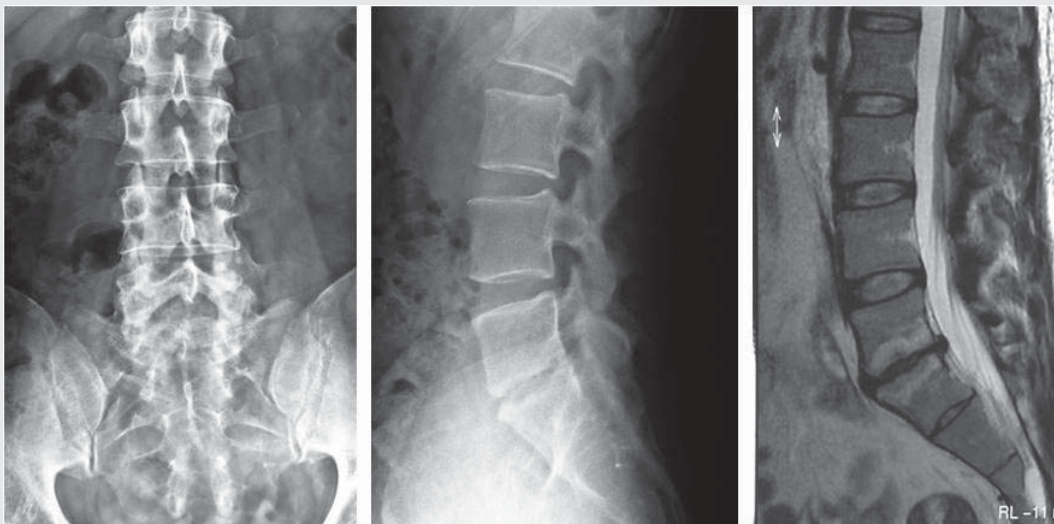

Figure 4a:

Preoperative x-ray graphies and T2-weighted sagittal MRI demonstrates the significant loss of height and degenerative disc disease at the L5-S1 disc space.

6. Ethier DB, Cain JE, Yaszemski MJ: The influence of anulotomy selection on disc competence. A radiographic, biomechanical, and histologic analysis. *Spine* 1994; 19: 2071-6.
7. Guiot BH, Khoo LT, Fessler RG: A minimally invasive technique for decompression of lumbar spine. *Spine* 2002; 27: 432-8.
8. Slosar PJ, Reynolds JB, Koestler M: The axial cage. A pilot study for interbody fusion in a higher-grade spondylolisthesis. *Spine J* 2001; 1(2): 115-20.
9. Trambert JJ: Percutaneous interventions in the presacral space: CT guided precoccygeal approach-early experience. *Radiology* 1999; 213: 901-904.
10. Cragg A, Carl A, Casteneda A, Dickman C, Guterma L, Oliveria C: New percutaneous Access method for minimally invasive anterior lumbosacral surgery. *J Spinal Disord Tech* 2004; 17: 21-28.
11. Ledet EH, Carl LA, Cragg A. Novel lumbosacral axial fixation techniques. *Expert Rev Med Devices* 2006; 3(3): 327-34,

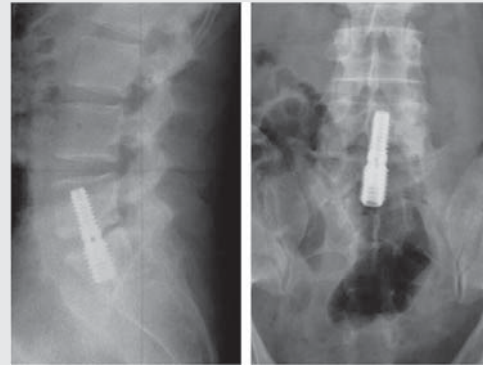


Figure 4b:

Preoperative x-ray graphies and T2-weighted sagittal MRI demonstrates the significant loss of height and degenerative disc disease at the L5-S1 disc space.



POSTERIOR PERCUTANEOUS TRANSPEDICULAR LUMBAR DYNAMIC STABILIZATION

Tuncay Kaner MD, A Fahir Ozer MD

1. Introduction:

Pain is the foregoing symptom of the patient whose disc degeneration deforms gradually. This patient is neurologically intact but the back ache or the pain radiating to the legs often disturbs him. In fact, pain is a symptom of a degenerative process. Pain in this process has more than one source. Rupture of the disc capsule, mechanical nociception, stimulation of the nerve root at the epidural space by the intradiscal chemical substance (chemical nociception), relaxation of the ligamentous connections of the vertebrae because of instability, erosion of the cartilage of the facet articulations or rupture of the joint capsule, rupture of the interspinous or supraspinous ligaments are all known as pain sources for these patients⁽¹⁻⁴⁾.

Dr. Henry Graff⁽⁵⁾ from Belgium was the first to use the concept of 'Dynamic Stabilization' in 1980's, he claimed that in chronic instability, fusion surgery is not necessary, but just simple stabilization of the vertebral column aiming to carry the load is sufficient. He explained that lumbar back pain can be relieved by supporting or correcting the tension band of the posterior column with the help of a posterior ligament system.

Biomechanical experiments prove that all the mentioned systems correct axial loading on the spinal column, normalize the neutral zone and supply a stabilization force close to those of the rigid systems⁽⁶⁾. But concerning the Graff tension bands, because the posterior column is stabilized under compression, foraminal stenosis is inevitable. Nevertheless, they cause posterior annular bulging and as a result, spinal stenosis is expected. The Dynesis system (Zimmer Spine Inc. Warshow, IN) was then invented as a result of these disadvantages^(7,8). In this system, a spacer

is located around the tension band to prevent the excessive compression. But a disadvantage of this system is that, there is no standardization for the tension force of the band.

It was Dr Stempel's idea to place a joint between the screw's head and stem (Cosmic, Ulrich AG, Germany)⁽⁹⁾. This is the concept of the dynamic screw. Originally, this device was designed to facilitate fusion. But after a follow up period of the patients, it was realized that; although the pseudoarthrosis ratio is high with this system, the complaints of the patients improved. So, spine surgeons started using this system without fusion. Biomechanically, the dynamic and the rigid systems supply almost the same stabilization strength.

With the posterior transpedicular dynamic stabilisation systems (PTPDS), while the posterior tension band is functioning perfectly, the vertebral segmental motion is not eliminated. Ideally, it is best to use the rigid rod and dynamic screw system for stabilization of one motion segment. Using these systems for more than one motion segment may result to eliminate their dynamic property and thus, they gain the character of rigid systems. For this reason, it is ideal to use dynamic rod and dynamic screw combination for more than two motion segments. The follow up of our patients operated with this combination possess fair outcomes⁽¹⁰⁾.

Intervertebral artificial disc prostheses, disc cushions, nucleus pulposus supporters are among the dynamic stabilisation devices for the anterior column. Interspinous supporters and PTPDS are the dynamic systems for the posterior column. PTPDS can be categorized in three subgroups.

- Stabilization via rigid rod and dynamic pedicular screw;

- Stabilization via dynamic rod and rigid pedicular screw;
- Stabilization via dynamic rod and dynamic pedicular screw.

Lomber dynamic stabilization is one of the promising spinal surgical techniques. With the aim of this system, the ratio of the spinal fusion surgery will lessen by time; while the morbidity and mortality due to fusion are going to decrease, the surgeon and patient satisfaction will increase considerably.

2. Indications:

The indications of this system are:

- Discogenic pain, recurrent disc hernias, degenerative antero and retro spondylolisthesis, lumbar spinal stenosis.

3. Contraindications:

There are no specific contraindications for this system except general medical vital problems.

4. Surgical Technique:

4.a. Surgical Equipment:

C-arm fluoroscopy, operating table suitable for spine surgery, operating microscope, high speed drill and transpedicular dynamic stabilization instruments are essential for surgical procedure (Figure 1a, 1b). It will be better to support the surgery with neuro monitoring recordings systems.

4b. Operating Room Set-up:

The prone position of the patient is preferred and the C-arm and monitor are placed according to the localization of the surgeon. It will be better if the video and C-arm monitors

are placed on the opposite side of the surgeon. The assistant is located opposite to the surgeon and the nurse is at the caudal of the patient (Figure 2).

4.c. Patient Positioning:

The patient was brought to the operation room, then, pre-operative evaluation was performed following the induction of general anesthesia. Prone position was given to the patient on the operating table. The level of the PTPDS is signed with the C-arm before medical clearance and sterile covering (Figure 3).

4.e. Surgical Technique:

After the determination of pathology level under C-arm, bilateral 3 cm length stab incision or 1.5 cm incision for each screw was made 3 cm off midline. First, under the AP and lateral fluoroscopic guidance, the pedicle is identified and the guide wire is inserted into the marked pedicle. With a special apparatus, the grooved screws are placed through the guide wire. The screw driver is slid on the guide wire and the screw is inserted into the vertebra corpus through the pedicle under AP and lateral fluoroscopy (Figure 4a, b,c,d). The same procedure is applied for the caudal and cranial pedicles under AP and lateral fluoroscopy (figure 4e,f). After the insertion of unilateral screws, the opposite side located surgeon performs the same procedures to the opposite side pedicles under AP and lateral fluoroscopy (Figure 4g,h,i).

Then, the guide wire is taken out and the system is locked. The rod is placed by using the screw guide and the screws are connected to the rod (figure 4j). Finally, the whole application system is discharged.

The hemostasis should be obtained with a bipolar cautery and a gentle tamponade with thrombin soaked gel-foam pledgets. After the irrigation of area, use of epidural morphine paste or similar cocktails may help to reduce postoperative pain and allow for more rapid recovery and ambulation. A routine closure of the fascia and skin is performed after removing the PTPDS systems.

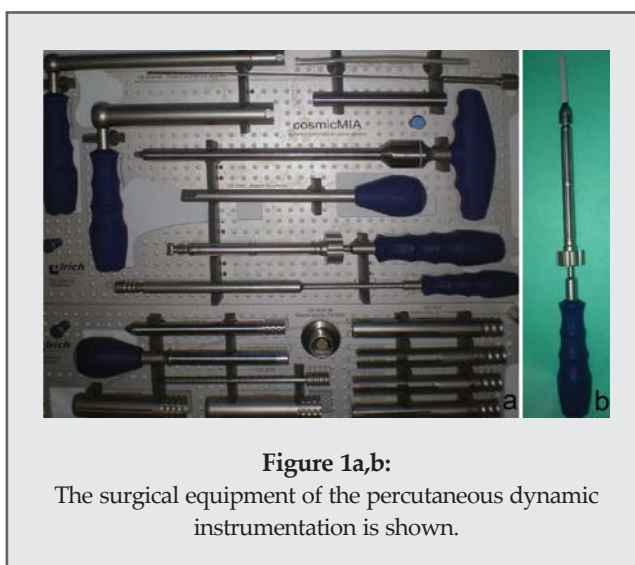
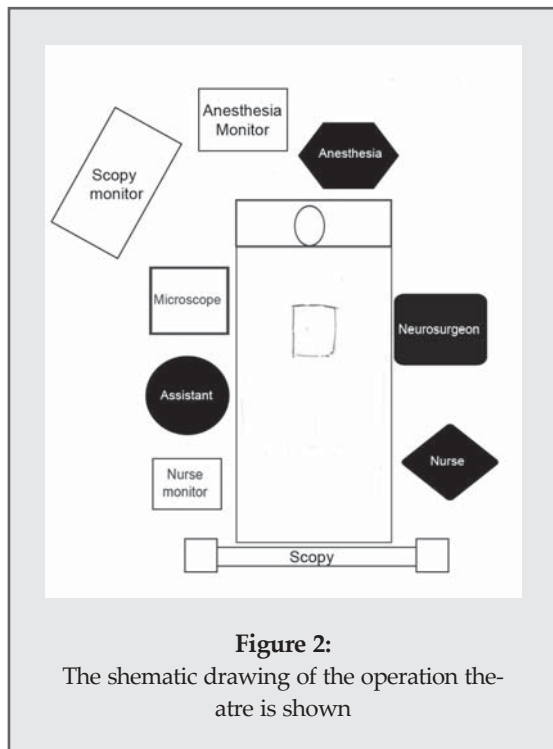


Figure 1a,b:

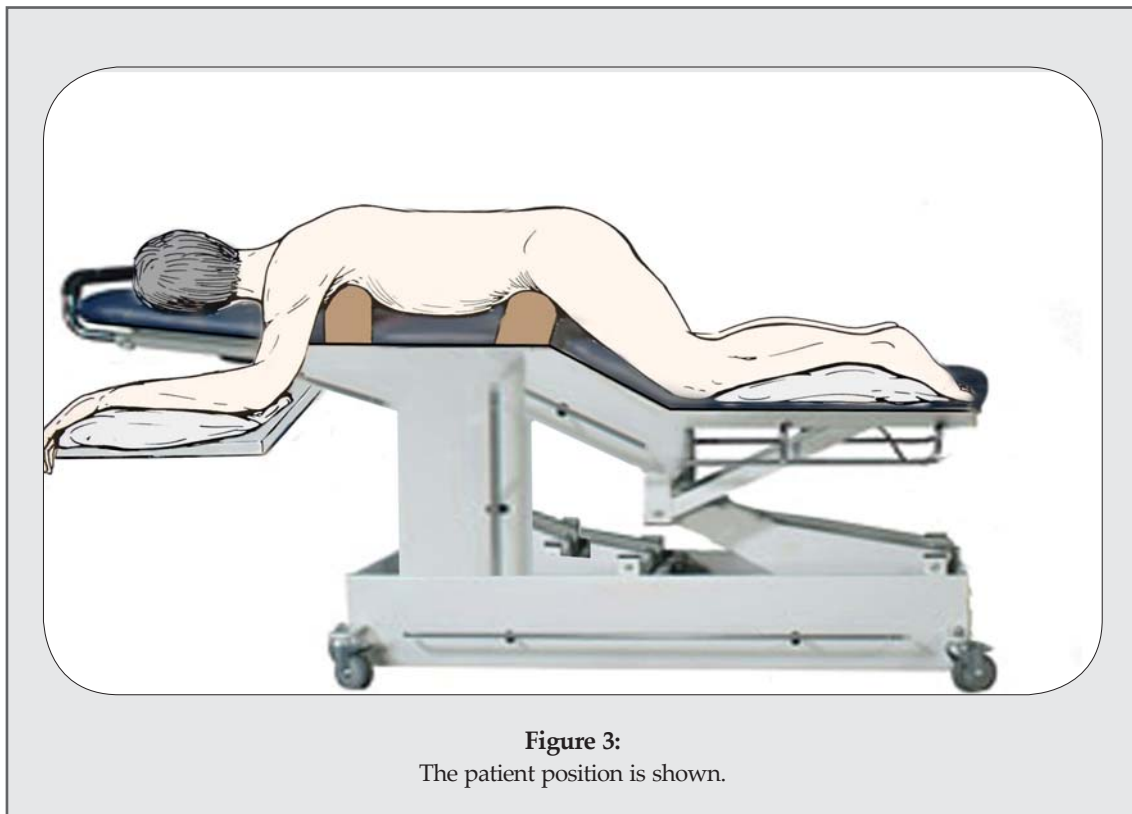
The surgical equipment of the percutaneous dynamic instrumentation is shown.



There is no need to use a drain if we ensure from the hemosthesis. The fascia is closed with reabsorbable 0-Vicryl stitches and it is continued with 3-0 Vicryl stitches for subcutaneous layer after the injection of marcain (0.25%). Either Steri-Strips® or Dermabond® can be used to cover the skin. These materials may keep the skin edges closely with their waterproof barrier speciality for a 7- to 10-day period.

5. Postoperative Care:

The patient is returned to the supine position and taken to the post-anesthesia recovery unit after awakening from anesthesia. A muscle relaxant and non-steroidal anti-inflammatories are given systematically. The patients are allowed to mobilize and rehabilitation in the following hours after surgery to relax the paravertebral muscles. The patients may be discharged the day after surgery. Depending on their pre-operative medications, patients undergoing PTPDS may be discharged on a combination of muscle relaxant, and non-steroidal anti-inflammatories. The patient may return his job in 2 weeks after surgery.



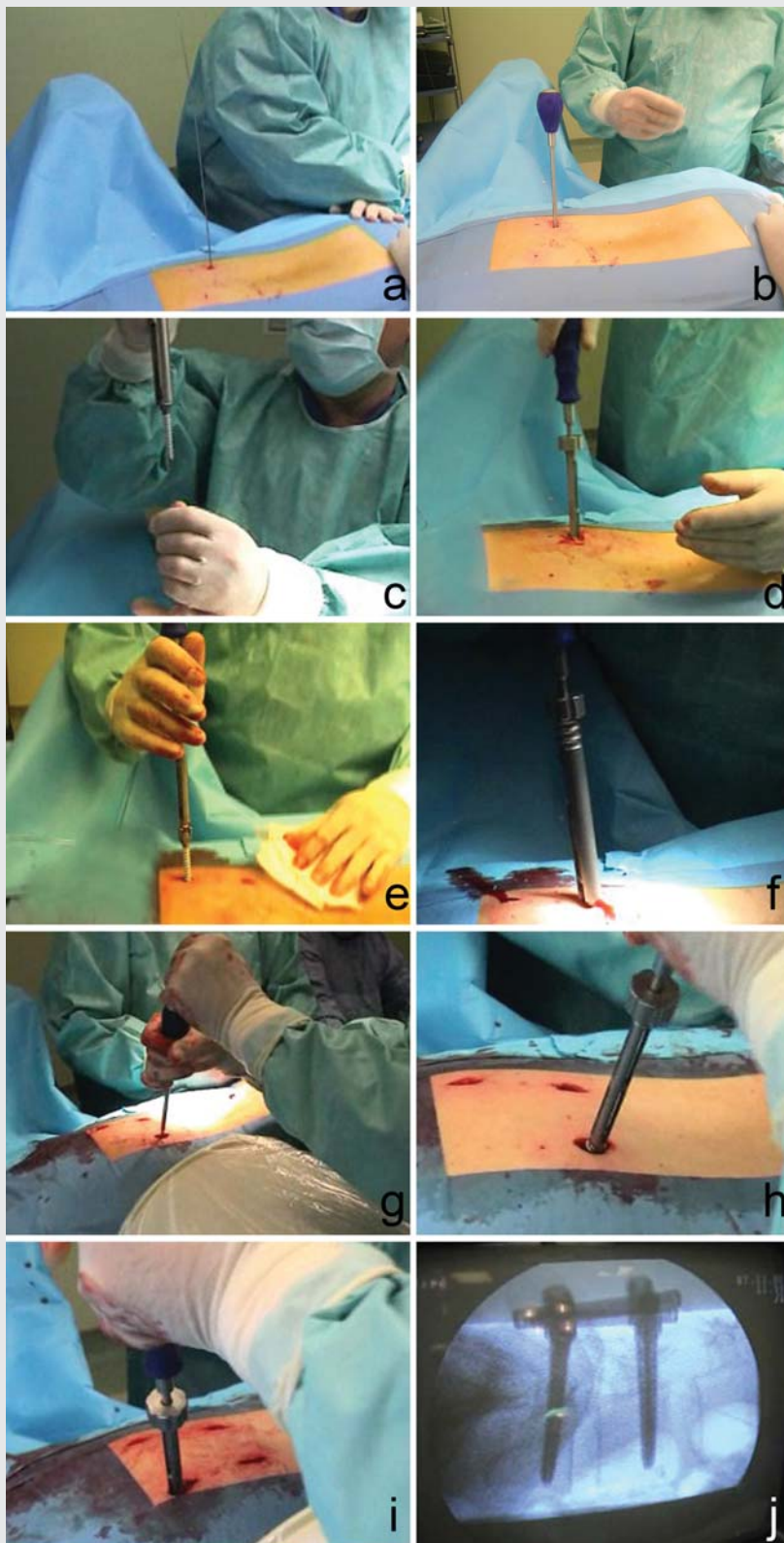


Figure 4a,b,c,d:

With a special apparatus, the grooved screws are placed through the guide wire. The screw driver is slid on the guide wire and the screw is inserted into the vertebra corpus through the pedicle under AP and lateral fluoroscopy.

Figure 4e,f:

The same procedure is applied for the caudal and cranial pedicles under AP and lateral fluoroscopy

Figure 4g,h,i:

After the insertion of unilateral screws, the opposite side located surgeon performs the same procedures to the opposite side pedicles under AP and lateral fluoroscopy

Figure 4j:

The guide wire is taken out and the system is locked. The rod is placed by using the screw guide and the screws are connected to the rod. Finally, the whole application system is discharged.

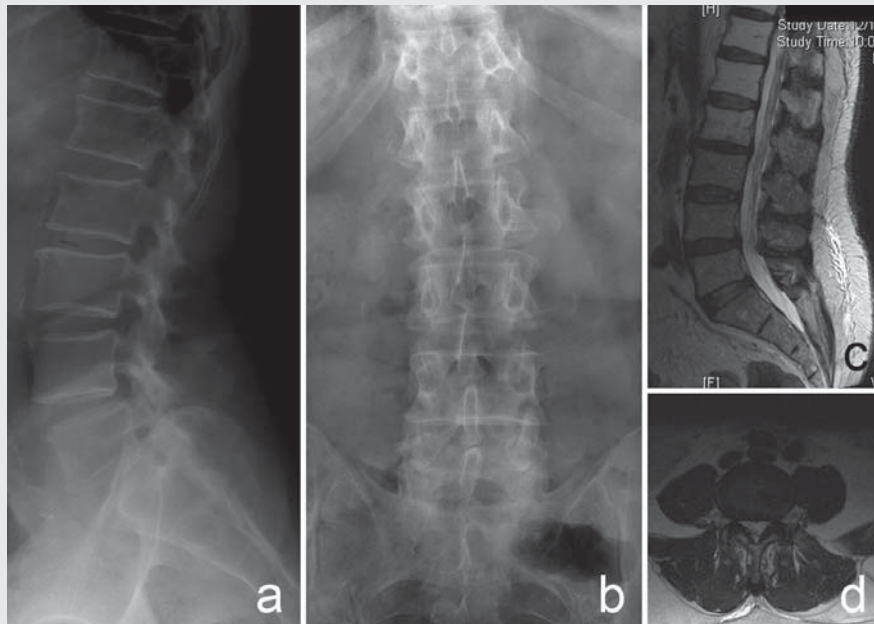


Figure 5:
a,b) The preoperative AP and lateral lumbosacral x-ray graphies of the patient,
c,d) The T2 weighted sagittal and axial MRI images.

6. Complications and Avoidance:

Neural injury may occur due to the removal of bone structures and disc fragments. Penetration of instruments may cause to contusion of neural structures. These kinds of spinal cord injuries may result with paraplegia, monoplegia or monoparesia. Iliac artery, ven and ureter injuries may occur due to the removal of disc fragments. More practice with cadavers, advance anatomy education and familiar to the instruments may decrease these complications before starting the PTPDS.

Caring on the sterilisation of the operation sets, instruments and operation area may prevent the deep paraspinal, epidural or superficial wound infection. The hemostasis before removing the PTPDS systems may prevent the postoperative hematoma. The occurrence of cerebrospinal fluid (CSF) leakage from a small dural tear may be treated with fibrin glue, fat or muscle grafts. Direct repair can be necessary for large dural tears and CSF leaks.

7. Case Illustrations:

63 years old male patient was admitted to our department complaining of severe pain during the last 30 days. He was hypertensive and diabetic. Neurologic examination was normal except severe back pain. The radiological images showed L4-5 grade I spondylolisthesis and disc degeneration (Figure 5a, b, c, d). Discography was performed L4-5 disc degeneration was shown and pain provocation was positive (Figure 5e).

L4-5 percutaneous dynamic pedicular instrumentation (CosmicMia, Ulrich AG, Germany) was performed to the patient (Figure 5f, g, h). Postoperative course of the patient was uneventful and he was discharged 3 days after the operation.

8. References:

1. Freynhagen R, Baron R. The evaluation of neuropathic components in low back pain. *Curr Pain Headache Rep* 2009;13(3): 185-90.
2. Igarashi A, Kikuchi S, Konno S. Correlation between inflammatory cytokines released from the lumbar facet

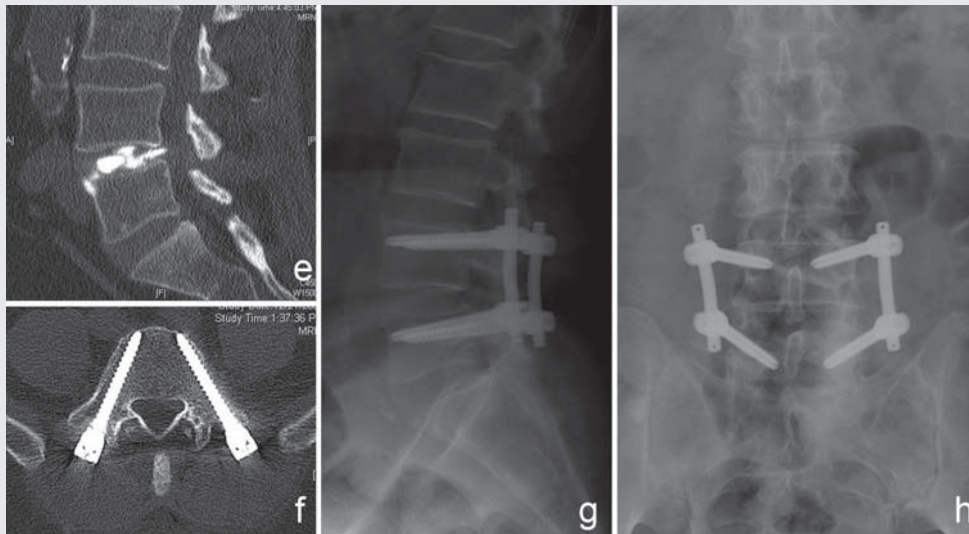


Figure 5:

e) Provocative discography under sagittal CT images, **f)** Postoperative axial view of the dynamic screws, **g,h)** Postoperative AP and lateral lumbar x-ray graphics of the patient.

- joint tissue and symptoms in degenerative lumbar spinal disorders. *J Orthop Sci* 2007;12(2):154-60.
- Naguszewski WK, Naguszewski RK, Gose EE. Dermatome somatosensory evoked potential demonstration of nerve root decompression after VAX-D therapy. *Neurol Res* 2001;23(7): 706-14.
 - Kawakami M, Hashizume H, Nishi H, Matsumoto T, Tamaki T, Kuribayashi K. Comparison of neuropathic pain induced by the application of normal and mechanically compressed nucleus pulposus to lumbar nerve roots in the rat. *J Orthop Res* 2003; 21(3): 535-9.
 - Graf H. Lumbar instability: surgical treatment without fusion. *Rachis* 1992; 412: 123-137.
 - Schmoelz W, Huber JF, Nydegger T. Dynamic stabilization of the lumbar spine and its effects on adjacent segments: an in vitro experiment. *J Spinal Disord Tech* 2003; 16: 418-423.
 - Cunningham BW, Kotani Y, McNulty PS, Cappuccino A, McAfee PC. The effect of spinal destabilization and instrumentation on lumbar intradiscal pressure. An in vitro biomechanical analysis. *Spine* 1997; 22: 2655-2663.
 - Kotani Y, Cunningham BW, Cappuccino A, Kaneda K, McAfee PC. The effects of spinal fixation and destabilization on the biomechanical and histologic properties of spinal ligaments. An in vivo study. *Spine* 1998; 23: 677-682.
 - Strempe AV, Moosmann D, Stoss C, Martin A. Stabilisation of the Degenerated Lumbar Spine in the Nonfusion Technique with cosmic Posterior Dynamic System. *WSJ* 2006; 1(1): 40-47.
 - Kaner T, Sasani M, Oktenoglu T, Cosar M, Ozer AF. Utilizing Dynamic Rods with Dynamic Screws in the Surgical Treatment of Chronic Instability. *Turk Neurosurg* (in press, 2009).

5k

LUMBAR INTERSPINOUS DEVICES

Ali Arslantas MD, Sait Naderi MD

1. Introduction:

Lumbar spinal stenosis (LSS) is a common disorder causing low back pain, leg pain and neurogenic claudication. A variety of treatment options have been described to treat the LSS. However, high complication rates of decompression operations, likelihood of adjacent segment disease after spinal fusion, and elder age of this patient population led to development of minimal invasive approach to patients with LSS.

Interspinous devices (ISD), the implants placed between lumbar spine spinous processes, were developed as minimal invasive option for treatment of ligamentous lumbar spinal stenosis (LSS). They restrict the lumbar spine extension, and widen the spinal canal AP diameter, and in turn, reduce neurogenic claudication. The advantages of the ISDs were reported to be easy implantation, minimal invasive approach, minimal necessity for tissue retraction, short operation duration, the opportunity for application under local anesthesia, and less risk of corrosion.

2. Indications

The effectiveness of ISDs have been reported in a variety of indications including LSS, degenerative spondylolisthesis (Grade I), facet joint disease, disc instability, and discogenic low back pain. However, the main indication is ligamentous LSS associated with the following criteria:

- Central or lateral lumbar spinal stenosis confirmed by CT or MRI scan
- Neurological intermittent claudication
- No response to conservative therapy

- Only one or two stenotic level
- Age over 50 years old

3. Contraindications

There are only a limited number of contraindications, including an allergy to titanium or alloy, severe osteoporosis, anatomical degenerations such as ankylosing spondylitis, high grade spondylolisthesis, scoliosis, fracture of spinous process or pars interarticularis, cauda equina syndrome, widespread spinal stenosis, and infection

Kinds of ISDs

Currently more than 10 ISDs are used in clinical practice. They are similar to each other from the design and biomechanical standpoints. Here, the general aspects of some of these devices are reviewed.

The *X-Stop* interspinous decompression system (St. Francis Medical Tech., Alameda, CA) was developed to treat neurological claudication in spinal stenosis. The *X-Stop* composed of an oval titanium spacer, which separates the spinous processes and limits extension, and two lateral wings which prevents anteriorly or laterally migration of the device (1). It was designed to limit extension on the affected level or levels while allows flexion, axial rotation and lateral bending motions.

Wallis System (Abbott spine, inc, Austin, TX) was developed to prevent low back pain from intervertebral segmental instability. Although both preclinical and clinical studies were limited, Senegas reported that this system have restored the stability due to the degenerative instability, reduced loading on facet joints and disc, increased disc hydration, and pre-

served lumbar lordosis. Indications of Wallis were reported to be recurrent herniated disc, voluminous herniated disc in young adults, degenerative disc disease at a segment adjacent to fusion, and Modic 1 degenerative lesions. It was reported to be contraindicated in cases with high grade degenerative lesions, spondylolisthesis, osteoporosis, L5-S1 level, litigation, and non-specific low back pain ^(2,3).

The *DIAM* (Medtronic Sofamor Danek, Memphis, Tennessee, USA) is a dynamic stabilization device, designed to reduce segmental motion at the degenerative segment by shock absorber structure. Taylor and Ritland have reported the effectiveness of this interspinous device in reducing the increased segmental flexion-extension motion after a discectomy or partial facetectomy. The reported indications include disc herniation, lumbar spinal stenosis, facet syndrome, black disc and adjacent segment pathologies after fusion ⁽⁴⁾.

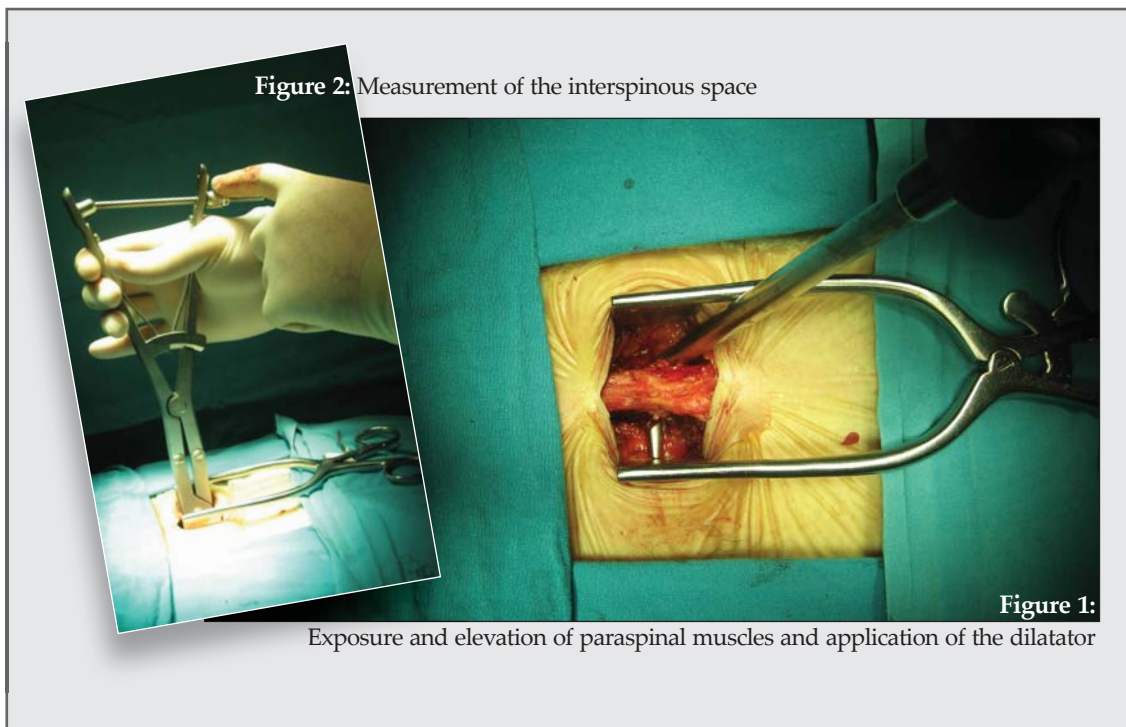
ISS (Interspinous System-Biomet), *U-Device* or *Coflex Spine Motion U-Device* (Fixano), *PEEK* (Optima) are the other kinds of the ISDs available in the market. There a limited number of clinical and biomechanical studies addressing these systems.

Recently, preclinical and clinical studies are increasing, particularly in the X-stop decompression system.

4. Surgical Procedure

The surgical technique for implantation of the ISDs is similar in various devices. Here, we describe the technique used for X-stop ISD implantation.

This minimally invasive surgical procedure spell about 20 minutes to one hour. Surgical implantation is performed under local anesthesia or general anesthesia. The patient is placed on the right lateral decubitus position on the operating table in slight flexion position to prevent extension. A midsagittal approximately 3 cm incision is made over the spinous processes. The paraspinal muscles are elevated from spinous process and medial lamina. After fluoroscopic identification of the correct level, firstly small then large dilators are inserted into the interspinous process area (figure 1 and 2). After this stage, sizing instrument is inserted and dilated until the supraspinous ligament become taught. Suitable device is inserted between the spinous processes as close to the aspect of the lamina as possible (figure 3) and universal wing is attached to the tissue expander (figure 4). Then the incision is closed. In our experience mean operation time is approximately 20 minutes.



5. Complications

Most of complications are related to the inappropriate size of the implant, and inappropriate location. A complication avoidance requires a careful decision making with regard to the implant size and implant location (Table 1).

Table 1: Complications of interspinous devices
Implant not positioned correctly
Implant dislodgement or movement
A fracture of the spinous process during implantation
Failure of the procedure, continuation of the symptoms
Additional surgery
Mechanical failure of implant
Foreign body reactions

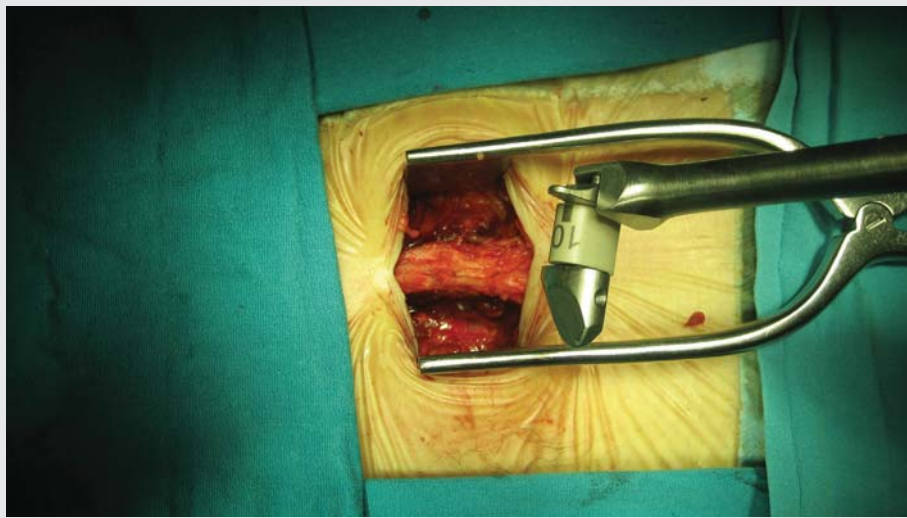


Figure 3: The application of the device

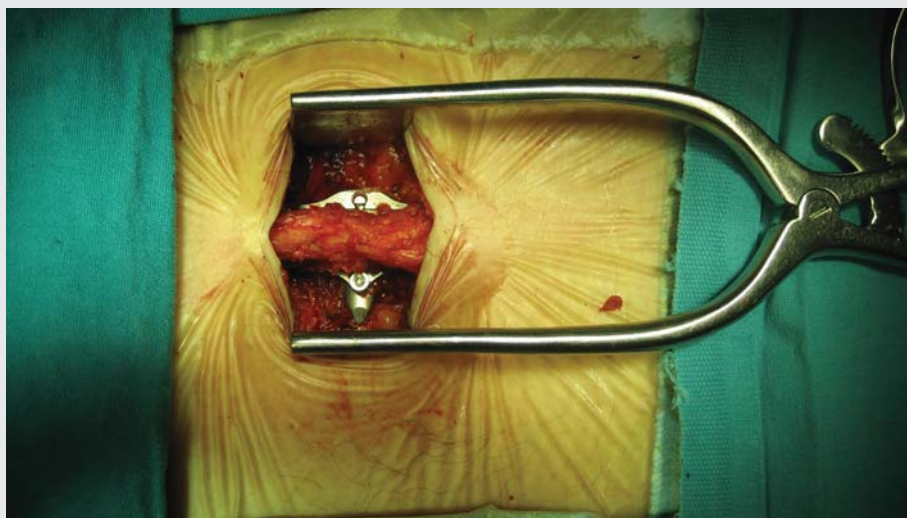


Figure 4: Final position of the ISD

6. Postoperative Care

There is no special consideration regarding postoperative care after this procedure. Patients could be mobilized within the first hours after this minimal invasive surgery.

7. Conclusion

The results of recent studies have shown that ISDs are effective and safe treatment options for patients with neurological intermittent claudication secondary to ligamentous LSS. In an invitro study, Swanson *et al*⁽⁵⁾ demonstrated the effectivity of ISDs on disc pressure at instrumented level, while Lindsay *et al*⁽⁴⁾ shown that the implant reduced the range of motion during flexion-extension and not affected at the adjacent levels. The other studies shown that implant prevents narrowing of the lomber spinal canal and neural foramen in extension and reduced facet loading at the implanted level^(6,7).

In a clinical study, Zucherman *et al*⁽⁸⁾ reported that X-Stop improved symptoms and physical functions compared with conservative treatment and steroid injections in two-year prospective randomized trial multicenter study. Richard *et al*⁽⁹⁾ have also reported similar results. They have also reported no major complications after the surgery. Short operation time (mean operative time was 54 minutes in Zucherman study and 51.2 minutes in Richards study) and minimally blood volume loss (mean blood lose volume 46mL in Zucherman study and 40.1-57.9 mL in Richards study) were other advantageous aspects of this surgery.

Other clinical studies focused on other aspects of ISDs. While Lee *et al*⁽¹⁰⁾ have shown that 40% of patients improved at 9 and 18 months following surgery, Siddiqui *et al*⁽¹¹⁾ shown that its effectivity in only short time period. Siddiqui have also reported two spinous process fracture during the operation. On the other hand, in a study by Verhoof *et al*⁽¹²⁾, X-Stop interspinous device showed high failure rate in lumbar spinal stenosis with degenerative spondylolisthesis.

Finally, it can be concluded that ISDs are effective in aged patients with ligamentous LSS. There is need to studies comparing long term results of different ISDs.

8. References:

1. Lindsay DP, Swanson KE, Fuchs P, Hsu KY, Zucherman JF, Yerby SA. The effects of an interspinous implant on the kinematics of the instrumented and adjacent levels in the lumbar spine. *Spine* 2003; 28: 2192-7.
2. S enegas J. Minimally Invasive Dynamic Stabilization of the Lumbar Motion Segment with an Interspinous Implant. In: Mayer HM (ed): *Minimally Invasive Spine Surgery second Edition. A Surgical Manual*. Springer, Berlin Heidelberg. 2006, pp 459-465
3. Senegas J. Dynamic lumbar stabilization with the wallis interspinous implant Dynamic Reconstruction of the. In: Kim DH, Cammisa FP, Fessler RG (eds): *Dynamic Reconstruction of the Spine*. Thieme Medical Pub, New York. 2006, pp 258-267
4. Taylor J. and S. Ritland Technical and Anatomical Considerations for the Placement of a Posterior Interspinous Stabilizer. In: H. Michael Mayer (ed) *Minimally Invasive Spine Surgery second Edition. A Surgical Manual* pringer Berlin Heidelberg. 2006, pp 466-475
5. Swanson KE, Lindsey DP, Hsu KY, Zucherman JF, Yerby SA. The effects of an interspinous implant on intervertebral disc pressures. *Spine* 2003; 28:26-32.
6. Thunder RM, Hsu KY, Zucherman JF The x stop interspinous process decompression system for the treatment of lumbar neurological claudication. In: Kim DH, Cammisa FP, Fessler RG (eds): *Dynamic Reconstruction of the Spine*. Thieme Medical Pub, New York. 2006, pp 251-257
7. Wiseman CM, Lindsey DP, Fredrick AD, Yerby SA. The effect of an interspinous process implant on facet loading during extension. *Spine* 2005; 30: 903-907.
8. Zucherman JF, Hsu KY, Hartjen CA, Mehlic TF, Implicito DA, Martin MJ, Johnson DR 2nd, Skidmore GA, Vessa PP, Dwyer JW, Puccio ST, Cauthen JC, Ozuna RM. A multicenter, prospective, randomized trial evaluating the X STOP interspinous process decompression system for the treatment of neurogenic intermittent claudication: two-year follow-up results. *Spine* 2005; 30: 1351-1358.
9. Richards JC, Majumdar S, Lindsey DP, Beaupr e GS, Yerby SA. The treatment mechanism of an interspinous process implant for lumbar neurogenic intermittent claudication. *Spine* 2005; 30: 744-749.
10. Lee J, Hida K, Seki T, Iwasaki Y, Minoru A. An interspinous process distractor (X STOP) for lumbar spinal stenosis in elderly patients: preliminary experiences in 10 consecutive cases. *J Spinal Disord Tech* 2004; 17:72-77.
11. Siddiqui M, Smith FW, Wardlaw D. One-year results of X Stop interspinous implant for the treatment of lumbar spinal stenosis. *Spine* 2007; 32:1345-8.
12. Verhoof OJ, Bron JL, Wapstra FH, van Royen BJ. High failure rate of the interspinous distraction device (X-Stop) for the treatment of lumbar spinal stenosis caused by degenerative spondylolisthesis. *Eur Spine J* 2008; 17: 188-192.

51

MINIMAL INVASIVE METHODS FOR ANTERIOR APPROACH TO LOWER LUMBAR VERTEBRAE

Senol CARILLI MD, Fahir Ozer MD

1. Introduction

While at the beginning of the last century anterior lumbar interbody fusion (ALIF) was thought to treat Pott's disease years later with a new indication it was depicted for the treatment of spondylolisthesis (1-3). After these early descriptions, anterior lumbar procedures had been started to apply with increasing frequency. Recently, this and other anterior procedures have become a part of daily practice with the addition of further indications such as disc prosthesis.

Disc degeneration is strictly correlated with age and almost half of the population affected with this condition between the ages of 40-60 (4-6). It seems that anterior procedures will continue increasing in practice; they have already become the first-line treatment in certain circumstances.

Rationale of preference of ALIF is shorter operative time, less blood loss, less postoperative pain, shorter hospital stay and faster returning to daily activities than classic posterior approaches. ALIF, also, provides a superior biomechanical reconstruction of the anterior column, better sagittal balance, better restoration of disc interspace height than posterior approach without paraspinous muscle trauma and denervation. All these benefits are enhanced by minimal invasive anterior approaches. Starting from the 1995, the term, minimal invasive anterior vertebral procedures are describing surgeries performed through shorter incisions with very limited dissections and laparoscopic surgeries (7, 8).

2. Indications of minimal invasive surgery

Indications of the minimal invasive ALIF are the same with classical procedures (include spinal deformity, spinal instability, tumors, infection, and chronic disabling low back pain.)

3. Contraindications of minimal invasive surgery

As a relative contraindication of minimal invasive ALIF, an anterior extraperitoneal (ventromedial) approach should not be performed if the patient has had previous major abdominal surgery or spinal surgery around these levels or if the patient is extremely obese. In obese patients retraction of peritoneal sac and the abdominal wall is quite difficult, while in patients with a previous abdominal surgery, dissection of the peritoneum and retraction of the peritoneal sac may cause vascular and organ injuries. Spinal surgery, even performed by posterior approach, may cause stiff adhesions between the vertebrae and the perivertebral tissue which contains major vessels and their dissection may end up with serious bleeding. It is early to evaluate the results of these techniques while they are still in maturation period. Although, at the high volume centers vascular complications reported as low as 1.9%, in most articles there is no exact numbers of complications such as bowel injuries (9). A thorough understanding of anatomical tissue planes and meticulous surgical technique are necessary to prevent serious complications.

4. Surgical procedures

4.a. Anatomical Considerations

For L4-L5 levels either lumbar or various anterior accesses are feasible. Lumbar approach is performed by extraperitoneal route in lateral decubitus position. Anterior approaches can be performed by either transperitoneal or extraperitoneal routes with assorted incisions. Due to iliac crest L5-S1 levels can not be reached comfortably by lumbar incision. Anterior approaches to L5-S1 level and L4-S1 two level surgeries are required anterior incisions, especially for two level interventions median vertical incisions are more practical.

Independent from the incision type and place, in relation to peritoneal sac there are two anterior approaches to lumbar spine; transperitoneal and extraperitoneal. Advantages of anterior extraperitoneal approach are; ease of retraction of intraperitoneal organs with peritoneal sac retraction only, lateral discectomy is easier with this approach; dissection plan is simple and keeps the peritoneal cavity clean from blood, bone and disc fragments, additionally opening and closure times are shorter. Disadvantage of extraperitoneal approach, mainly, is weak control for the contralateral site of the vertebra and the vessels.

Anterior transperitoneal approach carries the advantages of great exposure comfort for neurosurgical procedures and ease of dissection of the great vessels but peritoneal soiling, and intraabdominal organ retraction difficulties are its drawbacks. For anterior transperitoneal approach "open window laparotomy" is a safer technique which carries retraction and undisturbed peritoneal organs advantages of the extraperitoneal method while it brings comfort of midline access and prevailing of to vessels and disc space on both side of the midline ⁽¹⁰⁾.

During dissection at the anterior side of the corpus vertebra it should be remembered that superior hypogastric plexus is situated in front of the last lumbar vertebra and the promontory of the sacrum, between the iliac vessels. Cleavage of this area is carried out by blunt dissection, otherwise electrocautery or traumatic surgery may result in retrograde ejaculation in male patients.

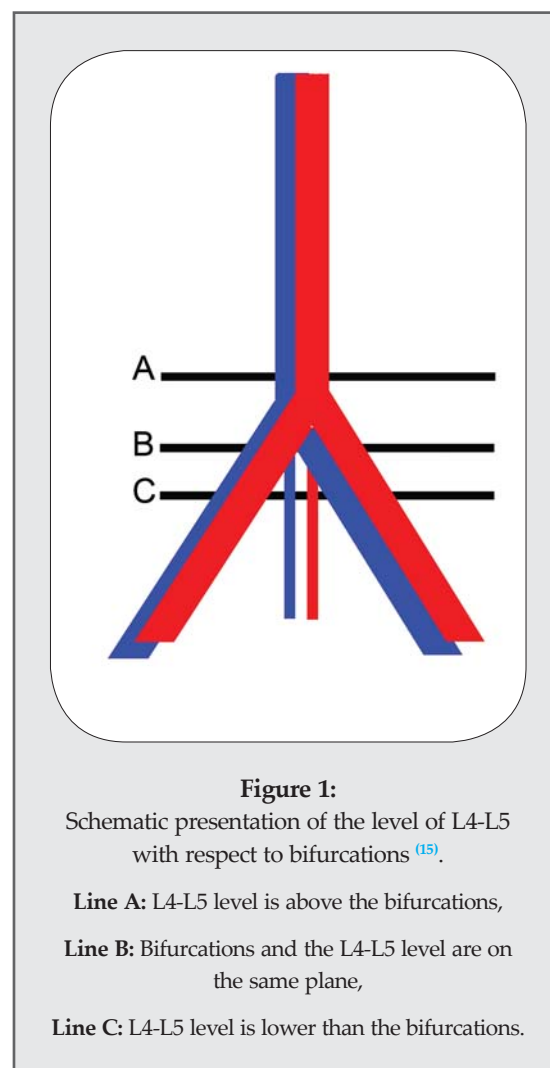
During dissection at the lateral side of the corpus vertebra, segmental spinal arteries are required

a special attention. Segmental spinal arteries should not be violated whenever it is possible. If it is required segmental spinal arteries should be ligated near the aorta rather than near the vertebral foramina to remain local circulation. Segmental spinal arteries should not be ligated on both sides of the same level or on the same side of the adjacent level. Thorough understanding of the anterior vasculature and its relation to lumbosacral spine is necessary for a successful surgery.

4b. L4-L5 access:

According to disc space and vascular structures three main anatomic variations encountered to access the L4-L5 space ⁽¹¹⁻¹⁴⁾.

1- The most common variation is bifurcations are lower than disc (Figure 1 Line A). There are two



options in this situation moving both vena cava and aorta to the right side of disc or moving the aorta to the left and vena cava to the right (Figure 2 A and B). Obviously, the former is easier because limitation of the surgical field with a great vessel on one site is always safer than having one on two sides.

2- The second most common variation, accounts about 30 %, bifurcations are higher than disc (Figure 1 Line C). In this circumstance for safety, at least, both iliac vein and right iliac artery are hanged up (Figure 3).

3- The least common variation is aortic bifurcation is higher and the caval bifurcation is at the same level or lower (Figure 1 Line C). The preferred access is between the left iliac artery and vein (Figure 4). During mobilization of the iliac vein posterior tributaries should be identified to prevent bleeding.

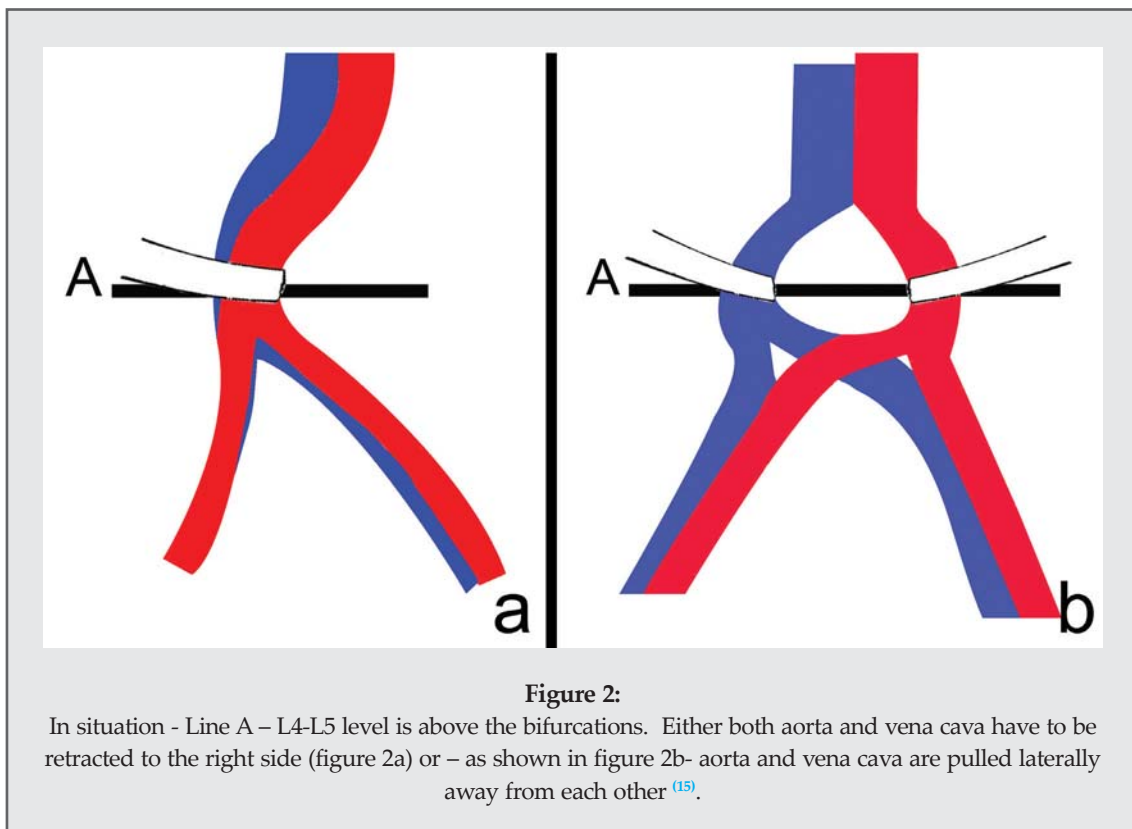
4.c. L5-S1 access:

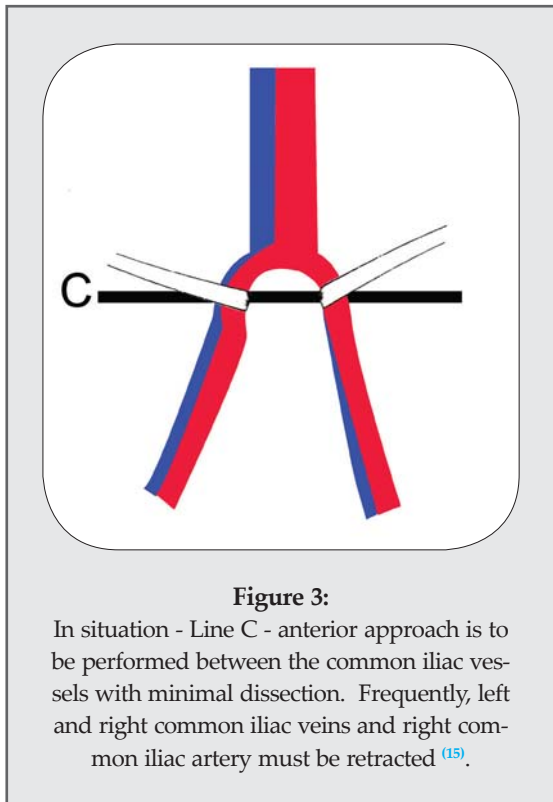
For a safe and sound surgery at this level in majority of patients dissection of the left common iliac vein is sufficient. However, in order to avoid an injury at the interventions below the bifurcation, bifurcation of the vena cava and left iliac vein has

to be dissected and cleared off the surgical field in some cases. Left iliac vein at this level is closer to midline than other vascular structures. The distance between the bifurcation of the vena cava and the L5-S1 disc is about 18mm (7-36mm)⁽¹⁴⁾. The space for approaching this level is restricted by the left common iliac vein and the right common iliac artery, and this distance is on average 33.5mm (12-50 mm). Because of these limited distances it could be necessary to dissect up to the left common iliac vein which crosses to the disc where it is only on average 12mm left of the midline.

For L5-S1 levels in most of the patients this dissection is sufficient to reach the disc space. This is shown in 90% of the patients by Capellades in his MRI based study⁽¹¹⁾. Median sacral vessels are always coagulated before the mobilization of the aortocaval bifurcation and iliac vessels. On the other hand, it should be kept in mind that median sacral vessels are not denoted to midline.

If there is not an adequate amount of space between the iliac vessels for L5-S1 level approach, common iliac veins and arteries should be dissected and hung up with vascular tapes. The com-





mon iliac veins receive the iliolumbar, and sometimes the lateral sacral veins, additionally left iliac receives middle sacral vein. Before pulling away the iliac vein, especially its posterior side should be controlled because of these tributaries. Sometimes suturing or clipping are safer than simple ligation on the iliac vein side.

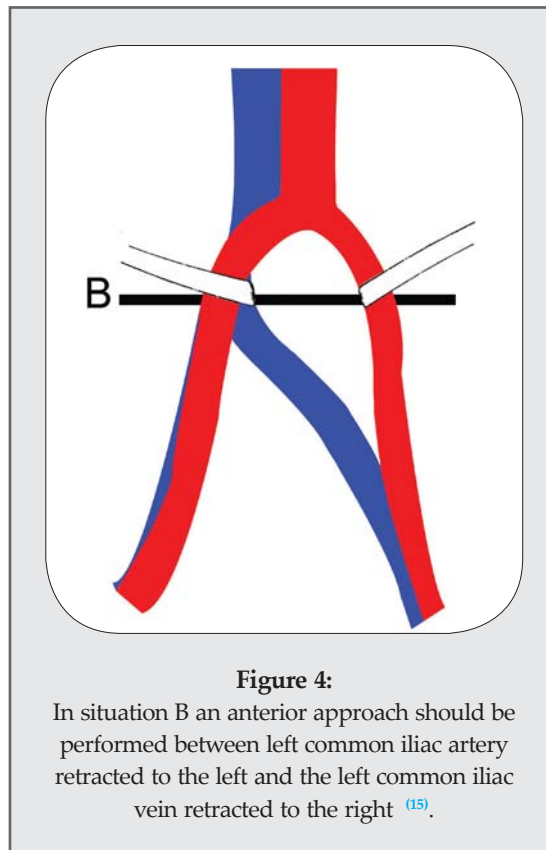
The superior hypogastric plexus, contains the sympathetic function for the urogenital system, is situated in front of the last lumbar vertebra and the promontory of the sacrum, between the iliac vessels. Cleavage of this area is carried out by blunt dissection, electrocautery or traumatic surgery may cause retrograde ejaculation in male patients. Separation of the probable nerve fibers is carried out in a cranio-caudal direction and transverse cuts are avoided in prevertebral tissue. After the dissection is completed and the disc is exposed clearly endoring self retraining device is put in place by three pins and spinal surgery begins.

Some of these challenges are originated from the directions of skin incisions. For a single level disease it is logical to make a transverse incision for extraperitoneal approach which permits well exposition for the left side of the extraperitoneal space while it can

not be mentioned for contralateral side. Also, transverse incisions give better cosmetic results. Vertical midline incision is superior with its extensibility for the two level diseases. For repairing the vascular injuries, vascular surgery instruments are kept ready to use in the operating room. It is helpful to determine the relationship of vessels and disc level before the surgery by CT scan or MRI.

4.d. Ventrolateral Approach to L4-S1

The patient is positioned in supine and there is no need for special arrangement. A horizontal left paramedian skin incision of about 4cm is placed over the disc level, which is determined by C-arm, and 1-2cm lateral to the midline. This incision is suitable for single level interventions. After the opening of anterior rectus sheath, cutting starts from the most lateral part of the muscle by electrocautery. Inferior epigastric vessels and branches should be ligated or coagulated carefully to avoid hematoma. Like skin incision severing of 1-2cm medial part of the muscle is not required. The most lateral part of the posterior sheath is the safest area to avoid to open the peritoneum and to enter preperitoneal



space, because all the fascial layers fuse through the midline, and peritoneum becomes closer to them. After identification of peritoneum lying under the transversalis fascia at the lateral border, the posterior sheath, including fascia transversalis, is cut to 1-2cm to medial part, as done at the skin and at the muscle. After the opening of posterior rectus sheath, finger dissection begins within the preperitoneal tissue that is bordered peritoneum internally and fascia transversalis externally. Through this finger dissection first protrusion is felt at the posterior wall is psoas muscle.

Identification of the ureter is not required while its location is lateral and not close to surgical field. Although identification of ureter is thought as an obligation by many surgeons during the separation of peritoneum from the preperitoneal fat ureter is left in this fatty tissue. During finger dissection, peritoneum cannot be mobilized at the inferolateral corner because of the internal inguinal ring, which serves as the lower border of the dissection. For the cranial side, 5-6cm freeing of peritoneum is sufficient to move the peritoneal sac medially. Medial retraction of the peritoneal sac reveals the great vessels and dissection proceeds under direct visualization. Aorta, vena cava and their bifurcations identified first by bluntly sweeping off the fatty tissue surrounding them. Vessels should be kept away from the field to avoid injury. For the lateral discectomy and disc prosthesis placement extensive anterior dissection is not required. For anterior discectomy or vertebrectomy vessels are dissected and pulled away from the surgical field (Figure 5).

We do not prefer the self retracting retractors for this approach. After the

spinal instrumentation is completed, sutures between the layers are cut and posterior peritoneum is closed by continuous fashion, then anterior wall is closed as a single layer. No drainage is used in the postoperative period. Narcotic analgesics may affect food tolerance otherwise normal diet is given the same day. Early ambulation is recommended.

4.e. Open Window Laparotomy for Approach to L4-S1

Open window laparotomy reduces the risks of vascular and abdominal organ injuries, provides better exposure of the anterior portion of the vertebra and retraction advantages⁽¹⁰⁾. This method is based on the philosophy of protection of the abdominal organs, facilitation of retraction, simplification of the retroperitoneal approach and for direct access to retroperitoneum by anterior access.

A midline approach is also preferred for patients who had previous abdominal, especially pelvic, and patients with relative contraindications for minimal invasive anterior approaches such as for obese patients, for complicated cases such as patients previously operated on these levels either by the posterior or anterior approaches or for recurrent cases. Vascular dissection

in this approach is simpler because dissection of the right iliac vessels is easier than in the extraperitoneal approach performed by transverse left transrectal incision (Figure 6). A 4cm vertical midline skin incision is made over the lesion site where identified by C-arm fluoroscope. For slim patients, palpation of the sacral promontory and incision according to its projection will be adequate. It should be remembered that incision reveals the disc space by right angle.

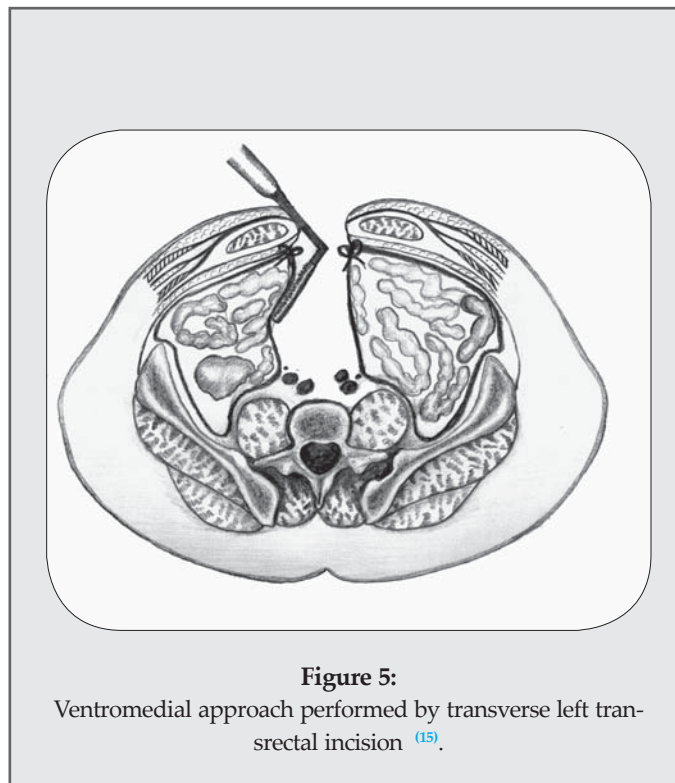


Figure 5: Ventromedial approach performed by transverse left transrectal incision⁽¹⁵⁾.

After the exploration of the peritoneal cavity, small intestine is shifted right and sigmoid colon left. Then, posterior parietal peritoneum is hanged up between the clamps and opened in the same direction with skin but larger, approximately 6-8cm, and peritoneal flaps are freed with finger dissection in each direction. The free lips of the posterior peritoneum are sutured to anterior parietal peritoneum and linea alba with 00 monofilament 8 shaped sutures spaced 1cm apart. An important point is starting to sew from the superior corner then through the inferior corner because injury of intestinal loops is greatest in this site. As its trace is completely out of the surgical field we don't pay special attention to identifying the ureter. After the window is completed, vascular dissection starts. Resuming normal diet may take longer than with extraperitoneal access. But oral fluids can be started at the same day.

4.f. Laparoscopic Lumbar Surgery

Patient is positioned supine, 30 degrees trandelenburg and legs are open. Surgeon works between the legs and the assistant on the one side of the patient. Monitor is on the opposite side beyond the shoulder of the patient (Figure 2 in chapter 5H). Laparoscopic approach can be performed by three 10mm trocars, the suprapubic trocar may be changed with

a larger like 12 or 18mm. First one is placed midline at suprapubic region. It is, essentially, used for 0 degree camera. Other two ports are working trocars and are inserted on both side of the midline, lateral to the inferior epigastric vessels, again between the pubis and umbilicus but more cranial than camera port for easily emptying intervertebral space. Determination of the trocar sites requires laparoscopic experience because all the ports must target the intervertebral space with correct angles. Three 10mm or larger trocars give us flexibility of using them in a changing manner as camera and working ports during operation. Although many surgeons prefer 0 degree camera, we mostly use 45 degrees which gives a better exposure at deep of the intervertebral space.

After the insertion of the first trocar with open technique pneumoperitoneum is accomplished then other two trocars are inserted. Sigmoid colon is pushed to patient's left and small intestines are right upward from the mesentery to reach the peritoneum on the vertebral colon. Trandelenburg position allows to small intestine fall cranial.

First, bifurcations are identified. Ureters are lying laterally than surgical field and generally there is no need to expose them. Peritoneum is cut by a scissors in vertical axis while it is hanged by a grasper to prevent an injury of underlying vessels. After sweep-

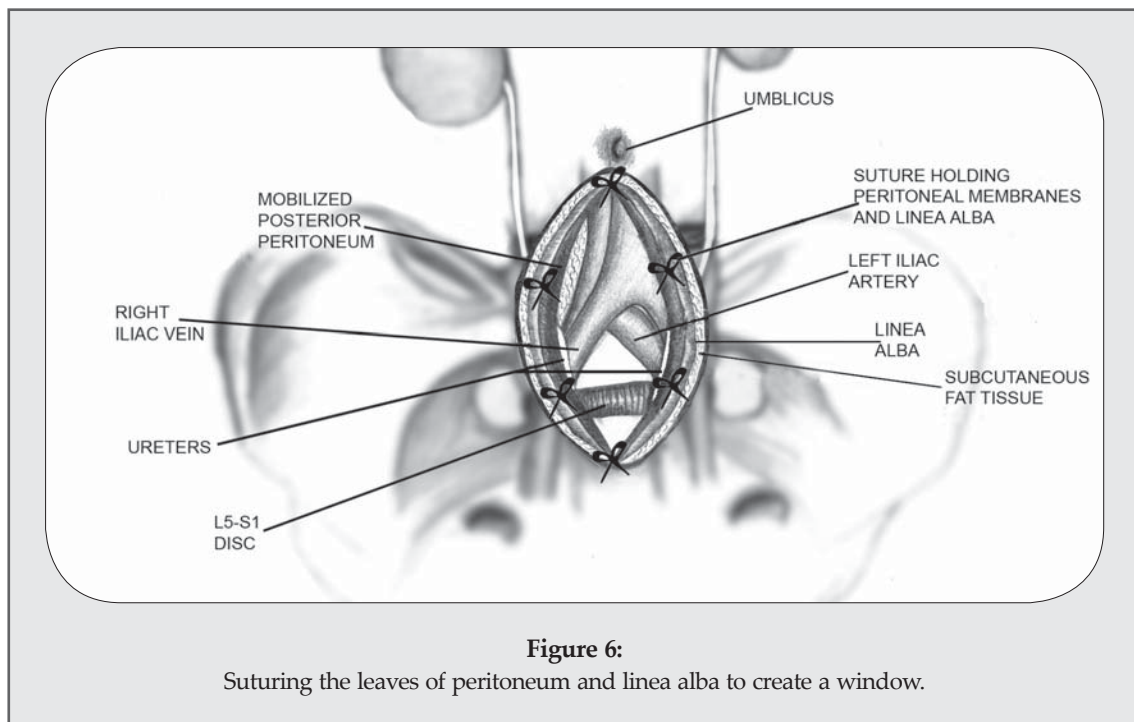


Figure 6:
Suturing the leaves of peritoneum and linea alba to create a window.

ing off the retroperitoneal fat disc and median sacral vessels lying on the anterior surface of the vertebra are identified. Median sacral vessels are isolated and coagulated by a bipolar electrocautery or by clips then cut by a endoscopic scissors. During retroperitoneal dissection sharp dissections and electrocautery usage, especially monopolar electrocautery, may cause retrograde ejaculation due to superior hypogastric plexus injury. There is no extensive vascular mobilization requirement for the L5-S1 level. The only need is to be clearly identified borders of disc and vascular structures.

5. References:

1. Müller W. Transperitoneale Freilegung der Wirbelsäule bei tuberkulöser spondylitis. *Dtsch Z Chir* 1906; 85: 128-35.
2. Ito H, Tsuchiya J, Asami G. A new radical operation for Pott's disease: Report of ten cases. *J Bone Joint Surg* 1934; 16: 499-515.
3. Carpener N. Spondylolisthesis. *Br J Surg* 1932; 19:374-86.
4. Boden SD, Davis DO, Dina TS, Patronas NJ, Wiesel SW. Abnormal magnetic-resonance scans of the lumbar spine in asymptomatic subjects. A prospective investigation. *J Bone Joint Surg Am* 1990; 72(3): 403-8.
5. Benoist M. Natural history of the aging spine. *Eur Spine J* 2003; 12 Suppl 2: 86-9.
6. The Longitudinal Assessment of Imaging and Disability of the Back (LAID Back) Study: Baseline data. *Spine* 2001; 26(10): 1158-66.
7. Zucherman JF, Zdeblick TA, Bailey SA, Mahvi D, Hsu KY, Kohrs D. Instrumented laparoscopic spinal fusion: Preliminary results. *Spine* 1995; 2: 2029-2035.
8. Mayer HM. A new microsurgical technique for minimally invasive anterior lumbar interbody fusion. *Spine* 1997; 22:691-700.
9. Brau SA, Delamarter RB, Schiffman ML, Williams LA, Watkins RG. Vascular injury during anterior lumbar surgery. *Spine J* 2004; 4(4): 409-12.
10. Carilli S, Oktenoglu T, Ozer AF. Open-window laparotomy during a transperitoneal approach to the lower lumbar vertebrae: new method for reducing complications. *Minim Invasive Neurosurg* 2006; 49(4): 227-9.
11. Capellades J, Pellise F, Rovira A, Grive E, Pedraza S, Villanueva C. Magnetic resonance anatomic study of ilio caval junction and left iliac vein positions related to L5-S1 disc. *Spine* 2000; 25(13): 1695-700.
12. Kleeman TJ, Michael Ahn U, Clutterbuck WB, Campbell CJ, Talbot-Kleeman A. Laparoscopic anterior lumbar interbody fusion at L4-L5: an anatomic evaluation and approach classification. *Spine* 2002; 27(13): 1390-5.
13. Regan JJ, Aronoff RJ, Ohnmeiss DD, Sengupta DK. Laparoscopic approach to L4-L5 for interbody fusion using BAK cages: experience in the first 58 cases. *Spine* 1999; 24(20): 2171-4.
14. Tribus CB, Belanger T. The vascular anatomy anterior to the L5-S1 disk space. *Spine* 2001; 26(11): 1205-8.
15. Carilli S, Sasani M, Ozer AF. Pitfalls of the anterior approach to the lumbar vertebrae. *WSJ* 2007; 2(3): 129-133.

5m

LAPAROSCOPIC ANTERIOR LUMBAR FUSION

Kamil Cagri Kose MD, Isador H Lieberman MD

1. Introduction:

In the pursuit of less invasive more effective surgical methods, surgeons devised a laparoscopic access technique to the abdominal cavity. Through this technique, general surgeons, vascular surgeons, urologists and gynecologists evolved from diagnostic procedures to therapeutic procedures. The laparoscopic approaches have now become mainstream in these specialties by virtue of the less invasive approach; faster post treatment recovery and rehabilitation, and less obvious skin scars ⁽¹⁾ (Figure 1). In the mid 1990's spinal surgeons in their attempt to capitalize on these benefits attempted to extend the laparoscopic approach to access the spine. Laparoscopic fusion of the lumbosacral spine was first reported by Mc Afee et al in 1995 ⁽²⁾. New tools and implants were designed and used with varying degrees of success. To date however, the laparoscopic access to the spine has not achieved the same level of acceptance as in other surgical specialties. This is due to the need for specialized expertise and potential for other direct and indirect spine related morbidity associated with the surgery, and further advances in other methods of achieving a more predictable lumbar fusion.

2. Indications:

The indications for laparoscopic anterior fusion are the same as those for traditional open anterior fusions:

- a. Single or two level symptomatic degenerative disks,
- b. Segmental instability,
- c. Grade 1 spondylolisthesis,
- d. Pseudoarthrosis,
- e. Failed posterior lumbar surgery,
- f. Degenerative scoliotic deformity,
- g. Long fusions to the pelvis

3. Contraindications:

The contraindications for laparoscopic anterior fusions (perhaps more important) are:

- a. Extensive peritoneal or retroperitoneal adhesions from previous surgery, radiation therapy or infection.
- b. Intra or retroperitoneal infectious or inflammatory conditions.
- c. Greater than Grade 2 spondylolisthesis.
- d. Overlying psychological conditions
- e. Positive Waddell' sign,
- f. Habitual narcotics users.

4. Surgical Procedures:

4.a. Surgical Equipments:

The required surgical equipments for laparoscopic anterior lumbar fusion are:

- a. Experience with laparoscopic surgery (experienced laparoscopic surgeon)
- b. Laparoscopic equipments (Camera, Monitor, Insufflator, Ports, Laparoscopic instruments, Laparoscopic retractors) (Figure 2a)
- c. Fluoroscopy (To determine the correct level(s) to be fused) (Figure 2b)
- d. Radiolucent operating table.

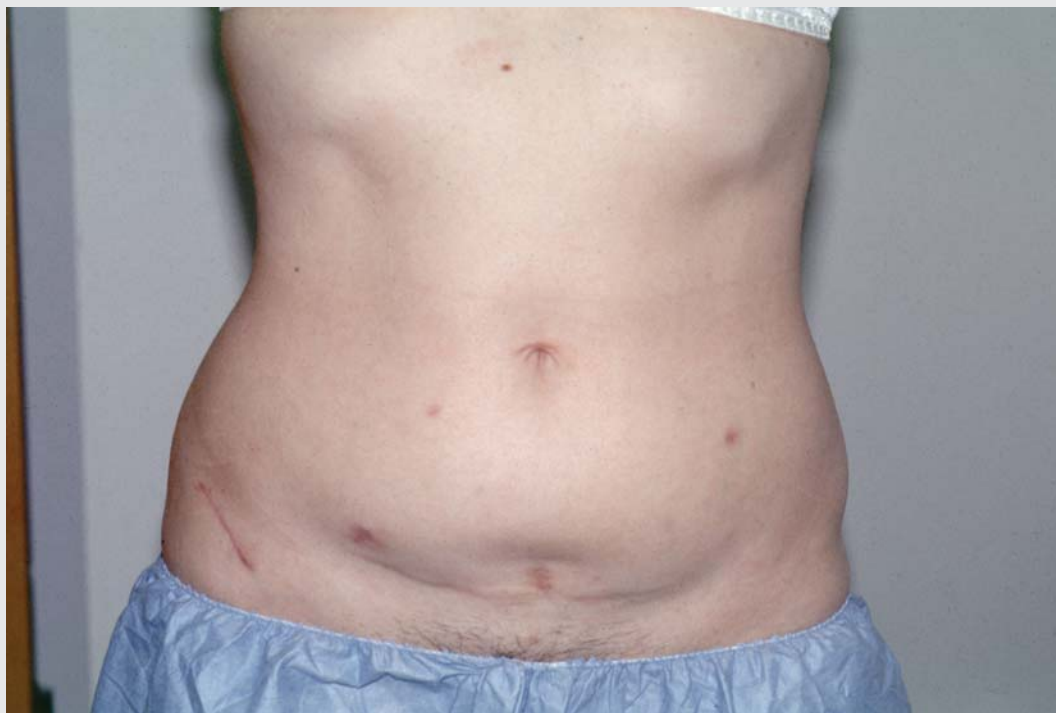


Figure 1:

Laparoscopic procedure is much superior in terms of cosmetic appearance when compared to the traditional open approaches.

4b. Patient Positioning:

With the patient in the supine position on a radiolucent operating table, first the bladder is decompressed by placement of a Foley catheter. The arms can be placed on the thorax of the patient or the patient may be elevated from the table with the use of gel pads or blankets to prevent interference of the arms with the fluoroscopic images. The patient is placed in trendelenburg position (laparoscopic procedures may require up to 30 degrees of trendelenburg position) to facilitate mobilization of the abdominal contents cephalad.

4.c. Surgical Technique:

Multiple portal configurations can be used depending on the instruments, implants and training of the surgeons. Typically at least 4 portals are used;

- a) Periumbilical
- b) Right lower quadrant portal
- c) Left lower quadrant portal
- d) Suprapubic spinal working portal (should be the last portal to be opened) (Figure 3a)

As in any surgical procedure “you can not do what you can not see”, thus an important aspect of any laparoscopic approach is to achieve and ensure satisfactory exposure of the desired surgical area. In addition in males, it is important to avoid excessive manipulation of the retroperitoneal contents or use excessive cautery in the deep pelvic region in order to prevent retrograde ejaculation. Once a good exposure is achieved, (Figure 3b, 3c, 3d) then the fusion procedure follows similar steps to any well done interbody fusion; evacuate the nucleus, debride the cartilaginous endplates to expose the bleeding subchondral bone, provide the osteoinductive, conductive and generic material to provide stability and fusion (Figure 4 a,b,c,d,e,f) Figure 5 a,b,c) (Figure 6 a,b,c).

5. Complications and Avoidance:

Laparoscopic surgery is a less invasive technique; however the risks and potential complications are still significant and essentially similar to any open spinal procedure. The unique complications asso-

ciated with a laparoscopic approach originate from the unique instruments used in this type of surgery like the Veress needle and the trocars. The first trocar or needle is inserted blindly, and can easily cause bowel or vascular injury. In the general surgery literature where laparoscopic surgery is commonly used, vascular injuries including perforation of the aorta and iliac vessels were reported in up to 0.6% of the cases, 10% of them serious. Some fatalities were reported and trocar perforation of a blood vessel is the second most often reported cause of death after anesthesia. Unlike open procedure where vascular injury is immediately recognized, in laparoscopic surgery, vascular injury may not be recognized till the patient is in shock.

A second major life threatening complication associated with laparoscopy and vascular injury is gas embolization. The insufflation gas (CO²) can enter the heart through a defect in the blood vessels. Gas em-

bolism resulting in death and near death incidents was reported. Usually the presentation is immediate and dramatic but may also be noted 30 minutes later when gas enters the portal system. Other injuries such as bowel injuries, some fatal, were reported in 4/1000 cases. These included injuries to stomach, small bowel, colon and spleen. Misplacement of the Veress needle has been reported to cause pneumothorax and or a tension pneumothorax, hypoxemia and hypotension. Gas may also enter the pleural space after trocar injury to the diaphragm or the persistence of a congenital opening through the diaphragm. The reader must note that none of these dreaded complications occurs in the course of open laparotomy where Veress needle, trocars, and gas insufflation are not used.

During laparoscopic surgery, it is important to note that excessive cautery can cause injury to adjacent organs, and even distant organs. In addition,

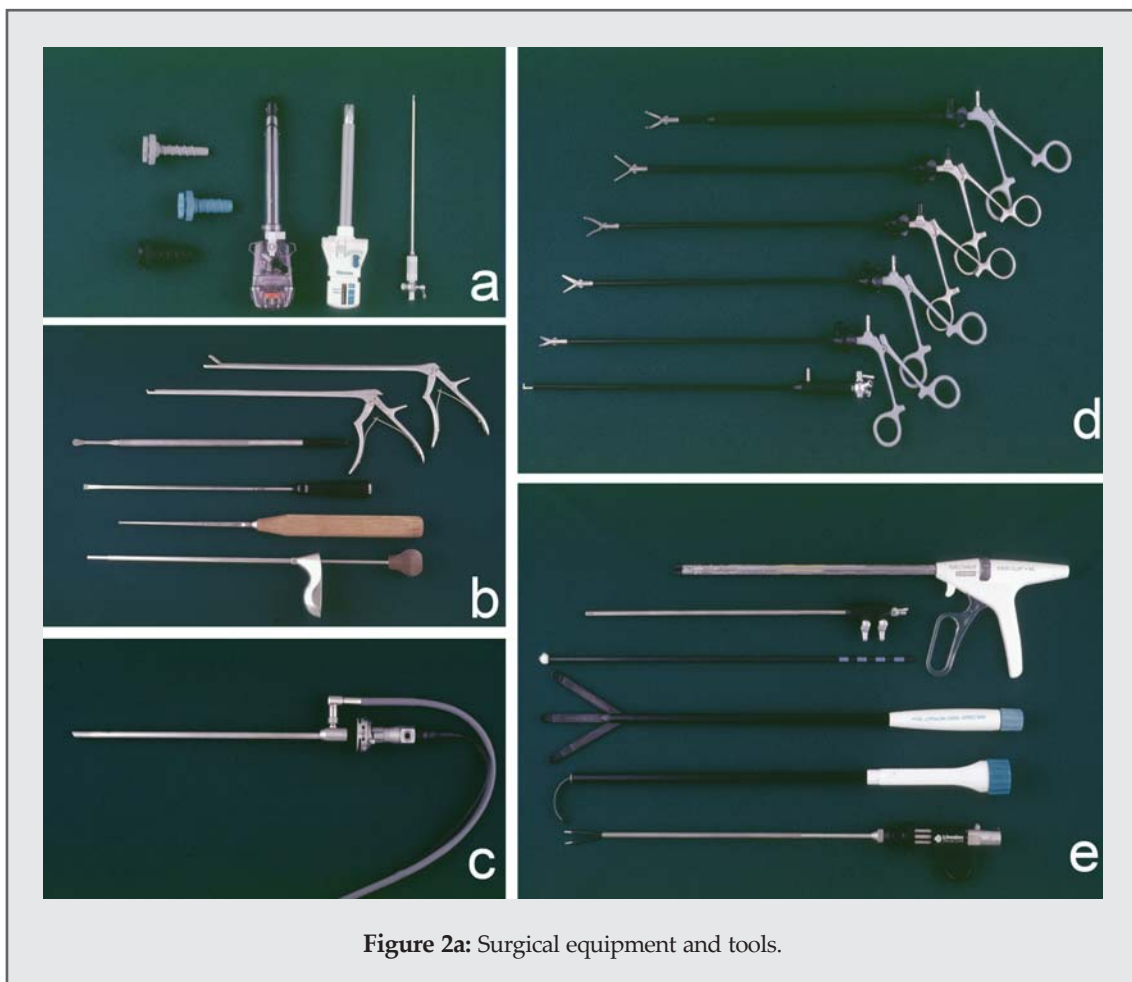


Figure 2a: Surgical equipment and tools.

retrograde ejaculation is found to be higher after laparoscopic ALIF procedures.

In evaluating laparoscopic surgery complications one needs to recall that the technique replaces an open procedure with a published rate of complications between 2 and 4 % for the exposure component of the fusion procedure. Laparoscopic surgery introduces new risks such as trocar injury, cardiovascular problems and damage to bowel and major vessels that are rarely if ever encountered in open fusion procedures.

Several comparative studies showed that at the L5-S1 disc level, there was no marked difference between laparoscopic anterior fusion (ALIF) and the open or mini-open ALIF in terms of short-term efficacy, i.e., operative time, blood loss, and length of hospital stay. With regard to the complication rate, however, there was a higher incidence of retrograde ejaculation in laparoscopic ALIF ^(3,4). At the L4-L5 and L4-L5/L5-S1 disc levels, the complication rate and conversion rate to open surgery was high in laparoscopic ALIF, and many authors were not impressed with this technique at these levels ⁽³⁾.

Many authors initially stated that laparoscopic procedure is associated with higher costs than open procedures ^(5,6). Today however, due to the readily available use of the laparoscopic instruments the costs have stabilized to a more acceptable level. Despite that the trend to laparoscopic fusion procedures has not increased.

6. Postoperative Care:

The postoperative care is similar to any open lumbar fusion surgery. After an uncomplicated procedure, the patient can start a clear liquid diet starting from the postoperative 1st day. Patient can be discharged about 3-4 days after the procedure and the return to work is generally 2-3 months after the operation.

7. References:


1. Lieberman IH, Willshir PC, Salo PT, Litwin DEM, Kraetschmer BG. Transperitoneal Laparoscopic Exposure for Lumbar Interbody Fusion. Spine 2000; 25 (4): 509-14.

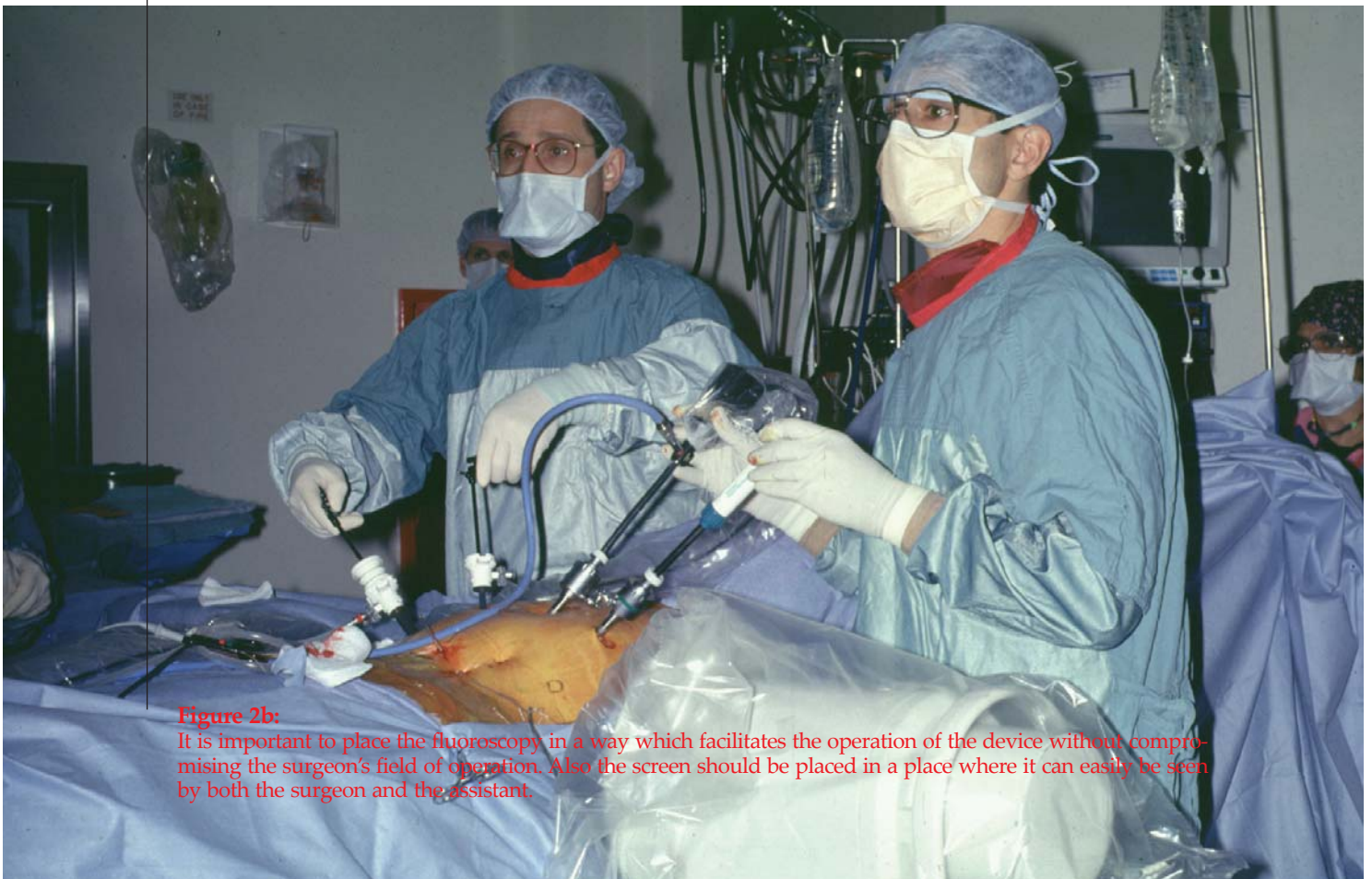

Figure 2b:

It is important to place the fluoroscopy in a way which facilitates the operation of the device without compromising the surgeon's field of operation. Also the screen should be placed in a place where it can easily be seen by both the surgeon and the assistant.

2. McAfee PC, Regan JR, Zdeblick T, Zuckerman J, Picetti GD 3rd, Heim S, Geis WP, Fedder IL. The incidence of complications in endoscopic anterior thoracolumbar spinal reconstructive surgery. A prospective multicenter study comprising the first 100 consecutive cases. *Spine* 1995; 20(14): 1624-32.
3. Inamasu J, Guiot BH. Laparoscopic anterior lumbar interbody fusion: a review of outcome studies. *Minim Invasive Neurosurg* 2005; 48(6): 340-7.
4. Kleeman TJ, Michael Ahn U, Clutterbuck WB, Campbell CJ, Talbot-Kleeman A. Laparoscopic anterior lumbar interbody fusion at L4-L5: an anatomic evaluation and approach classification. *Spine* 2002; 27(13): 1390-5.
5. Rodriguez HE, Connolly MM, Dracopoulos H, Geisler FH, Podbielski FJ. Anterior access to the lumbar spine: Laparoscopic versus open. *Am Surg* 2002; 68(11): 978-83.
6. Chung SK, Lee SH, Lim SR, Kim DY, Jang JS, Nam KS, Lee HY. Comparative study of laparoscopic L5-S1 fusion versus open mini-ALIF, with a minimum 2-year follow-up. *Eur Spine J* 2003; 12(6): 613-7.



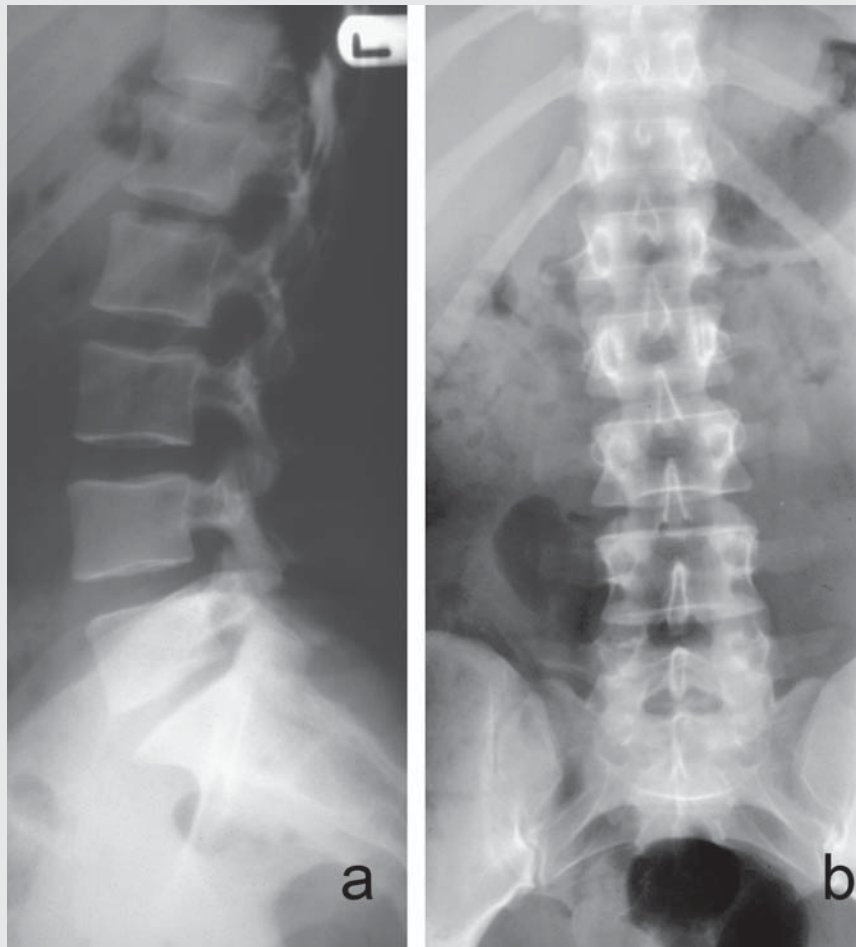
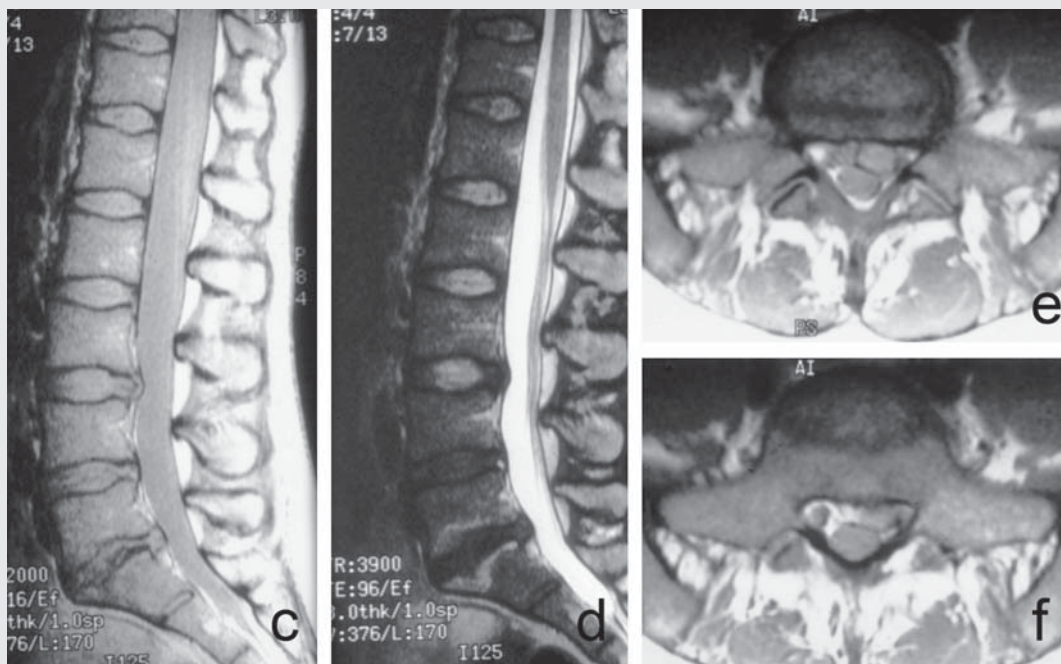


Figure 4:

a,b) The AP and lateral X-rays of a patient with L5-S1 degenerative disc disease.

c,d,e,f) Sagittal and axial MRI images of a patient with L5-S1 degenerative disc disease.



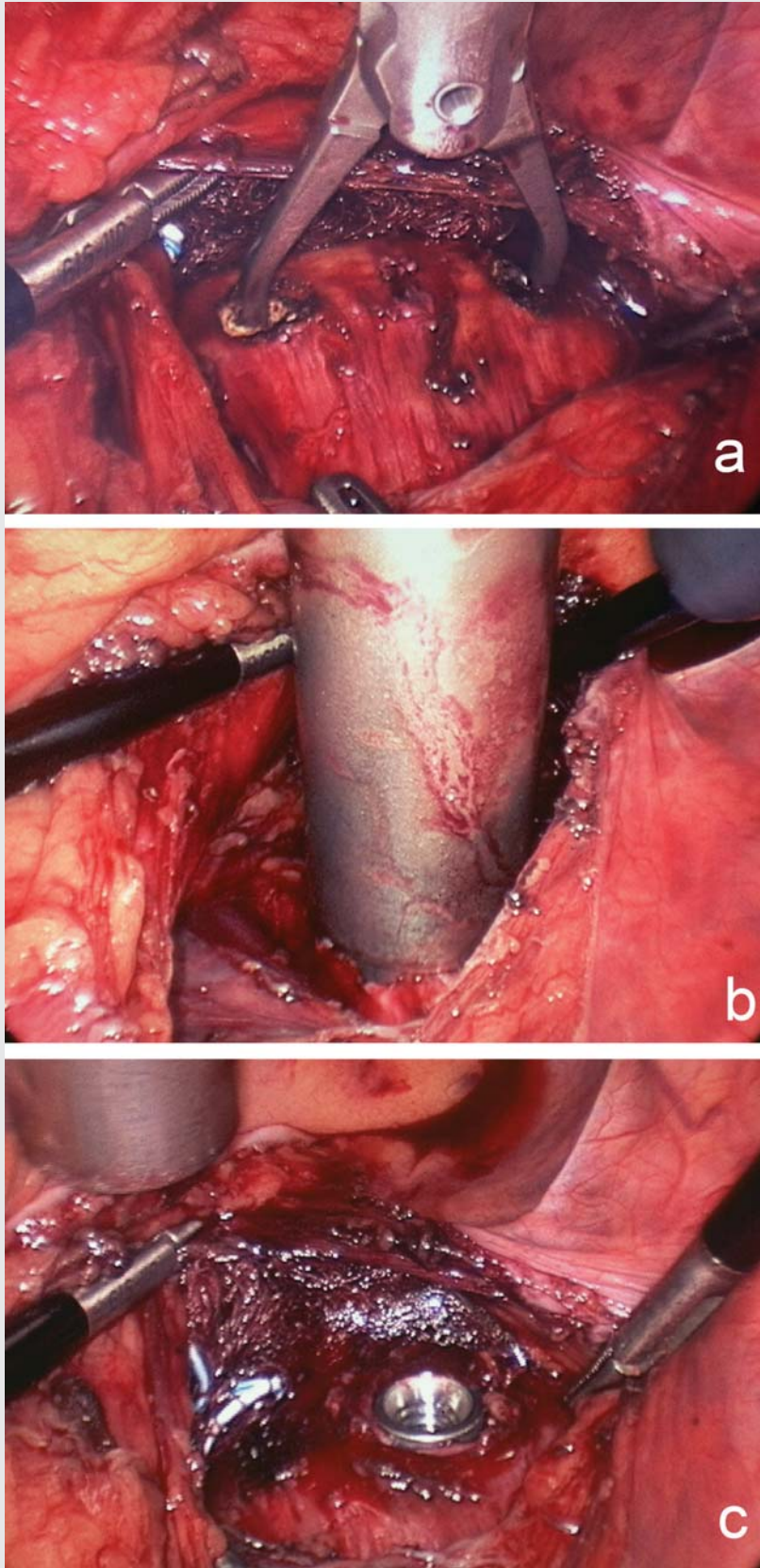


Figure 5:

Intraoperative views showing:

- a)** marking of the disc space,
- b)** placement of the working cannula through which disc space debridement, endplate removal and placement of the interbody fusion materials is carried out,
- c)** final position of the implant.

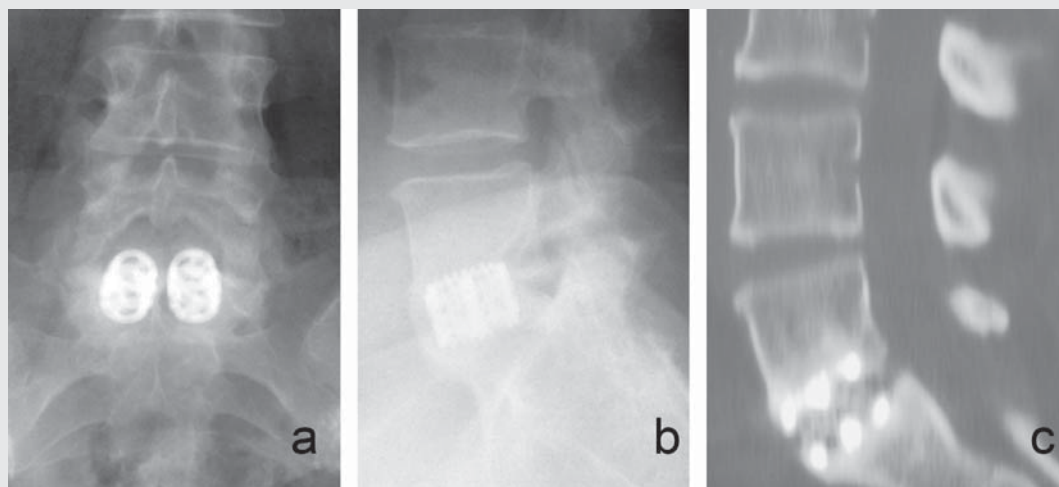


Figure 6:

Postoperative 1 year follow-up views of the same patient

- a) AP X-ray
- b) Lateral X-ray showing fusion mass both in front of and behind the interbody cage,
- c) Sagittal CT image showing solid fusion of both endplates through the interbody cage.

5n

LATERAL LUMBAR MINIMAL INVASIVE APPROACH (XLIF)

Farbod Asgarzadie MD, Larry T Khoo MD, Zachary Smith MD

50

NUCLEUS REPLASMANE OF THE LUMBAR DISCS

Antohny T Yeung MD, Christopher A Yeung MD

5p

MICRO LUMBAR DECOMPRESSION FOR LUMBAR SPINAL STENOSIS

Tuncay Kaner MD, A. Celal Iplikcioglu MD

1. Introduction:

Spinal stenosis was described, for the first time, as one of the causes of neural compression by Bailey and Casamajor ⁽¹⁾ in 1911. Later, in 1954, it was described by Verbiest ⁽²⁾ as the typical clinical presentation of bilateral neurogenic claudication, which is provoked by prolonged standing and lower back extension and relieved by sitting and flexing the lumbar spine. Degenerative lumbar spinal stenosis is a progressive spinal disease which is common in the elderly population and characterized by hypertrophy of the ligamentum flavum, degeneration of the intervertebral disc, and hypertrophy of the facet joint. Traditionally, the treatment of spinal stenosis has been wide laminectomy, which allows decompression of the neural structures by unroofing the spinal canal. The success rate of the procedure is between 62-70% due to postoperative iatrogenic spinal instability. Consequently, the minimally invasive approaches such as partial interspinous laminectomies, modifications of spinous process osteotomies, bilateral laminotomy, and unilateral laminotomy are described.

Young *et al.* ⁽³⁾ described unilateral laminotomy for bilateral micro decompression of lumbar spinal stenosis technique in 1988. Their approach was modified by McCulloch ⁽⁴⁾ in 1991 and described as microsurgical fenestration technique. The main purpose of this minimal invasive surgical technique is to maintain spinal stability by performing enough decompression of dural sack and effected nerve roots. In this surgical technique paraspinous multifidus muscles retract ipsilaterally and muscle structure of the opposite side is protected. Therefore, iatrogenic muscle trauma is kept in a minimal level. Similarly, inter-/supraspinous ligaments are protected; since unilateral

micro decompression is performed in spinal canal facet joints and joint capsule of the opposite side is also protected. As a result, the risk of postoperative iatrogenic segmental instability is minimized. Other advantages of unilateral micro lumbar decompression include a reduced operative time, fewer intraoperative complications, minimal blood loss, short hospitalization and immediate recovery. In conclusion, unilateral micro lumbar decompression gives better surgical results.

2. Patient Selection and Indications:

Cases should be in a clinical table of degenerative lumbar stenosis. Lumbar spinal stenosis patients usually can walk less than 100m without the symptoms of neurogenic claudication and radiculopathy. Single- or multilevel central or lateral stenosis should be confirmed by CT or magnetic resonance imaging (MRI) evidence. Failure of conservative treatment for a minimum of 3 months is necessary for the admission. Such treatments include non-steroid antiinflammatory drugs, steroids, and physiotherapy. Patients should not have instability in their preoperative flexion/extension radiography.

3. Contraindications:

Segmental instability is a major counter indication for unilateral micro lumbar decompression.

4. Surgical Procedures:

4.a. Surgical Equipment:

Intraoperative fluoroscopy (C-handled) machine, operation microscope, high speed drill, monopolar and

bipolar coagulation, microsurgery and laminectomy set is required equipment for this surgery. Additionally, alcohol solution that is required for the sterilization before lumbar spinal surgery, Betadine, drape and sterile towels should be prepared.

4b. Operating Room Set up:

C-handled and operation microscope should be placed opposite of the surgeon. A spinal surgeon would be on the clinical side of the patient in which unilateral micro lumbar decompression would be performed (right or the left side). Surgical assistant and operation technician are opposite of the surgeon. Aspirator should be under the surgeons left hand and high speed drill should be under his right hand (Figure 1a,b).

4.c. Patient positioning:

Prophylactic antibiotics (usually 2 gr cefamesine) are applied to patients 30 minutes before the operation. After intubating the patient, urine catheterization is performed using Foley's sounding-line. Moreover, anti-embolic stocking are worn to patient's both legs extending to inguinal area.

The patient is placed on an operation table in the prone position while under general endotracheal anesthesia. As in standard microdiscectomy position lower back flexion is ensured (Figure 2). In order to release the pressure that could occur on the chest and abdomen, patients both sides (shoulder and in between spina iliaca and anterior superior point) are

supported with silicone pillows. Moreover, areas that could be under pressure in prone position (eyes, axillaries, inguinal and popliteal areas) are carefully controlled. The operational lumbar level of the patient is identified with C-handled. Operative area is cleaned with Betadine solution and just like all other operations' patient covered with a sterile sheet. At this stage patient is ready for the operation.

4.d. Surgical Technique:

The level of spinal stenosis, in a patient who is under general anesthesia and in prone position, is identified under lateral fluoroscopy using a spinal needle. 2-3 cm skin incision is planned approximately 1 cm lateral of the midline on symptomatic side for single level stenosis (Figure 3a). Local anesthetics with epinephrine is injected under the skin in order to help hemostasis. Skin incision is done as planned and standard intervertebral Paraspinous approach is performed with curvilinear paramedian fascia incision. After placing retractor operation is taken into the microscopy field and all the surgical procedures carried out under microsurgery. At this point, ipsilateral interlaminar space is clearly in view. Superior lamina and a part of the facet joints medial side is thinned using high speed drill. The remaining bone is removed by using a 2-mm-diameter Kerrison rongeur. Similarly, but limited laminotomy is performed to inferior lamina. Operative microscope is tilted toward subarticular area, at this point by directing the microscope up to add down ligamen-

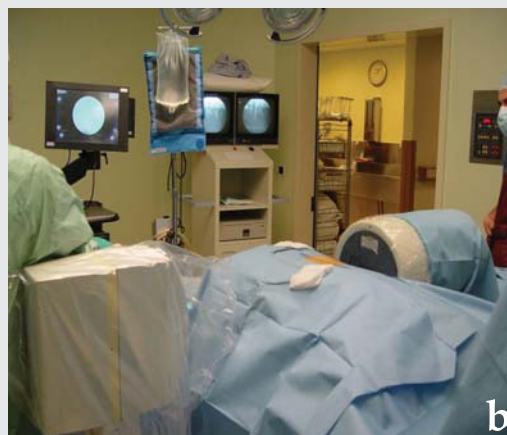
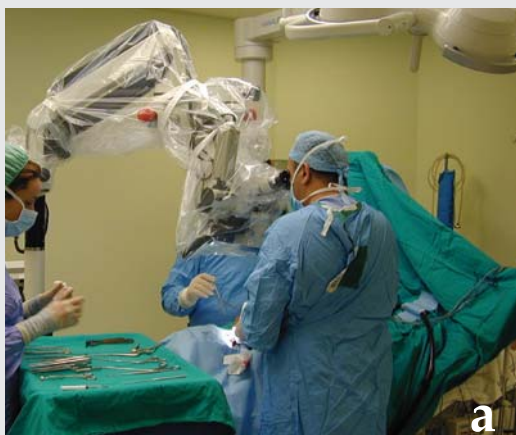
Figure 1a,b:

The general operating room set up and equipment is seen.

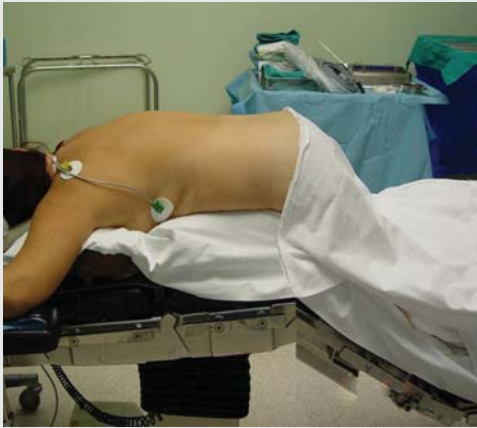

Figure 2:
The patient positioning is seen.

tum flavum, soft tissues, lateral recess, and pathologies that cause stenosis at the bone excised using the Kerrison rongeurs. At this point, as a consequence of removing bone tissues and the ligamentum flavum the dural layer and midline are clearly in view and decompressing the ipsilateral radicular recess allow free nerve root in foramen to be seen. Cephalad and caudal nerve roots in operative area should be clearly visible to the opened interlaminar window. Maximum care should be given to protect pars interarticularis and facet joints during this process. After finishing ipsilateral micro decompression operation continuous in a contralateral side. The operating table is elevated, and the operative microscope is gradually tilted toward the opposite side, patient position is changed if necessary, allow-

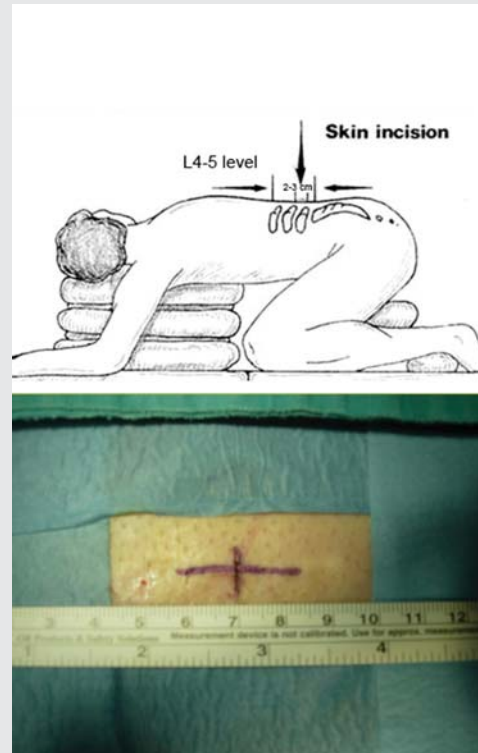


Figure 3a:
The skin incision is seen

ing contralateral ligamentum flavum to be removed using the small Kerrison rongeurs.

Part of the spinous process is further drilled, and the inner portion of the contralateral facet is undercut until the contralateral spinal nerve root and du-

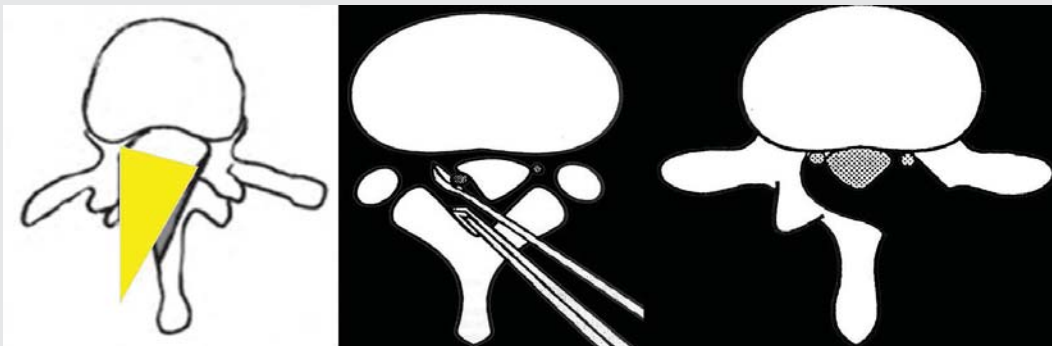


Figure 3b:
Bilateral decompression with unilateral approach is seen schematically.

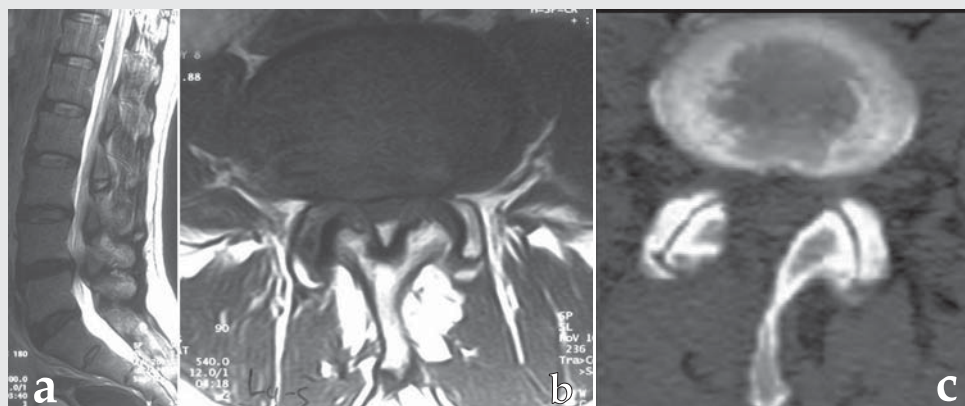


Figure 4:
a,b) The preoperative MRI (axial and sagittal images) is seen,
c) Postoperative decompression area is seen at postoperative axial CT scan.

ral border are visible. After this stage, if necessary, a contralateral foraminotomy can be performed since the contralateral nerve root can be easily identified. If there are tight adhesions to be dural, some small pieces of the ligamentum flavum can be left in place. After the surgery spinal canal should reach the normal sagittal and transversal diameters and all the soft tissue and bone tissue that was causing the stenosis should be resected (Figure 3b). In the closing stage of the operation wound is irrigated and homeostasis maintained. Usually a deep drain is placed and removed in postoperative 12th hour. Operation ends with closing fascia, sub skin tissues and skin respectively.

5. Postoperative Care:

Postoperative hospitalization time is one day. Patient is mobilized in first postoperative day. Patient is released in postoperative day one after nonsteroid antiinflammatory analgesic medications are systematically given. Patient can go back to work in postoperative day 15.

6. Complications and Avoidance:

The complications of this procedure are as follows: dural tears, increased radicular neuro deficit, epidural hematoma, superficial wound infection, and postoperative segmental instability^(5, 6). Intraoperative

complications are more frequent in learning-curve; therefore, such operations should be performed by more experienced surgeons. In this surgical operation more serious complications that increase the morbidity are dural tears and CSF leakage. In order to prevent such complications a clear vision should be achieved under the operative microscope and dural adhesions should be carefully dissected using microsurgical techniques.

If dural wound occurred during the operation it should be fixed primarily when possible, and it should be closed water-tight using tissue adherents. In order to prevent neural tissue wounds it is advised to work gently using thin tipped Kerrison. A good hemostasis should be provided in order to prevent epidural hematoma. Usage of prophylactic antibiotics is important in preventing wound infections. There is a small incidence rate of postoperative segmental instability as a complication. In order to prevent postoperative segmental instability it is very important to protect pars interarticularis and facet joint during bone tissue excision., thus bone excision should be in specified limits^(7,8).

7. Case Illustrations:

A 67 years old male patient was admitted to our neurosurgery department with complaint of leg pain. Patient had been suffering pain and numbness in both legs for two years. However, pain was increased in last two months and pain was more significant in his

right leg. Pain was increasing with prolonged walking and decreasing during relaxation. In his neurological examination neurogenic claudication was identified after walking 50m. In radiological examination (lumbar MRI) advanced spinal narrow canal was identified in L4-L5 level (Figure 4a,b). Since the patient had not responded to previous conservative treatments the operation was advised. Patient was taken into operation and micro lumbar decompression with right unilateral approach was performed. (Figure 4c). Patient was released from the hospital in postoperative day 2.

7. References:

1. Bailey P, Casamajor L. Osteoarthritis of the spine as a cause of compression of the spinal cord and its roots. *J Nerv Ment Dis* 1911; 38: 588-609.
2. Verbiest H. A radicular syndrome from developmental narrowing of the lumbar vertebral canal. *J Bone Joint Surg Br* 1954; 36: 230-7.
3. Young S, Veerapen R, O'Laoire SA. Relief of lumbar canal stenosis using multilevel subarticular fenestrations as an alternative to wide laminectomy. *Neurosurgery* 1988; 23: 628-633.
4. McCulloch JA. Microsurgical spinal laminotomies, in Frymoyer JW(ed): *The Adult Spine: Principles and practice*. New York: Raven Press, Ltd,1991, pp1821-1831.
5. Costa F, Sassi M, Cardia A, et al. Degenerative lumbar spinal stenosis : analysis of results in a series of 374 patients treated with unilateral laminotomy for bilateral microdecompression. *J Neurosurgery Spine* 2007; 7(6): 579-86.
6. Thome C, Zevgaridis D, Leheta O, et al. Ourcome after less-invasive decompression of lumbar spinal stenosis:a randomized comparison of unilateral laminotomy, bilateral laminotomy, and laminectomy. *J Neurosurg Spine* 2005; 3: 129-141.
7. Ivanov AA, Faizan A, Ebraheim NA, Yeasting R, Goel VK. The Effect of Removing the Lateral Part of the Pars Interarticularis on Stress Distribution at the Neural Arch in Lumbar Foraminal Micro decompression at L3-L4 and L4-L5, Anatomic and Finite Element Investigations. *Spine* 2007; 32(22): 2462-6.
8. Adams MD, Hutton WC. The mechanical function of the lumbar apophyseal joints. *Spine* 1983; 8: 327-330.