

# POSTEROLATERAL SELECTIVE ENDOSCOPIC DISCECTOMY THE YESS TECHNIQUE

*Anthony T. Yeung M.D., Christopher A. Yeung M.D., Yinggang Zheng M.D.*

## 1. Introduction

The intervertebral disc, an important supporting structure of the spinal column, is implicated as a major source of low back pain and sciatica. <sup>(1,2)</sup> The pathogenesis of disc degeneration and herniation is complex and multifactorial, but clearly outlined and documented by Wolfgang Rauschnig's work illustrating the patho-anatomy of degenerative disc disease and degenerative conditions of the lumbar spine. <sup>(3)</sup> Most disc herniations are not the result of an acute event, but an accumulation of several insults to the spine that lead to degeneration, annular tears, and eventual disc herniation. <sup>(4)</sup> There are several theories of disc degeneration including mechanical, chemical, age-related, autoimmune and genetic. Within the mechanical theory, the following types of abnormal loads have been proven experimentally to cause disc injury: torsion <sup>(5)</sup>, compression <sup>(5,6)</sup>, repetitive compressive loading in flexion <sup>(7)</sup>, hyper flexion <sup>(8)</sup>, and vibration. <sup>(9)</sup>

Traditionally disc surgery has been reserved for disc herniations causing radiculopathy or nerve deficits due to mechanical compression on the spinal nerves. <sup>(10)</sup> This is due to the inherent morbidity of the posterior surgical approach that must violate and alter the important function of the posterior spinal column. Open posterior discectomy often includes or requires a midline incision, muscle and ligament stripping, prolonged muscle retraction, bone resection of the lamina and facet, and nerve root and dural tube retraction. This can cause instability and scarring around the sensitive nerve roots even in a technically perfect operation. The morbidity of the standard posterior approach has therefore limited the use of surgery as an early treatment option in the cascade of disc degeneration and herniation. Thus,

surgery was often not recommended for herniations without neurologic deficits, "small" herniations, central herniations, and annular tears. The dogma that "disc surgery is really decompressive nerve surgery" dominates the rationale for traditional micro-discectomy for herniated discs.

Minimally invasive surgical options that limit the inherent approach related-morbidity are possible with the posterolateral portal. <sup>(11-28)</sup> This approach to the disc is most challenging at the L5-S1 level due to the prominence of the iliac crest. Most L5-S1 disc spaces are accessible; however, entry into the disc may require foraminal decompression of the lateral facet.

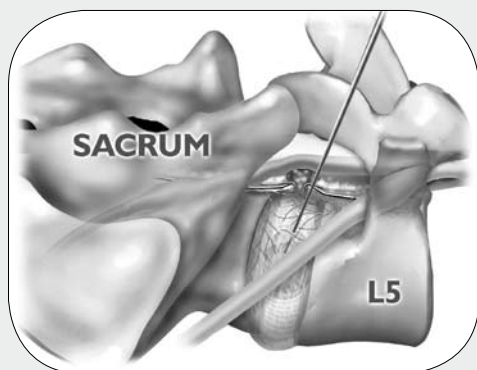
The least invasive of all posterolateral intradiscal techniques is the injection of Chymopapain, a treatment option validated by at least two large prospective, randomized double blind studies and numerous cohort studies. <sup>(29,30)</sup> This treatment produced satisfactory results in many studies and came into widespread clinical use in the 1970's, but lost popularity with reports of complications as severe as anaphylactic shock and transverse myelitis. <sup>(31)</sup> Although these complications can now be virtually eliminated with pre-operative antigen screening and discography, the perceived risk has limited its continued use. More recent studies from experienced chymopapain users still tout chymopapain as a valuable adjunct to endoscopic disc surgery. <sup>(32,33,34)</sup>

The introduction of the operating microscope for discectomy by Yasargil in 1967 and later by Williams encouraged smaller incisions for the standard posterior approach. <sup>(35,36)</sup> The transcanal microscope-assisted technique became the gold standard; however, it still requires retraction of the dural tube and nerve, periosteal stripping of the muscle and ligaments, hemi-

laminotomy, and regional or general anesthesia. Tubular retractors have recently been developed that can be used with either a microscope or endoscope for this posterior transcanal approach.<sup>(37)</sup> This utilizes tissue dilation rather than cutting, and minimizes the superficial tissue destruction, but still requires the same amount of bone removal and neural manipulation as the standard microscopic posterior discectomy.

The concept of indirect decompression of the spinal canal via a posterolateral, extracanal approach was introduced by Kambin in 1973 using a Craig cannula for limited nucleotomy in combination with a transcanal approach.<sup>(14)</sup> In 1975 Hijikata reported the first stand alone nonvisualized posterolateral percutaneous central nucleotomy.<sup>(9)</sup>

Kambin went on to describe the safe triangular working zone (Kambin's Triangle) (Figure 1) and results of arthroscopic microdiscectomy, in which arthroscopic visualization of the herniation via the posterolateral approach was used for discectomy of contained herniations.<sup>(11, 14-19)</sup> Hermantin et al. reported satisfactory results from video assisted arthroscopic microdiscectomy in 97% of patients compared to 93% in traditional microdiscectomy with an average of 31 months follow-up.<sup>(11)</sup> The arthroscopic group had less narcotic use and less time off from work. The study was prospective and randomized with 30 subjects in each group.



**Figure 1:**

Kambin's triangular working zone is the site of surgical access for posterolateral endoscopic discectomy. It is defined as a right triangle over the dorsolateral disc. The hypotenuse is the exiting nerve root, the base (width) is the superior border of the caudal vertebra, and the height is the dura/traversing nerve root.

Mayer also showed promising results in a prospective randomized study comparing percutaneous discectomy with microscopic discectomy for contained or slight subligamentous herniations.<sup>(21)</sup> The percutaneous group showed comparable or superior results. Long term disability defined by return to work status, produced statistically significant differences. In the percutaneous group, 95% returned to their previous occupation compared to 72.2% in the microdiscectomy group. Each group had 20 subjects.

Evolving methodology the 1980's and early 1990's allowed for endoscopic lumbar nerve root decompression by a visualized, direct excision of contained and non-contained herniated disc fragments.<sup>(19,20,25,28)</sup>

Yeung introduced a rigid rod-lens, flow integrated, multichannel, wide-angle operating spinal endoscope in 1998 that allowed for even more flexibility accessing the disc, traversing and exiting nerve roots, and epidural space. The endoscope configuration offered significant visual improvement and the complementary instrument system with specialized slotted and bevel-ended tubular access cannulas allowed for same-field viewing of the intradiscal space, annular wall, and epidural space. The design allows for improved access to the posterior disc for visualized fragmentectomy, improved access to the undersurface of the superior articular facet for foraminoplasty, and protection of the neural structures by rotating the cannula.<sup>(26,27)</sup>

## 2. Indications and Treatment Rational

- All lumbar disc herniations except migrated/sequestered fragments inaccessible through the foramen
- Annular tears
- IDD-Internal disc disruption diagnosed with discography producing concordant pain and radiographic abnormalities
- Foraminal stenosis
- Synovial cysts of the facet joint
- Discitis

Perhaps the ideal lesion for posterolateral selective endoscopic discectomy is the far lateral, extraforaminal disc herniation. The exiting nerve is routinely visualized, and the cannula inserts directly at the herniation site. This approach requires less ma-

nipulation of the exiting nerve root than the paramedian posterior approach.

Any herniation contiguous with the disc space not sequestered and migrated is amenable to endoscopic disc excision. The timing of surgical treatment is similar to posterior transcanal discectomy. The size and types of herniations chosen by the surgeon for endoscopic excision will depend on the skill and experience of the surgeon as well as the anatomic considerations in the patient relative to the location of the herniation. Certainly, all contained disc herniations are appropriate for endoscopic decompression. With experience extruded herniations can be routinely addressed.

The posterolateral endoscopic approach only requires tissue dilation to accommodate a 7mm working cannula. This tissue sparing approach offers consideration for earlier surgical timing when approach related risk/benefit ratios are factored in after patients fail conservative treatment and continue to have debilitating pain without neurologic deficit. Quality of life issues and functional issues associated with chronic discogenic pain can be addressed with this minimally invasive surgical option. Therefore, small disc herniations with predominant leg pain, central disc herniations with predominant back pain, IDD, and annular tears causing chemical sciatica are amenable to disc surgery by endoscopic means.

The discectomy decompresses the disc, alleviating pressure on the annulus, and removes any unstable degenerated disc fragments that could herniate. Radiofrequency energy can be applied to the annular tears under direct visualization to contract the collagen and ablate ingrown granulation tissue, neoangiogenesis, and sensitized nociceptors. Frequently interpositional nuclear tissue is seen within the fibers of the annular tear preventing the tear from healing. This tissue can then be removed to allow the tear to heal.

Endoscopic foraminoplasty can be readily achieved with bone trephines/rasps and the side firing Holmium-YAG laser.<sup>(38)</sup> The roof of the foramen is formed by the undersurface of the superior articular facet. This is easily visualized and accessed via the endoscope. The side firing Holmium-YAG laser and bone trephines strip the facet capsule and remove bone to enlarge the foraminal opening. Studies by Panjabi have demonstrated that decompression through the foramen can be more effective than posterior decompression for foraminal stenosis. The posterior removal of

1/3 of the medial facet produces more instability than posterolateral foraminal decompression.<sup>(39)</sup> Synovial cysts can also be visualized and removed.

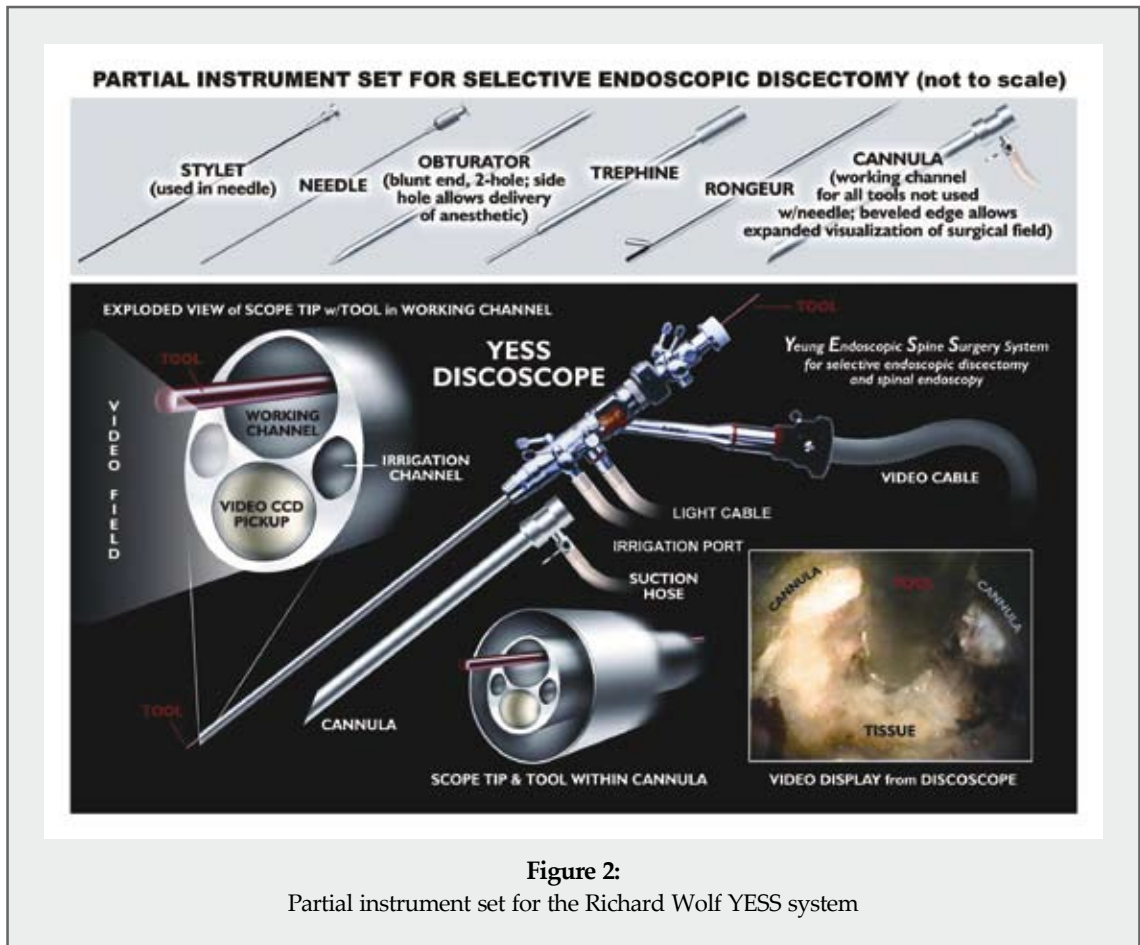
Discitis can be treated with posterolateral endoscopic discectomy and debridement. Current methods rely on needle aspiration followed by prolonged antibiotic treatment. Needle aspirations are not as reliable as tissue samples from endoscopic debridement, and are often negative even in the face of bacterial discitis. Surgeons are often hesitant to perform open debridement because of the morbidity of the open approach, creation of dead space and devascularized tissue, and the concern for spreading the infection in the spinal canal. Endoscopic excisional biopsy and thorough debridement via the posterolateral portal has provided almost immediate pain relief and a much more reliable tissue sample for laboratory analysis and culture.<sup>(40)</sup> Since only tissue dilation is used, no dead space is created that would allow the infection to spread. Many patients with discitis have co-morbidities, which make them poor open surgical candidates.

## 3. Surgical Procedures

### 3.a. Surgical Equipment

The Yeung Endoscopic Spine Surgery System (Richard Wolf) consists of the following instruments. (Figure 2)

- Multichannel, 20° oval spinal endoscope with 2.7mm working channel and integrated continuous irrigation (inflow and outflow) ports
- Multichannel, 70° oval spinal endoscope
- 7mm working cannulas with various open slotted, beveled, and tapered ends
- 2 channel tissue dilator/obturator
- Specialized single and double action rongeurs for visualized fragmentectomy
- Larger straight and hinged rongeurs for discectomy and targeted fragmentectomy
- Trephines for annulotomy and foraminoplasty
- Micro rasps, curettes, and penfield probes
- Annulotomy knife
- Flexible bipolar radiofrequency probe for hemostasis, thermal contraction of the annular collagen, and thermal ablation of the annular nociceptors (Ellman trigger-flex bipolar probe)



**Figure 2:**  
Partial instrument set for the Richard Wolf YESS system

#### Adjunctive equipment

- Straight and flexible suction-irrigation shavers for discectomy (Endius MDS)
- Side firing Holmium-YAG laser (Trimedyne)
- Fluid pump for continuous irrigation
- Video endoscopy tower

#### 3.b. OR Set up

Proper OR setup requires a radiolucent table with a hyperkyphotic frame, one C-arm, and a tower with the usual monitor for endoscopic viewing. Ideally the operating suite will be equipped to record the procedure including fluoroscopic images onto video and/or still images. Foot pedals controlling the radiofrequency probe, shaver, suction, C-arm, and laser should be ergonomically arranged. Required personnel include the anesthesiologist, scrub tech, circulator, C-arm technician and a surgical assistant if a biportal approach is planned. (Figure 3)

#### 3.c. Patient Positioning

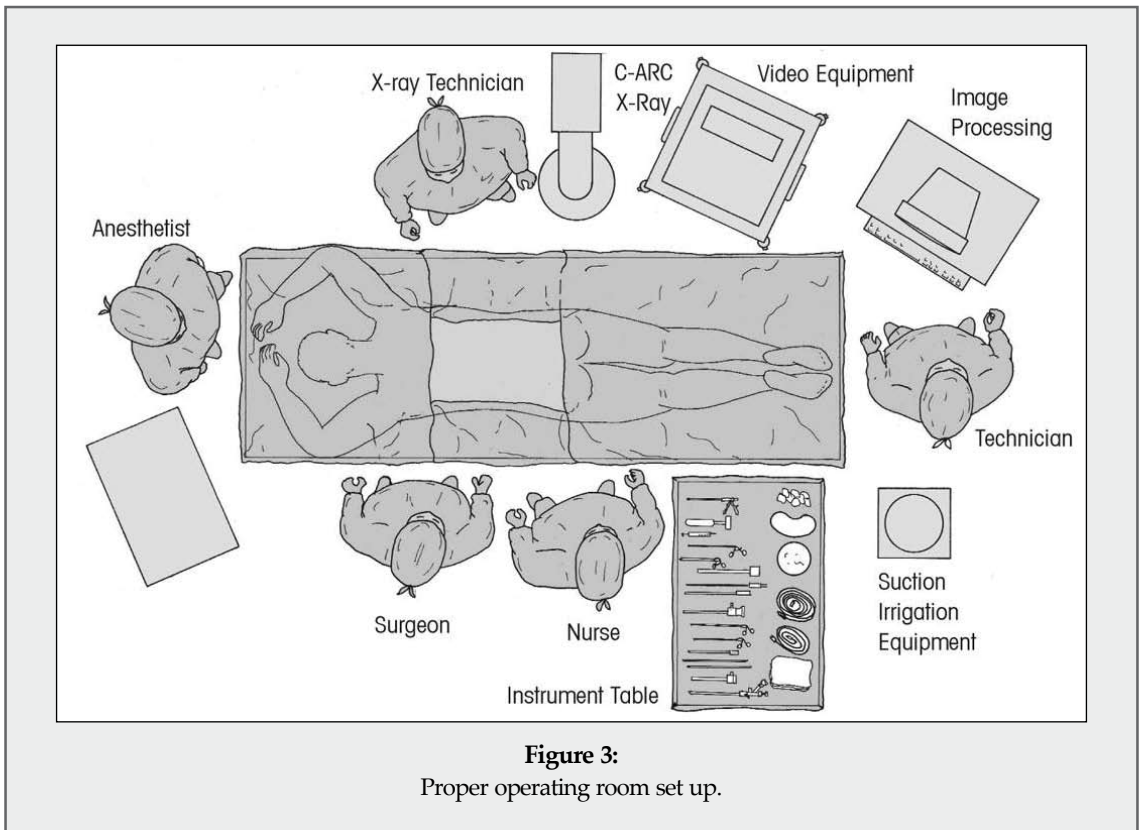
The patient is placed prone on the radiolucent hyperkyphotic frame (Kambin frame, US Surgical) with the arms away from the side of the body. Care is taken to line up the patient with the C-arm to ensure a perfect posterior-anterior and lateral view on the fluoroscopy. The spinous processes should be centered between the pedicles on the PA view and the endplates parallel on the lateral view. The surgical level must be centered to avoid parallax error. Anesthesia consists of ½ percent local lidocaine infiltration, supplemented by versed and fentanyl for conscious sedation.

#### 3.d. Step-by-Step Surgical Techniques with Relevant Surgical Anatomy

##### 3.d.1. Protocol for Optimal Needle Placement

Utilizing a thin metal rod as a radio-opaque marker and ruler, lines are drawn on the skin to mark surface topography for guidance in free hand biplane





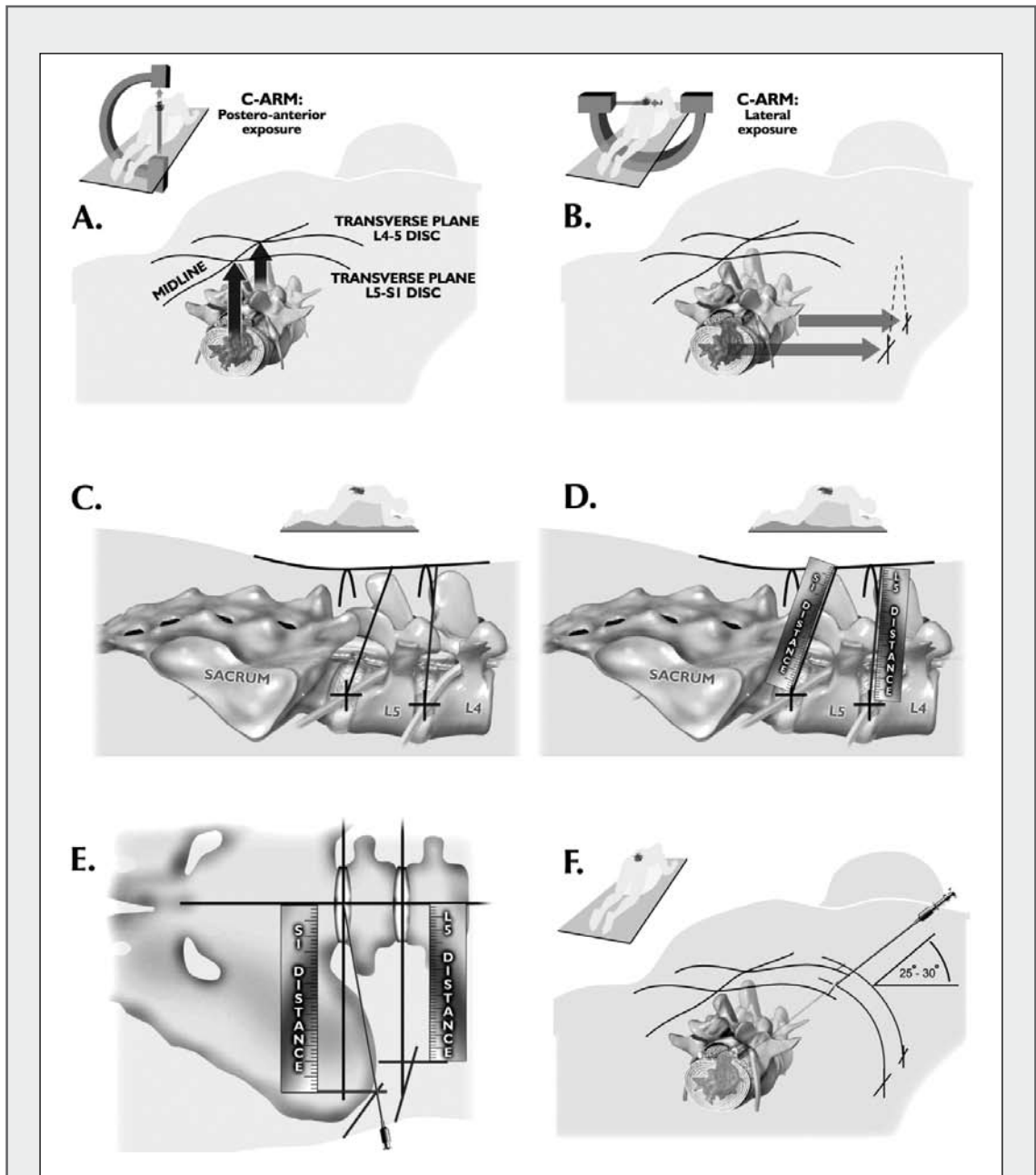
**Figure 3:**  
Proper operating room set up.

C-arm needle placement. These surface markings help identify three key landmarks for needle placement: the anatomic disc center, the annular foraminal window (centered within the medial and lateral borders of the pedicles), and the skin window (needle entry point). (Figure 4)

- Utilizing a metal rod as radio-opaque marker and ruler, draw a longitudinal line over the spinous processes to mark the midline on the PA view.
- Draw a transverse line bisecting the targeted disc space to mark the transverse disc plane on the PA view. The intersection of these 2 lines marks the anatomic disc center.
- On the lateral view draw the disc inclination plane from the lateral disc center to the posterior skin. This line should bisect the disc and be parallel to the endplates. This line determines the cephalad/caudal position of the needle entry point. When drawing this disc inclination line, the tip of the metal rod should be at the lateral anatomic disc center. The distance from the rod tip to the plane of the posterior skin is measured by grasping the rod at the point where the posterior skin plane intersects it.

- This distance is then measured on the posterior skin from the midline along the transverse plane line.
- At the lateral extent of this measurement a line parallel to the midline is drawn to intersect the disc inclination plane line. This intersection marks the skin entry point or skin window for the needle.

The skin window's lateral location from the midline determines the trajectory angle into the foraminal annular window. Utilizing the above method, a 45 degree trajectory to the disc should place the needle tip in the true anatomic disc center. Since most of the pathology being treated is located posteriorly, placement in the posterior one third of the disc is optimal. Thus one needs to "fudge" 1-2 cm laterally for the optimal skin window placement to access the posterior one third of the disc. This allows one to avoid the facet joint with a shallower needle trajectory (about 30 degrees in the coronal plane) to the disc. Alternatively one can place the rod tip at the anterior portion of the disc when measuring the disc inclination plane. This produces a longer measurement to the posterior skin plane, thus placing the



**Figure 4:**

Protocol for optimal needle placement. A. PA fluoroscopic view enables topographic location of the midline and the transverse disc plane. The intersection of these lines is the PA anatomic disc center. B. Lateral fluoroscopic view enables topographic location of the disc inclination plane. C. The inclination plane of each target disc is drawn on the skin from the lateral disc center. D. The distance from the lateral disc center to the posterior skin plane is measured along the inclination plane. E, F. This same distance is measured from the midline along the transverse disc plane for each target disc. At the end of this measure a line parallel to the midline is drawn to intersect the disc inclination line. This is the skin entry point or "skin window" for the needle.

skin window more lateral. This is actually the preferred method. This coordinate system of finding the optimal anatomical landmarks for instrument placement will help decrease the steep learning curve for needle placement and eliminate the less accurate “down the tunnel” method favored by radiologists and pain management physicians.

The positive disc inclination plane of the L5-S1 disc is noteworthy. A steep positive inclination line (lordosis) will position the optimal skin window more cephalad from the transverse plane line, avoiding the “high iliac crest”. A flatly inclined L5-S1 disc will position the optimal skin window with the iliac crest obstructing the trajectory of the needle. The skin window will have to start more medial to avoid the iliac crest, and sometimes the lateral  $\frac{1}{4}$  of the facet joint must be resected to allow for posterior needle placement in the disc.

The first neutrally aligned disc inclination plane is usually at L4-L5 or L3-L4. A neutrally aligned disc inclination plane is in the same plane as the transverse plane line, thus the skin window is in line with the transverse plane line. A negatively inclined disc, often at L1-L2 and L2-L3, places the skin window caudal to the transverse plane line.

### 3.d.2. Needle Placement

Infiltrate the skin window and subcutaneous tissue with one half percent lidocaine. Insert a six inch long, 18 gauge needle from the skin window at a 25-30 degree angle from the coronal plane (reciprocal of 60-65 degrees from the parasagittal plane), anteromedially toward the anatomic disc center. Infiltrate the needle tract with one half percent lidocaine as you are advancing the needle. The superficial portion of the needle trajectory is usually outside of the c-arm viewing perimeter. Once the needle tip is visible within c-arm viewing perimeter, tilt the c-arm, beam parallel to the disc inclination plane, the Ferguson view. Advance the needle toward the target foraminal annular window. If minor directional adjustments are necessary, use the plane of the needle bevel and hub pressure to navigate. At the first bony resistance or before the needle tip is advanced medial to the pedicle, turn the c-arm to the lateral projection. Do not advance the needle tip medial to the pedicle during the initial approach. Doing so risks inadvertent traversing nerve root and dural puncture.

Most frequently the first bony resistance encountered is the lateral facet. Increase the trajectory angle

to aim ventral to the facet and continue the approach toward the foraminal annular window. Turning the needle bevel to face dorsal helps the needle tip skive off the undersurface of the facet. The c-arm lateral projection should confirm the needle tip’s correct annular location. In the lateral view the correct needle tip position should be just touching the posterior annulus surface. In the postero-anterior view the needle tip should be centered in the foraminal annular window. The above two views of the c-arm confirm that the needle tip has engaged, the safe zone, the center of the foraminal annular window.

While monitoring the postero-anterior view, advance the needle tip through the annulus to the midline (anatomic disc center). Then check the lateral view. If the needle tip is in the center of the disc on the lateral view you have a central needle placement, which is good for a central nucleotomy. Ideally the needle tip will be in the posterior one third of the disc indicating posterior needle placement. This is ideal for accessing the herniations.

### 3.d.3. Evocative Chromo-discography

Perform confirmatory contrast discography at this time. The following contrast mixture is used: nine cc of Isovue 300 with one cc of indigo carmine dye. This combination of contrast ratio gives readily visible radio-opacity on the discography images, and intra-operative light blue chromatization of pathologic nucleus and annular fissures which help guide the targeted fragmentectomy.

Discography is an integral part of selective endoscopic discectomy. The literature on discography is currently considered controversial. It is controversial partly because of the high inter-observer variability by discographers in reporting the patient’s subjective pain as well as the ailing patient’s inability to give a clear response, especially if pain response is altered by the use of analgesics or sedation during the procedure. The surgeon who is accomplished in endoscopic spine surgery should do the discography himself in order to decrease the inter-observer variability in interpreting the patient’s response and thus better select for appropriate patients.

### 3.d.4. Instrument Placement

Insert a long thin guide wire through the 18 gauge needle channel. Advance the guide wire tip, one to two centimeters deep into the annulus, then remove

the needle. Slide the bluntly tapered tissue dilating obturator over the guide wire until the tip of the obturator is firmly engaged in the annular window. An eccentric parallel channel in the obturator allows for four quadrant annular infiltration using small incremental volumes of one half percent lidocaine in each quadrant, enough to anesthetize the annulus, but not the nerves. Hold the obturator firmly against the annular window surface and remove the guide wire. Infiltrate the full thickness of the annulus through the obturator's center channel using lidocaine.

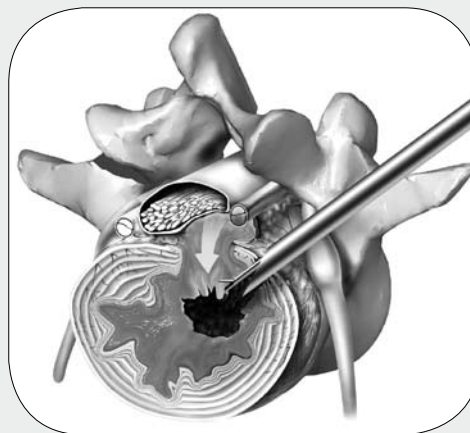The next step is the through-and-through fenestration of the annular window by advancing the bluntly tapered obturator with a mallet. Annular fenestration is the most painful step of the entire procedure. Advise the anesthesiologist to heighten the sedation level just prior to annular fenestration. Advance the obturator tip deep into the annulus and confirm on the c-arm views. Now slide the beveled access cannula over the obturator toward the disc. Advance the cannula until the beveled tip is deep in the annular window. Remove the obturator and insert the endoscope to get a view of the disc nucleus and annulus.

Alternatively if you are worried about further extruding a large disc herniation or you want to inspect the outer annular fibers before fenestrating the annulus, the surgeon can engage the outer annulus with the blunt obturator. Then the beveled cannula is advanced over the obturator to the annulus. The obturator is removed and the endoscope is inserted. The outer annular fibers can be inspected to ensure that no neural structures are in the path of the cannula prior to the annulotomy. Then an annulotome or a cutting trephine can be used for the annular fenestration under direct vision. Prominent disc tissue can be removed prior to entering the disc with the cannula.

The foraminal annular window is an easily identifiable c-arm and intraoperative anatomic landmark and is the starting location for endoscopic disc excision. Through the endoscope, the surgeon may see various amounts of blue stained nucleus pulposus. The general purpose access cannula has a bevel hypotenuse of 12 mm and outside diameter of 7 mm. When the cannula is slightly retracted to the midstraddle position in relationship to the annular wall, the wide angle scope visualizes the epidural space, annular wall and the intradiscal space in the same field.

### 3.d.5. Performing the Discectomy

The basic endoscopic method to excise a non-contained paramedian extruded lumbar herniated disc via a uniportal technique is described here. First enlarge the annulotomy medially to the base of the herniation with a cutting forcep. The side-firing Holmium-YAG laser can also be utilized to enlarge and widen the annulotomy. This is performed to release the annular fibers at the herniation site that may pinch off or prevent the extruded portion of the herniation from being extracted. Directly under the herniation apex a large amount of blue stained nucleus is usually present, likened to the submerged portion of an iceberg. The nucleus here represents migrated and unstable nucleus. The endoscopic rongeurs are used to extract the blue-stained nucleus pulposus under direct visualization. (Figure 5) The larger straight and hinged rongeurs are used directly through the cannula after the endoscope is removed. Fluoroscopy and surgeon feel guides this step. By grabbing the base of the herniated fragment, one can usually extract the extruded portion of the herniation. Initial medialization and widening of the annulotomy reduce the prospect of breaking off the apex of the herniation. The traversing nerve root is readily visualized after removal of the extruded herniation. (Figure 6,7,8)



**Figure 5:**

Uniportal technique for selective endoscopic discectomy. Rongeurs are used for visualized fragmentectomy. The beveled cannula can be positioned to view the intradiscal cavity, annular wall, and epidural space in the same field of vision.



Next perform a bulk decompression by using a straight and flexible suction-irrigation shaver (Endius MDS). This step requires shaver head c-arm localization before power is activated to avoid nerve/dura injury and anterior annular penetration. The cavity thus created is called the working cavity. The debulking process serves two functions. First it decompresses the disc, reducing the risk for further acute herniation. Second it removes the unstable nucleus material to prevent future reherniation.

Inspect the working cavity. If a non-contained extruded disc fragment is still present by finding blue stained nucleus material posteriorly, then these fragments are teased into the working cavity with the endoscopic rongeurs and the flexible radio-frequency trigger-flex bipolar probe (Ellman) and removed. Creation of the working cavity allows the herniated disc tissue to follow the path of least resistance into the cavity. The flexible radio-frequency bipolar probe is used to contract and thicken the annular collagen at the herniation site. It is also used for hemostasis throughout the case.

The vast majority of herniations can be treated via the uniportal technique. Sometimes for a large central herniations the disc needs to be approached from both sides, biportal technique.

---

#### 4. Potential Complications and Avoidance

As with arthroscopic knee surgery, the risks of serious complications or injury are low—about 1-3% in the author's experience. The usual risks of infection, nerve injury, dural tears, bleeding, and scar formation are always present as with any surgery. Transient dysesthesia, the most common post-op complaint, occurs about 5%-15% of the time and is almost always transient. Its cause is still incompletely understood and may be related to nerve recovery, operating adjacent to the dorsal root ganglion of the exiting nerve, or a small hematoma adjacent to the ganglion of the exiting nerve, as it can occur days or even weeks after surgery. Transient dysesthesia can occur even in cases where no adverse events were detected with continuous EMG and SEP neuromonitoring. Thus it cannot be completely avoided. The symptoms are like a variant of complex regional pain syndrome (CRPS), but less severe, and without the skin changes that accompany CRPS. Dysesthesia is readily treated by

transforaminal epidural blocks, rarely sympathetic blocks, and the use of Neurontin titrated up to 1800-3200 mg /day if needed.

Avoidance of complications is enhanced by the ability to clearly visualize normal and patho-anatomy, the use of local anesthesia and conscious sedation rather than general or spinal anesthesia, and the use of a standardized needle placement protocol. The entire procedure is usually accomplished with the patient remaining comfortable during the entire procedure and should be done without the patient feeling severe pain except when expected, such as during evocative discography, annular fenestration, or when instruments are manipulated past the exiting nerve. Local anesthesia using half percent xylocaine allows generous use of this dilute anesthetic for pain control and still allows the patient to feel pain when the nerve root is manipulated. Continuous EMG and SEP can also help monitor and prevent nerve irritation. This usually correlates well with the patients' intraoperative feedback.

---

#### 5. Discussion

Endoscopic spine surgery has a very high learning curve, but is within the grasp of every endoscopic surgeon with proper training. As with any new procedure, the complication rate may be higher during the learning curve, and may vary with each surgeon's skills and experience. The endoscopic technique is safer for the patient since he is conscious and able to provide immediate input to the surgeon when pain is generated. The surgeon's ability to perform the surgery without causing the patient undue pain will self select for surgeons who can master the technique to the extent that the surgeon will prefer endoscopic over traditional surgery for the same condition. For most contained disc herniations and discogenic pain, the experienced endoscopic spine surgeon will opt for the endoscopic approach as the treatment of choice for his patients.

---

#### 6. Case Presentation

##### 6.a. History

A 22 year old male with a two year history of low back pain and intermittent right leg pain sustained an acute worsening of his right leg pain 12 days

prior to evaluation. He proportionalized his pain to 5% back and 95% leg pain. He complained of a new onset of weakness, tingling, and constant numbness. The pain and numbness radiated down the posterolateral leg to the dorsum of the right foot. He was unable to bear weight on the right leg and was using a walking pole for support. He was unable to sleep supine and had to sleep in a recliner to minimize the pain. Sitting provided some relief. He denied bowel or bladder incontinence, but had constipation for the last 12 days.

### 6.b. Physical Exam

Physical exam revealed an antalgic gait, limited lumbar extension to 10 degrees, tenderness in the right sciatic notch, positive straight leg raising (SLR) and Lasegue's tests, positive contralateral SLR, 2+ bilateral patella and Achilles deep tendon reflexes, decreased sensation to light touch over the dorsum of the foot and to a lesser extent the lateral border of the foot, and weakness. The right sided weakness was graded as 4/5 anterior tibialis, 2/5 EHL, 3/5 hip abductor, 4/5 gastroc-soleus.

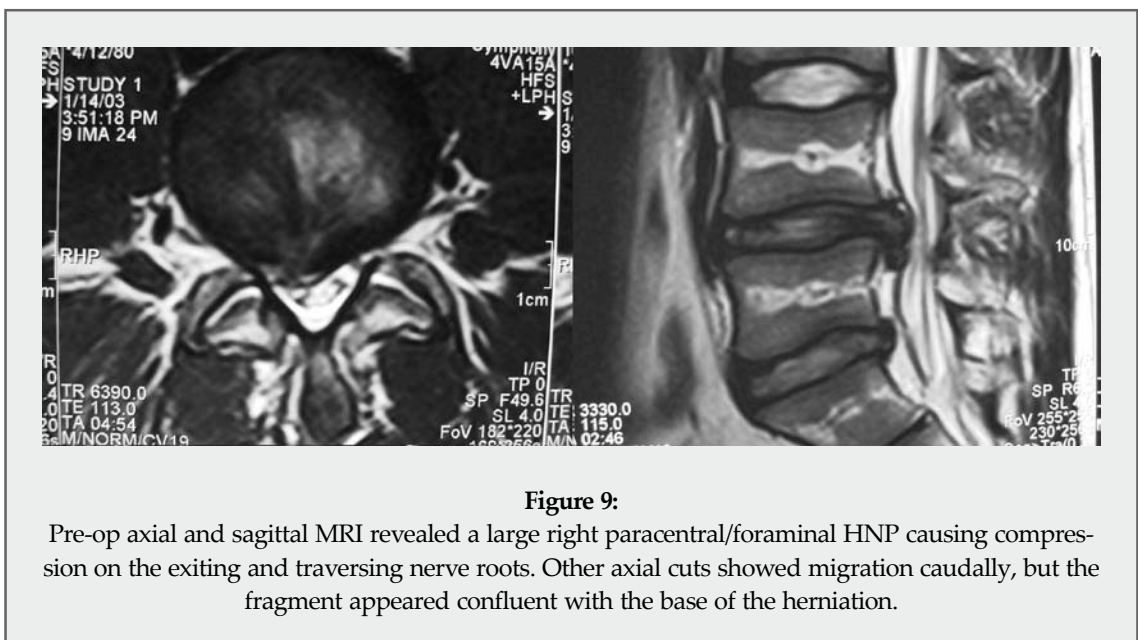
### 6.c. Imaging

MRI revealed a large right paracentral/foraminal extruded herniated nucleus pulposus with slight cau-

dal migration causing compression of both the exiting and traversing nerve roots (Figure 9).

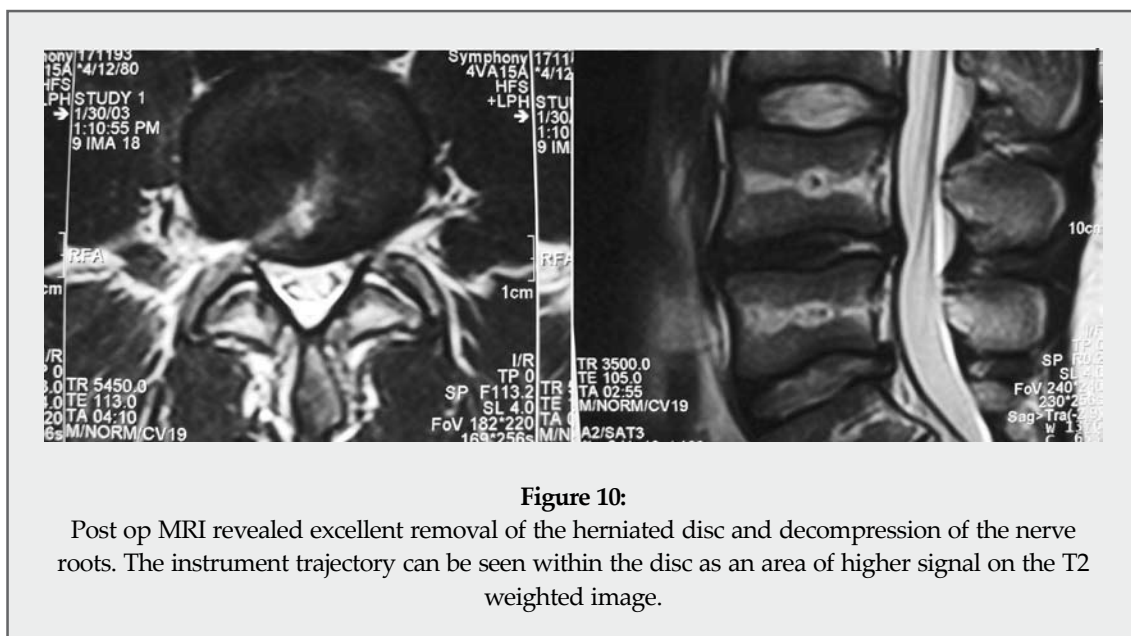
### 6.d. Treatment

Surgery was recommended due to the acute onset and progressive neurologic deficits. After a full discussion of his risks, benefits, and alternatives the patient elected to undergo outpatient selective endoscopic posterolateral discectomy. The patient experienced over 80% pain relief immediately post-op. He had some mild dysesthetic burning over the L4 distribution that started a few days post-op. This completely resolved by 4 weeks with the aid of neurontin 300mg TID. A post operative MRI was ordered when the patient had a acute worsening of his leg pain 11 days post op. (Figure 10) He said he "over did it". The patient's leg weakness was improving, but since some weakness was still present, we wanted to make sure he did not have a recurrent herniation. The MRI revealed excellent herniation removal without any retained fragments. The patient's acute pain resolved within 24 hours and he had no pain at all by 4 weeks. His weakness continued to improve grading 4/5 EHL, 4+/5 hip abductor, 4/5 anterior tibialis, and 5-/5 gastroc-soleus at his last follow up 2 months post-op.



**Figure 9:**

Pre-op axial and sagittal MRI revealed a large right paracentral/foraminal HNP causing compression on the exiting and traversing nerve roots. Other axial cuts showed migration caudally, but the fragment appeared confluent with the base of the herniation.



**Figure 10:**

Post op MRI revealed excellent removal of the herniated disc and decompression of the nerve roots. The instrument trajectory can be seen within the disc as an area of higher signal on the T2 weighted image.

## 7. References

- Bogduk N. The Innervation of the Intervertebral Disc. Chapter 5: 135-149. *The Biology of the Intervertebral Disc*, Vol I. Ghosh P ed. CRC Press, Boca Raton, FL. 1988.
- Luomaa K, Kilkka R, Luukkonen R, et al. Low Back Pain in Relation to Lumbar Disc Degeneration. *Spine* 2000;25:487-492
- Boden S, Herzog R, Rauschnig W, Rydevik B. Instructional Course Lecture #249: Lumbar Spine. *The Herniated Disc*. AAOS 67<sup>th</sup> Annual Meeting, 2000.
- Hadjipavlou AG, Simmons JW, Gaitanis IN, Goel VK. Etiopathogenesis of Disc Degeneration and Clinical Implication. In: Savitz MH, Chiu JC, Yeung AT, eds. *The Practice of Minimally Invasive Spinal Technique*. First edition. Richmond, VA. AAMISMS Education, LLC; 2000;16:149-170
- Farfan H. *Mechanical Disorders of the Low Back*. Philadelphia, PA: Lea & Febiger; 1973
- Bogduk N. *Clinical Anatomy of the Lumbar Spine and Sacrum*, 2<sup>nd</sup> Ed. Melbourne, Australia: Churchill Livingstone; 1996
- Adams MA, Hutton WC. Gradual Disc Prolapse. *Spine* 1985;10:524-531
- Adams MA, Hutton WC. Prolapsed Intervertebral Disc—A Hyperflexion Injury. *Spine* 1982;7:184-191
- Chaffin DP, Anderson GBJ. *Occupational Biomechanics*. New York, NY: Wiley Interscience; 1984:369-412
- Herzog RJ, Rydevick B, Boden SD. Instructional Course Lecture #310: Lumbar spine. *The Herniated Disc*. AAOS 70<sup>th</sup> Annual Meeting; February 7, 2003; New Orleans, LA
- Hermantin FU, Peters T, Quartararo L, Kambin P. A Prospective, Randomized Study Comparing the Results of Open Discectomy with those of Video-Assisted Arthroscopic Microdiscectomy. *JBJS* 1999; 81-A:958-965
- Hijikata S, Yamagishi M, Nakayma T. Percutaneous Discectomy: A New Treatment Method for Lumbar Disc Herniation. *J. Tokyo Den-ryoku Hosp* 1975;5:39-44
- Hijikata S. Percutaneous Nucleotomy. A New Concept Technique and 12 Years' Experience. *Clin. Orthop* 1989;238:9-23
- Kambin P, Gellman H. Percutaneous Lateral Discectomy of the Lumbar Spine. A Preliminary report. *Clin. Orthop* 1983;174:127-132
- Kambin P, Sampson S. Posterolateral Percutaneous suction-excision of Herniated Lumbar Intervertebral Discs. Report of Interim Results. *Clin. Orthop* 1986;207:37-43
- Kambin P, Brager M.D. Percutaneous Posterolateral Discectomy. Anatomy and Mechanism. *Clin. Orthop* 1987;223:145-154. 1987.
- Kambin P, Schaffer JL. Percutaneous Lumbar Discectomy. Review of 100 Patients and Current Practice. *Clin. Orthop* 1989;238:24-34
- Kambin P. Arthroscopic Microdiscectomy. *Arthroscopy* 1992;8:287-295

19. Kambin P, O'Brien E, Zhou L, Schaffer JL. Arthroscopic Microdiscectomy and Selective Fragmentectomy. *Clin Orthop* 1998;347:150-167
20. Mathews HH. Transforaminal Endoscopic Microdiscectomy. *Neurosurg Clin N Am* 1996;7:59-63.
21. Mayer HM, Brock M: Percutaneous Endoscopic Discectomy: Surgical Technique and Preliminary Results Compared to Microsurgical Discectomy. *J Neurosurg* 1993;78: 216-225
22. Onik G, Helms CA, Ginsberg L, Hooglund FT, Morris J. Percutaneous Lumbar Discectomy Using a New Aspiration Probe. *Am. J. Roentgenol* 1985;144:1137-1140
23. Schaffer JL, Kambin P. Percutaneous Posterolateral Lumbar Discectomy and Decompression with a 6.9-Millimeter Cannula. Analysis of Operative Failures' and Complications. *JBJS* 1991;73-A 822-831
24. Schreiber A, Suezawa Y, Leu H. Does Percutaneous Nucleotomy with Discoscopy Replace Conventional Discectomy? Eight Years of Experience and Results in Treatment of Herniated Lumbar Disc. *Clin. Orthop* 1989;238:35-42
25. Tsou PM, Yeung AT. Transforaminal Endoscopic Decompression for Radiculopathy Secondary to Non-contained Intracanal Lumbar Disc Herniation. *Spine Journal* 2002; 2:41-48
26. Yeung AT. The Evolution of Percutaneous Spinal Endoscopy and Discectomy: State of Art. *Mt. Sinai J Med* 2000; 67:327-332
27. Yeung, AT. Minimally Invasive Disc Surgery with the Yeung Endoscopic Spine System (Y.E.S.S.). *Surgical Technology International VIII* 1999;1-11
28. Yeung AT, Tsou PM. Posterolateral Endoscopic Excision for Lumbar Disc Herniation. The Surgical Technique, Outcome and Complications in 307 Consecutive Cases. *Spine* 2002;27:722-731
29. Gogan WJ, Fraser RD. Chymopapain. A 10-Year, Double Blind Study. *Spine* 1992;17:388-94
30. Javid MJ, Norby E. Safety and Efficacy of Chymopapain (Chymodiactin) in Herniated Nucleus Pulposus with Sciatica – Results of a Randomized, Double Blind Study. *JAMA* 1983;249:2489-2494
31. Smith L. Chemonucleolysis. Personal History, Trials, and Tribulations. *Clin Orthop* 1993;287:117-124
32. Hoogland T, Scheckenbach C. Percutaneous Lumbar Nucleotomy with Low-dose Chymopapain, an Ambulatory Procedure. *Z Orthop Ihre Grenzgeb* 1995;133(2):106-13. German
33. Van de Belt H, Franssen S, Deutman R. Repeat Chemonucleolysis is Safe and Effective. *Clin Orthop* 1999;363:121-5
34. Deutman R. The Case for Chemonucleolysis in Discogenic Sciatica. A review. *Acta Orthop Scand.* 1992;63(5):571-5. Review
35. Yasargil MG. Microsurgical Operation of Herniated Lumbar Disc. In: Wullenweber R, Brock M, Hamer J, Klingler M, Spoerri O, eds. *Advances in Neurosurgery*, vol 4. Berlin, New York:Springer-Verlag; 1977:81-94
36. Williams RW. Microlumbar Discectomy: A conservative Surgical Approach to the Virgin Herniated Lumbar Disc. *Spine* 1978;3:175-82
37. Perez-Cruet MJ, Foley KT, Isaacs RE, et al. Microendoscopic Lumbar Discectomy: Technical Note. *Neurosurgery* 2002;51(5 Suppl):129-36
38. Knight MTN, Goswami AKD. Endoscopic Laser Foraminoplasty. In: Savitz MH, Chiu JC, Yeung AT, eds. *The Practice of Minimally Invasive Spinal Technique*. First edition. Richmond, VA. AAMISMS Education, LLC; 2000;42:337-40
39. Osman SG, Nibu K, Panjabi MM, Marsolais EB, Chaudhary R. Transforaminal and posterior decompressions of the lumbar spine. A comparative study of stability and intervertebral foramen area. *Spine* 1997;22(15):1690-5
40. Ito M, et.al. Transforaminal Surgery for Pyogenic Thoracolumbar Spondylodiscitis. Paper presented at: the American Academy of Minimally Invasive Spinal Medicine and Surgery 3<sup>rd</sup> World Congress; Dec 8-11, 2002; Phoenix, Arizona