

## 35

# ANTERIOR, POSTERIOR DYNAMIC SYSTEMS AND THEIR ADVANTAGES AND DISADVANTAGES

Ahmet Levent AYDIN M.D.

Lumbar pain affects approximately 80% of the society in any stage of life at least once in a lifetime, and it turns into a chronic complaint in some of the affected patients. It reduces the life quality of the affected patient group, causes a considerable amount of burden both socially and economically, and leads to a long-term labour loss both during and after the stages of disease treatment.

*Degenerative disc disease* (DDD) ranks first among the causes of lumbar pain, which is a condition leading to aforementioned disturbances, and the etiology of the disease is still not known thoroughly. General opinion about the occurrence of this clinical syndrome is the alteration of the load-carrying capacity of the degenerated disc and the emergence of a relative stability due to an impairment of the movement segment. Thus, this instability causes pain.<sup>(1)</sup> Degeneration initiating in the disc tissue of the lumbar movement segment results in dehydration and radial ruptures in nucleus pulposus, and in the reduction of the disc height together with changes in collagen structure and its protrusion into the canal and foramina, together with radial and circumferential ruptures in annulus fibrosus, besides radial and circumferential ruptures. Following these changes, facet joint arthrosis starts to develop in time in posterior columns formed by facet joints due to irregular loading. Finally, rotational and transitional deformations depending on the relaxation of annular and vertebral ligaments lead to segmental instability. And this instability impairing the movement segment causes lumbar pain.<sup>(2,3)</sup> Origin of the pain in a symptomatic movement segment can be cartilage end plates in vertebra, disc annulus, vertebral

periosteum, and facet joints in particular, and also soft tissues such as muscle and connective tissue, which surround the vertebra.

Facet joints and hypertrophies in ligamentum flavum formed in the specified course of time result in lateral and central canal stenosis. Also the movement segment fails to keep its original position, and clinical conditions such as scoliosis, flat-back syndrome and rotational instability reveal.

During degeneration, lateral and anterior syndesmophytes, spondylophytes occur, and cause movement limitation of the vertebral segments in later stages. During the course of degeneration, symptoms of the patient change as well depending on these stages. At early stages of lumbar spondylosis, lumbago episodes frequently observed as a consequence of vertebral loading reduce as spontaneous ankylosis develops. However, as the result of canal stenosis, neurogenic findings of claudication and radicular symptoms emerge.

Rationale for emerging radicular symptoms is the pressure applied by neural foramen, lateral recess and narrowed vertebral canal on the nerve root. Sufficient decompression relieves these complaints.

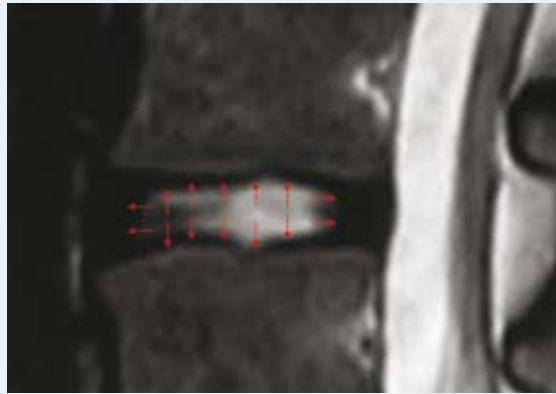
Reason for lumbar pain is not as clear as the pain mechanism caused by radicular symptoms. Lumbar pain, which is considered to manifest itself following instability occurring as the result of a decrease in disc height, does not respond to the fusion surgery as intended. According to Mulholland and Sengupta<sup>(6,7)</sup>, sites where irregular pressure is applied on cartilage end plates by the degenerated disc content could be the origin of the pain in degenerative disc

disease. Non-homogeneous fragments formed by fragmented and condensed collagen within the degenerated disc with impaired structure cause pain by applying excessive load on some sites at end plates rich in nerve endings (analogy of stone in the shoe) (Figure 1 and 2).

Pathological deformations in the disc tissue lead to abnormal loads at cartilage end plates and impairments in the normal distribution of intradiscal pressure during anterior, posterior and lateral flexions. In studies of intradiscal pressure profilometry by McNally and Adams<sup>(8,9)</sup>, anisotropic changes within the impaired disc have been demonstrated.

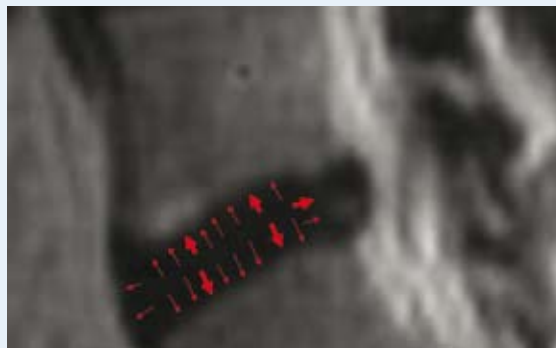
When the load-bearing balance at cartilage end plaques gets impaired, destructions at the cartilage end plaque and subchondral bone occur. As the result of this destruction and the decrease in disc height, tension reduction, rupture, cambering, and diffusion emerge in annulus.

In degenerative disc disease, different treatment options ranging from conservative treatment to the surgery can be used depending on the medical condition of the patient. Neurologic decompression, stabilization, or both of these in combination with each other are used in surgical treatment. Decompression and fusion surgery are performed from past to present in lumbar pain due to degenerative disc disease. The underlying reason of fusion surgery is the conception that pain is caused by an abnormal vertebral movement, and that the origin of pain will disappear when this movement is given up. The fact that pain complaint is not relieved in some patients undergoing to fusion surgeries, that the detection of pseudoarthrosis also in some patients with improved clinical condition, and that the success rate of fusion surgery being determined lower than expected gave rise to the concept of "dynamic system" in minds of researchers<sup>(10,12)</sup>. According to the studies conducted on these systems, dynamic systems applied for the correction of the instability terminate pain by bearing the load, which should be carried by the impaired disc.<sup>(1)</sup> In the last ten years, in the light of developments in the fields of tissue engineering and metallurgy, and of biomechanical developments, usage of numerous dynamic systems varying from artificial discs to



**Figure 1:**

*Equal distribution of intradiscal pressure into the cartilage end plaque and annulus in a normal vertebra is demonstrated in a T2-weighted MRI slice acquired on sagittal plane.*



**Figure 2:**

*In a T2-weighted MRI slice acquired on sagittal plane, non-homogeneous condensed cartilaginous structures cause pain at their site of localization by applying intensive pressure on the cartilage end plate and annulus (analogy of stone in a shoe).*

dynamic pedicle screws has become widespread. These systems balance the carried load without implementing the fusing functional vertebral segment while taking the vertebral movement under control<sup>(13,15)</sup> They improve the clinical condition by bearing the load, which should be carried by the degenerated disc. In the light of growing knowledge, dynamic stabilization is much more involved in the vertebral surgery. In our day, fusion surgery is advised in overt instabilities, whereas dynamic system in chronic instabilities.

## 1. Overall Evaluation of Disadvantages of Fusion Systems

According to Panjabi, in addition to decompression, also the fusion surgery is applied in the surgical treatment of the clinical instability, called as “pathological vertebral mobilization”, which causes neurological loss, pain, and deformity.

But in spite of improvements in the surgical technique the fusion surgery had never succeeded completely, and was not far from side effects at all. Due to the increasing knowledge about advanced technology and biological materials, rates of patients’ recovering from pain remained lower, though a success rate of fusion by around 100% was attained. As the cause of this, disadvantages of the fusion surgery are indicated just like as it is in the degeneration of the adjacent segment<sup>(16,22)</sup> (Figure 3).

With methods of anterior lumbar interbody fusion (ALIF), posterior lumbar interbody fusion (PLIF), transforaminal lumbar interbody fusion (TLIF) and

posterior lateral fusion (PLF), a fusion of 360° is attempted to accomplish.

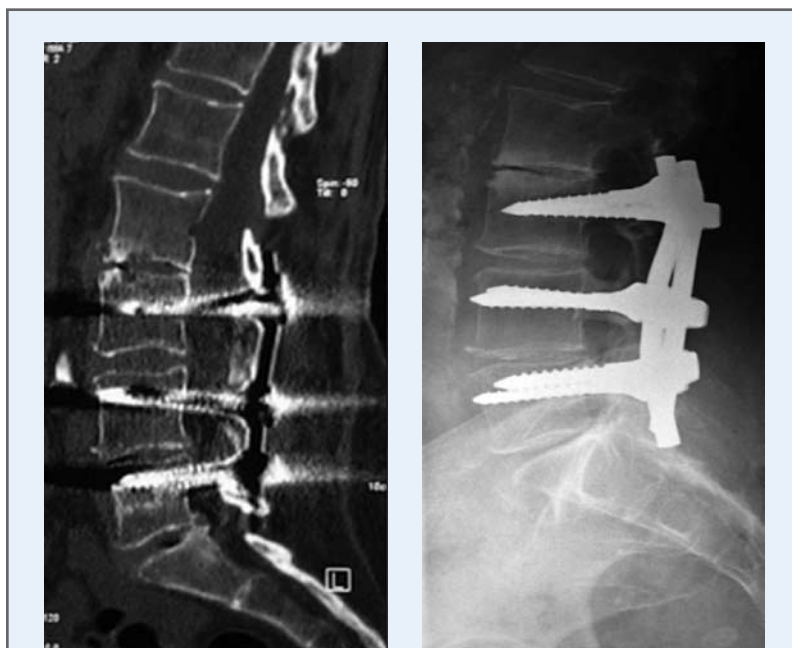However, in these fusion surgeries, complication risk is increased, and also a degeneration rate by 16.5% within the first five years and by 36.1% within the first ten years was observed in adjacent segments<sup>(23)</sup>. At the same time, adjacent segment problems such as facet joint impairments, symptomatic pseudoarthroses, problems at donor osseous sites, and infection showed a considerable increase following fusion surgeries<sup>(5)</sup> (Figure 4 and 5). Greater superiority of dynamic segments over fusion surgeries is that these systems prevent the degeneration in the adjacent segment by allowing a partial movement. In addition to resulting in a degeneration of the adjacent segment, fusion systems also cause important deformities like flat-back syndrome as the result of surgical procedures leading to destruction. After fusion surgery, in the presence of normal loadings the chance to return back to the normal vertebral posture disappears.

Even fusion surgeries applied without experiencing any surgical problems cause postural stress in adjacent segments. On the other hand, dynamic systems do not result in abnormal movements in the movement segment during postural changes.

Fusions between fourth lumbar and first sacral vertebra (L4-S1) lead to rotational stress in sacroiliac joints while sitting.

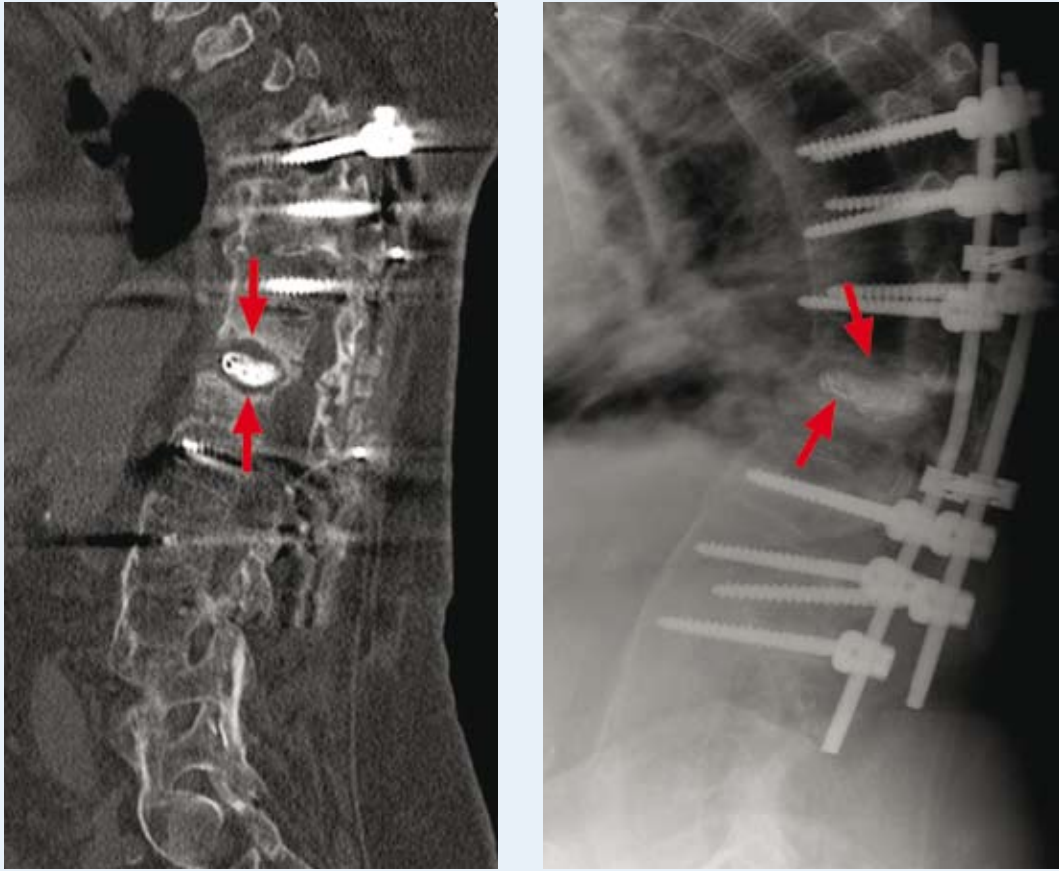
Posterior dynamic systems are favorable versus rigid systems when fusion is attempted. Formation of fusion is facilitated during anterior flexion by ensuring more load-bearing over the bone graft placed between vertebral corpora in front (*Wolfe law*).

However, the essential purpose of applying these systems is that they substitute for a vertebral support in cases where no arthrodesis is desired, and that they ensure stabilization



**Figure 3:**

*In CT and direct lateral X-Ray, the apparent degeneration (adjacent segment disease) in the second and third lumbar (L2-L3) vertebral discs in the neighborhood of fusion over time is shown as the result of the fusion surgery performed on the lower lumbar region.*



**Figure 4:**

*In CT scan of a patient at an advanced age and at a later osteoporotic stage, it is observed that bone grafts mixed with calcium phosphate form pseudoarthrosis rather than building up a fusion.*

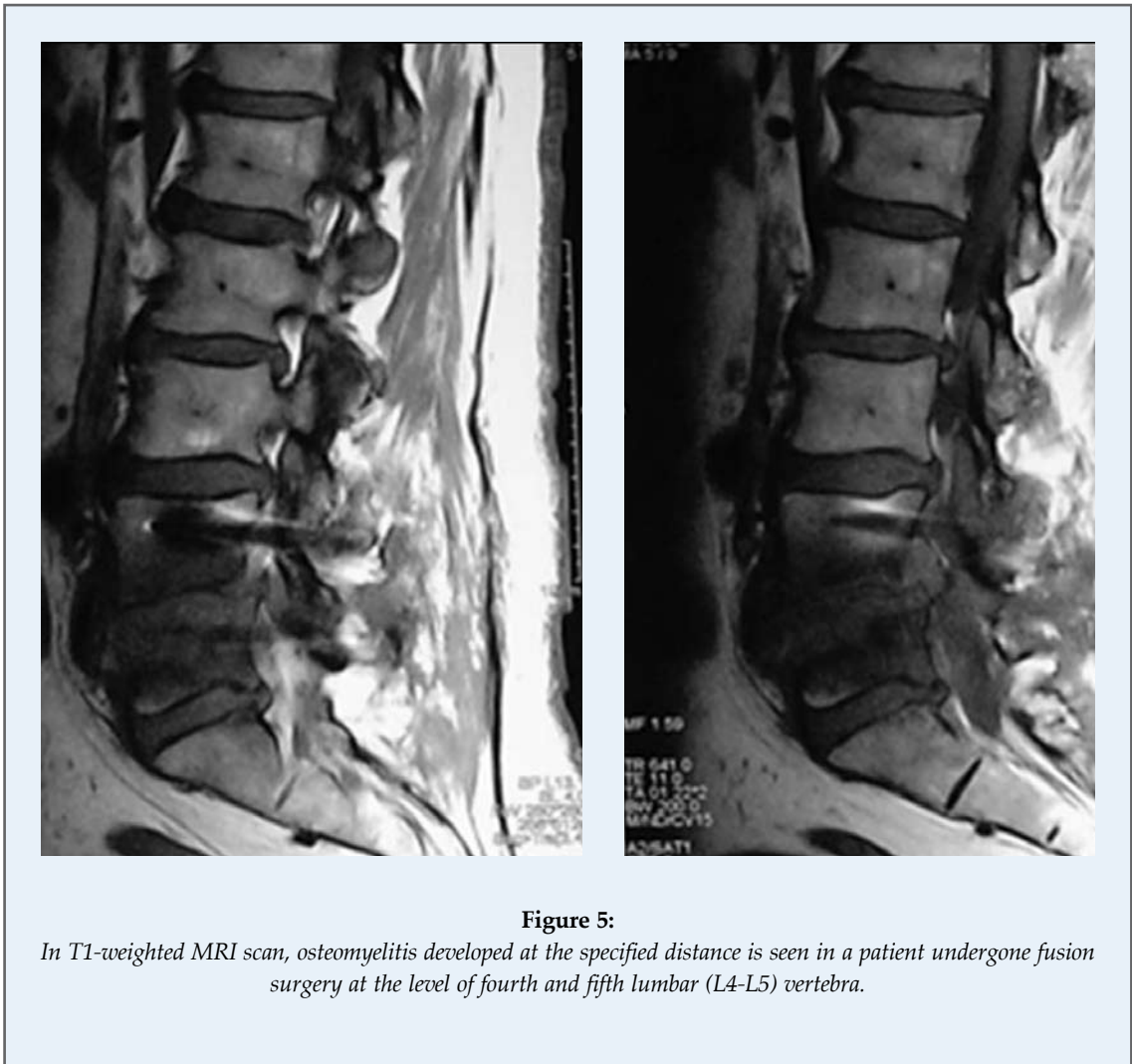
without completely eliminating movement.<sup>(8)</sup> Using the same mechanism by anterior fusion systems, posterior dynamic stabilization systems eliminate pain by reducing the load on the tissue of the impaired disc without causing movement deformation. In other words, dynamic systems do not restrict the vertebral movement in normal loading, whereas in abnormal loading they prevent pain by restricting the movement<sup>(6,8,24-26)</sup>.

For obtaining a desired result by the dynamic stabilization systems, they should function in harmony with soft tissues such as muscle and connective tissue, which surround the vertebra.

To this end, it is required that dynamic systems should be applied with the least possible damage to soft tissues.

Their applications through the paravertebral muscle tissue by Wiltse technique reduce the tissue damage, and consequently ensure them to become favorable versus fusion systems, with respect to surgical trauma as well (Figure 6).

Moreover, in dynamic system surgeries, time of surgery and the rate of complication decrease due to the fact that no bone graft is needed to be obtained from the patient for spondylodesis, or that no vertebral decortication could be performed<sup>(4)</sup> (Figure 7). Furthermore, since posterior dynamic systems are much simpler instrumentation surgeries, rates of mortality and morbidity in fusion surgeries are extremely lower in those surgeries. Dynamic stabilization systems, which have been used in vertebral surgery for a period of time longer than the last ten years,



**Figure 5:**

*In T1-weighted MRI scan, osteomyelitis developed at the specified distance is seen in a patient undergone fusion surgery at the level of fourth and fifth lumbar (L4-L5) vertebra.*

are generally classified as 1-“anterior disk prostheses” and 2-systems forming posterior tension band. **Systems forming posterior tension band:** while allowing for anterior and posterior flexion, they restrict the movements in other planes. They maintain the mechanical balance on vertebra once again by reducing the load over the disc without eliminating the mobilization ability of the vertebra (Figure 8). Thus, fusion complications like adjacent segment degeneration are decreased as well. This characteristic of posterior dynamic systems revives the thesis that in the case of instability, lumbar pain depends on the position and posture of the vertebra rather than on its movement.

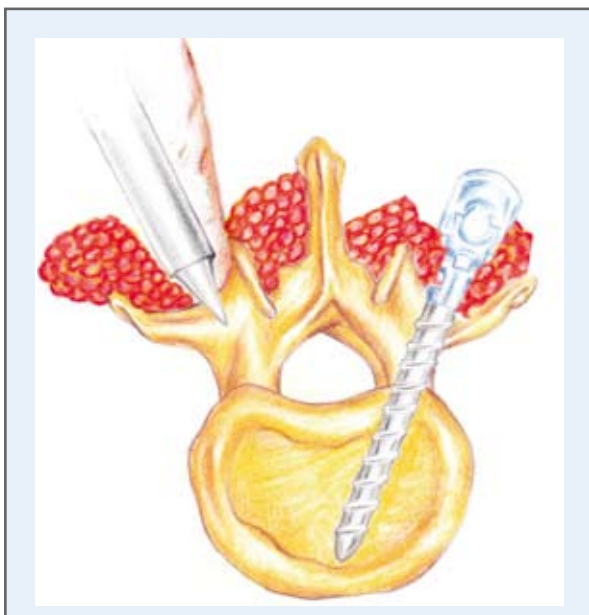
In dynamic radiography examinations of many patients, who defined mechanical pain in connection

with posture or position, no evident mobilization is detected on vertebra.

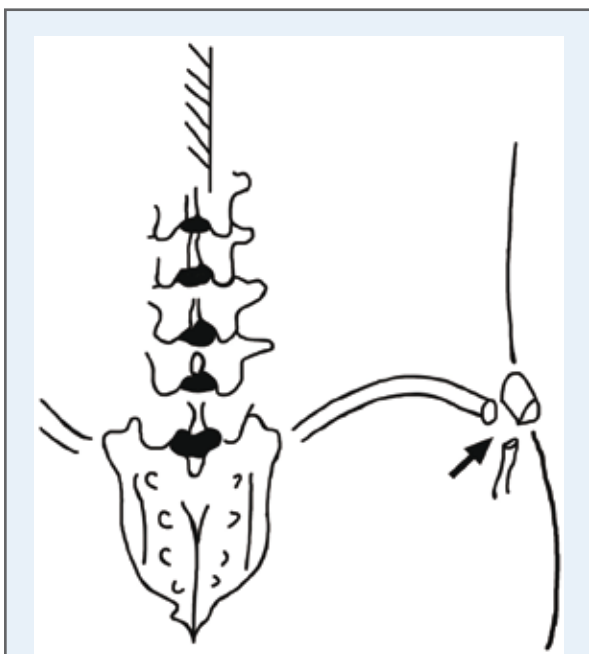
## 2. Dynamic Systems Frequently Applied in Vertebral Surgery

### 2.a. Graft Ligament System

The first system used for the purpose of dynamic stabilization is “Graft ligament system”. This system ensures the shift of vertebral load towards the posterior column by strengthening the posterior tension band, which is the common characteristics of ligament systems. Graft ligament system is supported by many people in Europe and Far East, and successful results obtained through its application are published and introduced to the literature. The



**Figure 6:** Wiltse technique



**Figure 7:** Iliac graft is one of the most frequently used sites as grafts. However, the majority of patients, from whom grafts are acquired at this site, complain from donor site pain rather than pain at surgical site following the surgery.

system is comprised of a non-elastic band between pedicle screws in posterior of the vertebra (Figure 9). According to Henry Graf, inventor of the system and whom the system is named after, the origin of vertebral pain was abnormal rotation movement. Therefore, system restricts especially the rotational movement by locking the facet joints in posterior flexion<sup>(27)</sup>. It partially allows for anterior flexion within limits of movement. However, since this angle of anterior flexion is within physiological limits, it does not cause any pain. It relieves the load over disc by forming a posterior tension band and thus partially eliminates the disc, which is the origin of pain.

Studies on Graft ligament system are not adequate yet. Nevertheless, some analyses document that the clinical success of this system is close to those of with fusion systems.

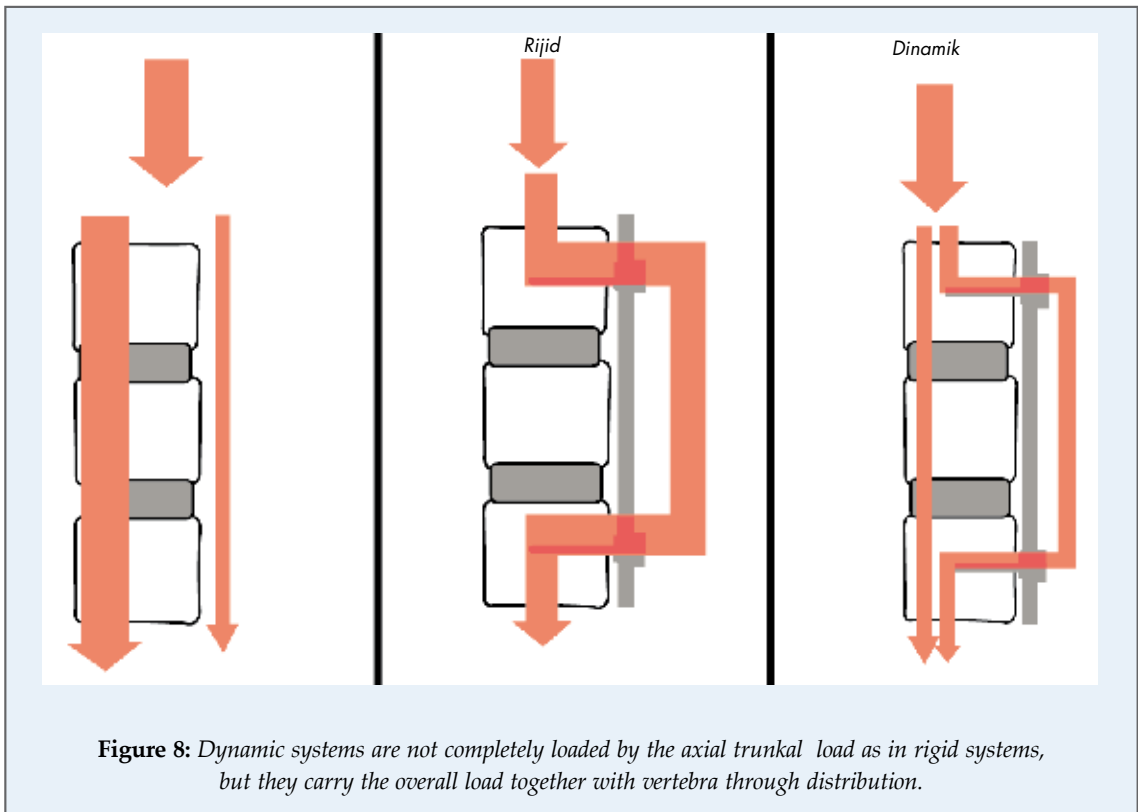
Rate of successful results obtained during a two-year follow-up period are indicated to be 75%<sup>(8,28)</sup>. In a 4-year prospective study including 88 patients, Graft ligament system was found to be more successful in relieving lumbar pain in mild spondylolisthesis compared to decompression<sup>(29,31)</sup>. Researchers argued that this system should be applied in younger patients with adequate muscle mass and normal facet anatomy.

### 2.b. Disadvantages of the System

Disadvantages of the system include that it increases symptoms for lateral recess stenosis by narrowing the orifice of the foramen by locking facets during posterior flexion and cambering ligamentum flavum towards the canal. This effect is observed particularly as the result of segmental lordosis, which reveals after the application of system, and it causes pain at an early postoperative period.

Indicated disadvantage is especially recorded in patients having degenerative changes in facet joints and ligamentum flavum hypertrophy.

Disc profilometry studies showed that Graft ligament system shifts the load distribution from anterior of the disc towards its posterior and this causes a rapid degeneration in the posterior zone of the disc. The system loses its preventive characteristic against degeneration because of relaxation during hyperextension<sup>(8,32)</sup>.

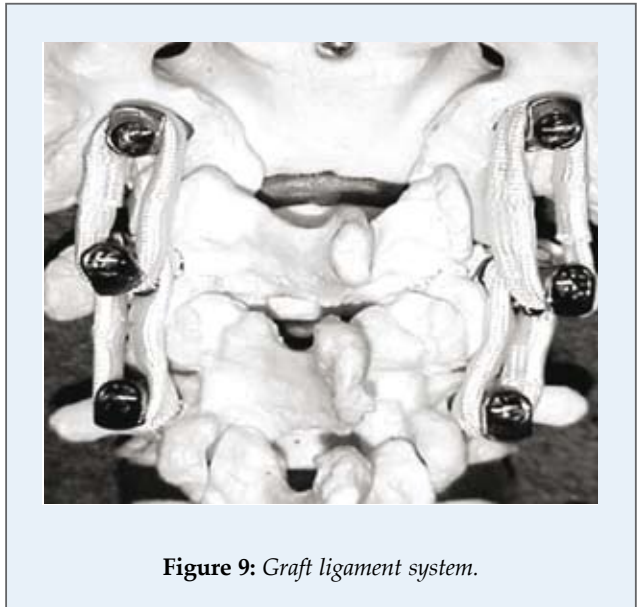


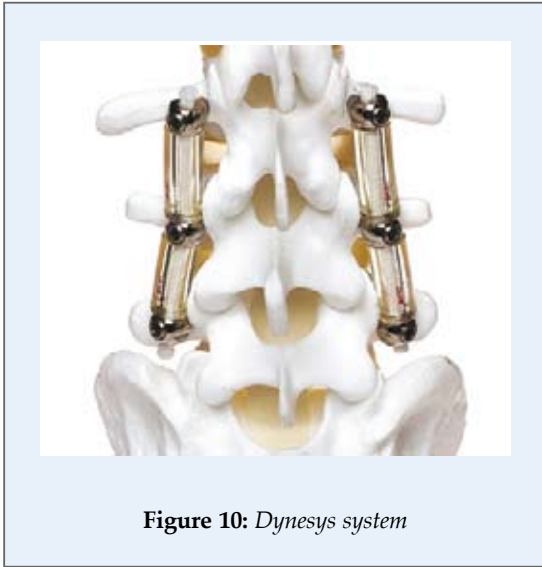
### 2.c. Dynesys Dynamic Stabilization System

Dynesys (Dynamic neutralization system-Zimmer Spine, Inc., Indiana, USA) is developed by Gilles Dubois in 1994. A plastic tube (Sulene polycarbonate urethane/PCU) is attached around the non-elastic [Sulene polyethylene terephthalate/PET) tension band, which is placed between hydroxyapatite-coated titanium pedicle screws. While taking the anterior flexion under control, posterior flexion is restricted by plastic tubes. These plastic tubes are also partly responsible for load-bearing. It is applied in spinal stenosis, degenerative discopathy, disk hernia, spondylolisthesis and revision surgery, and successful clinical results obtained are published (Figure 10). Technically, caution should be exercised to some points in the application of Dynesys system. For example, plastic tubes longer than required could lead to focal kyphosis. Generally, five clinical indications are reported for the application of Dynesys system. These are: 1-spinal stenoses accompanied by mild instability, 2-Grade I spondylolisthesis, 3-adjacent segment degeneration developing

due to a fusion operation undergone, 4-recurrent disc hernia and 5-degenerative disc disease<sup>(4)</sup>.

Its contraindications are: active systemic or local infection, severe osteopenia or osteoporosis, metabolic bone diseases, chronic corticosteroid usage,





**Figure 10:** *Dynesys system*

spondylolisthesis further than Grade I, ischemic spondylolisthesis or spondylolysis, pedicle fractures, total facetectomy, scoliosis more than 10°, allergic conditions against materials it includes.

Superiority of Dynesys system over Graft system is the fact that plastic tubes reduce the occurrence of pain by preventing the pressure on posterior annulus. In in-vitro studies carried out in cadavers, it is suggested that Dynesys system allowed 1-3° more movements in anterior and posterior flexion versus rigid systems at the level of third and fourth lumbar (L3-L4) vertebra. When compared to normal vertebra, it is observed that posterior flexion rate in this system did not differ, while it prevented anterior flexion by 30%. During the application of Dynesys system, facet capsules and other anatomic structures are not damaged like in fusion surgery, and thanks to the application flexibility of the system, it can be used together with other systems. In addition to these, the rate of adjacent segment degeneration in the system is lower than that of in fusion, and since no bone decortication is required for fusion and no procedure of muscular damage is performed for the placement of pedicle screws, the system causes less surgical trauma compared to the fusion.

#### 2.d. Disadvantages of the System

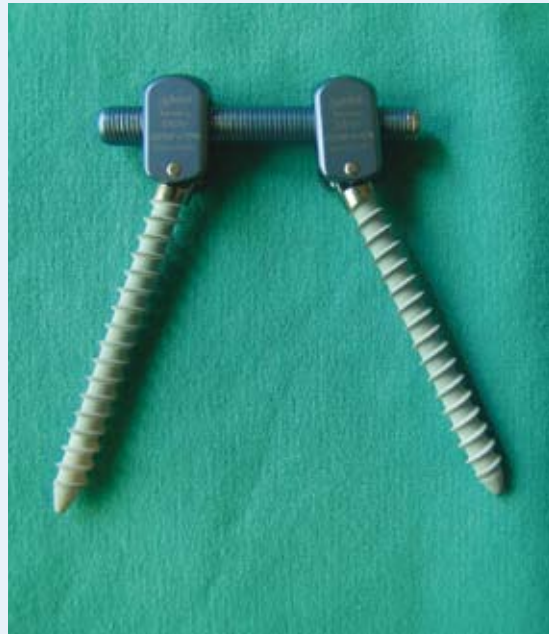Patients with trauma, patients of total facetectomy, isthmus fracture, and high-grade spondylolistheses

are among the major disadvantages of Dynesys system<sup>(33)</sup>.

Using PCU plastic tubes too long could result in a surgical failure by causing focal kyphosis, which leads to an increased pressure within the disc anterior compartment. It also causes retraction and bending of pedicle in compressive load-bearings.

In this case, it may cause fracture and loosening of the pedicle screw. In compressive load-bearings, retractor is compressed, and moves simply like a rigid implant<sup>(8,34,35)</sup>.

In 84 deformity patients study by Putzier, fewer progression of disc degeneration is observed in discectomy patients with Dynesys system applied compared to those who had no surgery<sup>(36)</sup>. According to 83 case study by Stoll, Oswerty scoring in 83 patients on whom Dynesys system had been applied decreased from 54 to 23. Life quality in connection with lumbar pain in 31 patients followed by Grob for two years improved significantly in half of the patients, but %19 of those were reoperated.<sup>(37)</sup> In these studies, quite different patients groups were used and no randomization was performed. Results of these studies showed no advantages versus fusion surgery<sup>(6,8)</sup>.



**Figure 11:** *Cosmic dynamic screw*



### 2.e. Cosmic Posterior Dynamic System

Stability of this system, which could be defined as a stable but not rigid system, is ensured by a titanium rod of 6.25 mm in diameter, whereas its flexibility is maintained by a pedicle screw system with screw neck joint. Screws with an articulated neck do not allow horizontal rotation and translation, but they prevent the excessive load in adjacent segments by enabling the micro-movement on sagittal plane (Figure 11).

In studies conducted in the laboratory, the system endured to 10 million cycles at 1 Hz at 0.3-3.0 KN. This rate normally corresponds to a 30-year post-operating time. Load distribution is divided between the anterior segment of vertebra and the system (Figure 8). Screws are coated with bioactive calcium phosphate in order to increase the osseous integration.

Because the system is semi-stable and ensures rotational and translational stability, as distinct from Graf and Dynesys systems it can be used in cases with discogenic lumbar pain as well as in those undergone laminectomy and total facetectomy. No transverse connection is required in applications related to 2-3 segments.

In examples where bisegmental decompression is performed and in the presence of excessive rotational instability, this system turns range of motion/ROM, lateral bending, flexion and extension movements back to normal, and reduces the movement rates to normal limits just as it is the case for normal segments.<sup>(38)</sup>

Cosmic system provides higher stability against rotation and translation, and does not restrict flexion and extension movements on sagittal plane. This system forms a tension band between vertebral segments, and restores the impaired lordosis angle. As the result of this, it ensures the transition of load-bearing over the impaired movement segment without damaging it, and it is avoided that the vertebra gets into positions, which will cause pain.

Cosmic stabilization system is indicated in lumbar pain due to discogenic lumbar pain and facet syndrome, recurrent disc hernia surgeries, decompression surgeries of cases with lateral lumbar spinal stenosis and due to central and facet ligamentum flavum hypertrophy, and in fusion surgeries where adjacent degenerated segment should be sup-

ported by the dynamic system (hybrid stabilization systems).

Among the contraindication of the system, the following may be claimed: deformity surgeries requiring stabilization more than three levels, kyphosis reductions, anterior vertebral defects, and local or general infection<sup>(39)</sup>. As the system will become more rigid when applied over two levels, especially its application over soft discs is not advised. In Turkish spinal surgery market, "Safinaz" screw has been produced, which is more cost-efficient and has the identical characteristics with Cosmic system; however it allows only 1° rotation. Biomechanical studies have been conducted on this screw and values approximating rigid stabilization have been obtained<sup>(38,40)</sup> (Figure 12).



**Figure 12:**  
*Safinaz dynamic screw*

## 3. Posterior Facet Replacement Systems

### 3.a. Total Posterior Element Replacement System (TOPS)

A joint having the characteristics of the movement segment is placed on the intermediary segment in order to ensure the normal biomechanical movement of the functional unit with the purpose of restoring the impaired segment to normal. Its application is difficult, and clinical results could not have been successful (Figure 13).

### 3.b. Fulcrum Assisted Soft Stabilization (FASS)

It is aimed to distract posterior annulus by placing a support between pedicle screws in front of the

ligament. Disadvantages of Graft ligament are attempted to be eliminated in order to avoid posterior effusion and foraminal stenosis. Its clinical results are not included in the literature yet (Figure 14).

#### 4. Total Disk Replacement Systems

The most applied total disc replacement (TDR) systems in the field of spinal surgery are: Charite, ProDisc-L, MobiDisc, Maverick, Kineflex (Figure 15). These systems are applied in monosegmental symptomatic degenerative disc disease and in post-discectomy syndrome. Surgical criteria in selecting the patient are: Conditions where at least 1-2 months of lasting lumbar pain is recorded, no response to conservative treatment lasting for at least 6 months is received, no spondylolisthesis nor spondylosis, no slippage towards anterior and posterior are detected in dynamic X-rays, and no facet joint arthropathy is determined in CT. It should not be performed on patients, who are benefiting from facet joint injection<sup>(45)</sup>. Operating principle of aforementioned systems is almost the same with that of hip and knee joint prosthesis systems. Removing out the tissue of degenerated disc that is the origin of pain resolves syndromes of the patient. Similarly in hip and knee prostheses, curratage of the cartilage tissue completely which causes pain is required before placing prosthesis.

Then, segmental movement established by the inserted disc prosthesis reduces the degeneration rate of the adjacent segment and contributes to the normal vertebral function by constituting the sagittal balance. Total disc prosthesis surgery should not be performed on the patient group developed facet arthrosis, because movement is preserved and only anterior column pathology is targeted.

*Total disk replacement (TDR) systems:* following issues are of importance since



Figure 13: TOPS (Total posterior element replacement system).

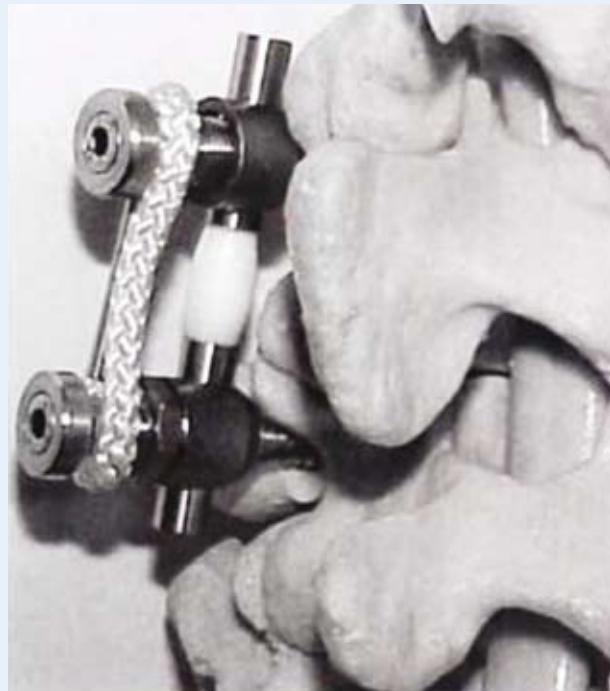


Figure 14: FASS (Fulcrum assisted soft stabilization) system.



**Figure 15:** *Maverick disc prosthesis.*



**Figure 16:** *Charite III disc prosthesis.*

they are applied in place of the evacuated disc tissue regarded as the origin of pain:

Ensuring that the prosthesis operates at least for 50 years prior to the onset of the mechanical wearing

in presence of physiological loading, that the system does not cause any facet arthrosis at the level where its kinematics is applied and does not lead to adjacent segment disease, and that the system sustains its function without any observed loosening and collapse.

The first TDR system (Charite) is applied since 1980's and no case of osteolysis has been reported until today. Wearing ratio in these systems is less than it is for hip and knee prosthesis, because the range of movement in vertebral segments where there are applied to is more limited compared to these joints.

#### 4.a. Charité Disc Prosthesis

It is developed by Karin Buttner-Janz and Kurt Schellnack in Charite hospital, Berlin. Firstly, it is performed on 13 patients in 1984. It consists of polyethylene-framed hydroxyapatite-coated titanium parts.

Movement is ensured on the joint between concave and convex surfaces of the disc, whereas a slight anterior and posterior slip is observed in flexion and extension (Figure 16). As collapse is observed in initial applications, structure of prosthesis is changed and its load-bearing surface adjacent to corpus is enlarged. The primary indication for Charite disc replacement system is the painful disc degeneration. It is required that symptoms are endured for at least 6 months and that the patient should not have benefited from the physical therapy. It is essential that examinations such as clinical consultation, MRI and discography should support the diagnosis.

No vertebral fracture should be present at the level of prosthesis application, and no Charite disc should be performed in the presence of osteoporosis. Again at this level, the system fails if there are any moderate or advanced facet joint arthrosis. Abdominal surgery undergone at the

level of application of the system is also included among contraindications. Charite should not be performed together with vertebral surgeries undergone,

which impair the biomechanics, disc structure, and stability of vertebra. In a clinically study controlled by Food and Drug Administration (FDA), which investigates the long-term clinical results and reliability of Charite prosthesis, a comparison of Charite prosthesis with *anterior lumbar interbody fusion* (ALIF) method was made in lumbar disc degeneration. In patients who were assessed by *visual analogue scale* (VAS), *Oswestry disability index* (ODI) and SF-36 scoring, VAS and ODI scorings of Charite group were observed to be better in postoperative 24<sup>th</sup> month, when compared to fusion group<sup>(41)</sup>.

In a study where 26 patients were followed-up for 10 years, it was observed that the mobility of prosthesis in patients was preserved by 87.4% 42. A complication of Charite disc prosthesis is the anterior and posterior placement of prosthesis. Due to angulation, slippage towards anterior is observed mostly at fifth and first sacral (L5-S1) vertebral levels. Slippage of prosthesis is a serious complication, which causes vascular or neural injury.

To reduce this complication, the disc surface in contact with corpus is coated by a material which allows a fusion with the bone tissue, and equipped as to be fixed with end plaques. During the application of disc prosthesis, vascular, urethral, and sympathetic chain injuries were reported.<sup>(43)</sup> Retrograde ejaculation and erectile dysfunction could also be seen. As in all types of vertebral surgeries, there is a neural injury risk in this surgery as well. There are complications reported such as adjacent segment degeneration, facet joint arthrosis, painful facet syndrome, hematoma, spontaneous fusion in the prosthesis, hyperlordosis at the level of surgery site, subsidence of prosthesis into corpus, and the restriction of range of movement in case the prosthesis is placed more anterior instead of at instantaneous axis of rotation (IAR)<sup>(43)</sup>. When clinically unsuccessful TDR surgeries are examined, a collapse by 67% was observed in these patients. In patients with lower bone density, this complication is much frequently recorded.

In fusion systems, bone mass placed in-between corpuses does not allow this complication (subsidence).

Rate of this complication of collapse caused by total disc replacement could

also differ depending on the shape of prosthesis and surgical technique. Preservation of cartilage end plates, the fact of them not being used in osteoporotic patients and that the diameter of prosthesis is not smaller than corpus diameter at the level of prosthesis application reduce the rate of collapse<sup>(44)</sup>.

#### 4.b. ProDisc-L Total Disk Replacement System

It is firstly used in 1990. ProDisc-L total disk replacement system consists of two metal end plates and the polyethylene joint surface attached to the inferior metal plate (Figure 17).

##### Indications

- It can be applied in Grade I or II degenerative disc disease between the lumbar third and first sacral (L3-S1) vertebral levels,
- In patients who do not respond to conservative treatment longer than 6 months,
- In patients with Oswestry score above 20/50 (40%),
- In the presence of disc height loss more than 2 mm, in slips over 3 mm or angulations above 5°, which do not exceed Grade I,
- In case of the detection of annular thickening, or degeneration in disc tissue in MRI,
- In patients who develop vacuum degeneration.



Figure 17: ProDisc-L disc prosthesis.

### Contraindications

- In the presence of disc degeneration over Grade II
- In case of lumbar fusion surgery undergone,
- In degenerative facet disease,
- In spinal stenosis and spondylolysis,
- In degenerative spondylolisthesis over Grade I,
- In unidentified leg pain,
- In metabolic bone disease and osteoporosis,
- In autoimmune diseases such as rheumatoid arthritis,
- If there is a pregnancy to be expected within three years,
- If body mass index is above 40,
- If steroids are used,
- In active infections,
- In systemic diseases and malignancies.

It ensures physiological lordosis by keeping the axial rotation axis at a site close to the posterior segment of the disc, that is at its original location, while maintaining physiological range of movement. Advantages of ProDisc-L include: preservation of facet joint function by allowing for the movement within physiological limits, application in more than one disc levels, and tight adherence to corpus surfaces.

Its disadvantages include: difficulty in removing prosthesis if revision surgery is required, few number of patients with a follow-up period above 10 years, the possibility of producing polyethylene debris, and especially chance of vertebral fracture in slightly built patients<sup>(45)</sup>.

### 4.c. MobiDisc Disc Prosthesis

It is prosthesis which includes two vertebral end plates and one polyethylene joint surface. End plates consisted of a cobalt-chrome alloy wrapped by a hydroxyapatite-coated cellular titanium. It is a second-generation prosthesis developed after ProDisc-L. Instantaneous rotation axis of prosthesis fits to the physiological axis of vertebra. It allows translation during rotation. Varied height options of polyethylene joint core are compatible with disc spaces in different widths, and various forms of prosthesis with an adjusted lor-

dosis of 0.5° and 10° are consistent with lordosis (Figure 18).

It is firstly used in 2003, and by biomechanical tests the prosthesis has been demonstrated to resist to 15 million cycles.

Superiority of MobiDisc prosthesis over other disc prostheses: simple operation technique, compatibility with the patient using various angles for lordosis, and allowance for translation. Its disadvantage is that it could not be applied in facet arthropathy and instability<sup>(46)</sup>.

## 5. Nucleus Replacement Systems

### 5.a. PDN-Solo and HydraFlex Nucleus Replacement System

Nucleus replacement systems are designed to perform the load transfer in disc tissue in presence of physiological conditions by imitating the structure of a normal nucleus pulposus.

Prosthetic disc nucleus (PDN) system started to take place in the clinical application of spinal disc arthropathy in 1996. This device, which has been developed by Charles D. Ray, is made up of a hydrogel substance absorbing fluid and has shown a diffusive characteristic when implanted<sup>(47)</sup>. PDN device consists of a hydrogel substance surrounded by




Figure 18: MobiDisc disc prosthesis.

a polyethylene sheath. Thus, it undertakes the tampon function of the normal disc, and also maintains disc height and flexibility (Figure 19).

It is applied in degenerative disc disease between second lumbar and first sacral (L2-S1) vertebral levels for a single level in adult patients aged between 25-75. Generally, these patients apply to the physician with complaints of lumbar and/or leg pain.

It is required that the symptoms of patients endured for at least 6 months and that they should not



**Figure 19:** Prosthetic disc nucleus (PDN) system.

have benefited from conservative and physical therapy. Contraindications for PDN are severe central spinal, foraminal and lateral recess stenoses. Moreover, it is also contraindicated for dynamic degenerative spondylolistheses over Grade I, lytic spondylolisthesis, degenerated or broken facet joints, Schmorl nodules at affected level, disc heights below 6 mm, osteoporosis or osteomalacia, spinal tumors, vertebral tumors, surgeries undergone at the application or adjacent site, active infection, severe obesity, and at disc level in the presence of congenital anomalies.

The greatest advantage of PDN system is that it can be performed through a small posterolateral annulotomy. Other application techniques include anterior retroperitoneal and anterolateral transposoatic modalities. If anterior retroperitoneal modality is to be applied, flap lifted up in anterolateral annulus should be sutured in place later on. In this method,

nucleus is typically evacuated almost entirely. During this procedure, end plates and posterior annulus should not be damaged. Edema formation and fracture of damaged cartilage end plates may lead to the fact that prosthesis is being embedded into end plates and corpus, and causes pain. Posterior annulus damage, on the other hand, results in the slip of prosthesis into canal. For application, following the evacuation of nucleus, height of the disc space is measured, and the prosthesis is placed by a slight distraction in lordosis position. In this procedure performed under fluoroscopy, caution should be exercised to place the prosthesis into 1/3 posterior segment of the disc space. Then, rehydration of prosthesis is ensured by saline infusion. Greatest disadvantage of PDN-Solo and HydraFlex systems is that they could glide and change position easily. To reduce the rate of this complication, it is required to comply with the patient selection criteria, pay attention to the surgical technique and to wear a supportive corset in postoperative period during the adaptation period of prosthesis (approximately 6 weeks).

Another disadvantage is the reconfiguration of end plates depending on the pressure by prosthesis. This reconfiguration, if excessive, and occurrence of disc height loss cause pain. Also in some patients, fracture of cartilage end plates could be seen<sup>(44,48)</sup>. Unsuccessful results have been obtained in its clinical studies, thus its usage remains limited in our day.

### 5.b. NeuDisc Nucleus Replacement System

Amount of tissue removed out during discectomy determines the severity of postoperative degeneration. Although no definite consensus is available about this issue, degeneration rate is lower if nucleus and annulus are preserved as much as possible<sup>(49)</sup>. Nucleus replacement systems are developed for preserving the height of disc space, reestablishing the annulus tension, and to keep the load-bearing, shock absorbing and vibration enduring capabilities of vertebra. Objective of these systems is to provide a painless life for the patient during the postoperative period.

Discogenic pain is eliminated by restoring the disc function following nucleotomy. NeuDisc produced for this purpose carries out the physiological function of nucleus pulposus (Figure 20). Hydrogel structure of NeuDisc system distributes the axial loading on the disc by imitating the osmotic structure of nucleus pulposus. Dacron sheath surrounding the hydrogel nucleus provides an adequate toughness for prosthesis, but at the same time it is soft enough not to break the cartilage end plates. Following its application through a small anulotomy, it is expanded by hydration and fills in the disc space. In biomechanical tests, it resisted to compression, axial torsion, flexion, extension, lateral flexion for 30 million cycles.

This rate corresponds to approximately 30 years of device life. It can be applied following total nucleotomy and at L2-S1 level, and it is required that no more loss of disc height than 50% of normally accepted should have occurred at the level of application site. Technically, it is placed through an annulus fenestration under the endoscopic guidance after total nucleotomy. There are some advantages of nucleus replacement system versus total disc replacement system. First of all, preservation of the annular tissue also ensures the preservation of disc function.

It can only be performed through a small incision in annulus by using minimal invasive surgery. No instrumentation is required because implant is not attached to vertebra. Surgery time is quite shorter compared to that of the total disc replacement surgery. Slip of the implant and its pressure on the neural tissue is possible; however, it does not cause permanent damage on neural tissue due to soft characteristics and small size of the implant. If implant complication or incompatibility develops, it is possible to remove it by anterior modality and switch to the procedure of total disc prosthesis, or to resort to fusion surgery. Main disadvantage of these systems is that they should be applied at an early period or at a stage of disc degeneration, which is not quite progressed, because annulus should have been preserved. It is inconvenient to apply them in degenerated annulus or in presence of loss of disc height. Extending a collapsed disc height causes pain due

to the loading on facets<sup>(50)</sup>. There are no long-term clinical outcomes.

### 5.c. Nubac Disc Arthroplasty

As is the case for other total arthroplasty systems, *Nubac disc arthroplasty system* is especially indicated in the surgery for degenerative disc disease where total discectomy is performed. Similar to other systems, a minimum 5 mm of disc height is required for the application this system.




Figure 20: NeuDisc disc prosthesis.

Forcing the discs with more than 5 mm reduced height in order to extend them both forces the facet joints developed arthrosis and causes the device to be embedded into corpus by leading to an excessive contact stress between the device and cartilage end plates as the result of axial loading. Therefore, Nubac disc arthroplasty system is indicated in the early or intermediary degenerative disc disease.

Compared to other total disk arthroplasty systems, it is said that Nubac system, which can also be applied using a less invasive approach, can be used to prevent discogenic lumbar pain following discectomy thanks to this feature.

Specified patient group also includes the patients, who applied to the physician only with leg complaint and developed no lumbar pain. Since other total arthroplasty techniques require invasive surgery, these are not recommended for this patient group. Nubac composed of polyetheretherketone (PEEK)

is designed as a “ball and socket” mechanism like other arthroplasty systems. Due to its structure, it does not restrict physiological, rotational movements, and applies no excessive loading on cartilage end plates.

Since Nubac disc prosthesis will be supported by annulus and other ligaments, it is essential that these tissues should be preserved during discectomy (Figure 21). It is advantageous for this prosthesis that it is applicable by posterior, lateral or retroperitoneal approaches. If posterior approach will be applied, the facet joint should be preserved as much as possible. It can be applied through lateral retroperitoneal, transpoatic approach at lumbar fourth and fifth (L4-L5) vertebral levels. This approach is regarded as less exposed to complications versus conventional anterior intraabdominal approach. Nubac system is applied through an annular opening of 6x6 mm. End plates should not be damaged during discectomy. Caution should be exercised to the lordotic angle when prosthesis is placed under fluoroscopy. Since Nubac could not adhere to end plates, annular opening should be not so large to prevent postoperative prosthesis dislocation. Also, the fact that nucleus pulposus is not evacuated completely increases the occurrence of this complication by pushing the prosthesis. Preservation of annulus as much as possible holds the prosthesis in place. In osteoporosis or Schmorl nodule, the rate of prosthesis being embedded into corpus increases.

Advantages of Nubac compared to total disk prosthesis or fusion surgery are: attachment by a less invasive and risky surgical application, being radiolucent, less surgery time, possibility to be performed

through anterior, posterior, lateral approaches, not causing facet degeneration and imbalance between anterior column and facet joints by establishing a physiological loading balance.

Disadvantages versus total disc prosthesis or fusion surgery: more disposal risk, inability to apply in advanced degenerative disc disease and the higher rate of being embedded into corpus. Disadvantages versus other nucleus replacement systems: having no shock absorbing feature and not settling completely at the space due to expansion.

Advantages versus these systems are less risk of dislocation, more endurance and biocompatibility, easier application, and providing more physiological load distribution during flexion and extension.

#### 5.d. BioDisc Nucleus Replacement System

It is a replacement system, which is used to generate in-situ polymerized hydrogel protein, to fill in the space emerged following the removal of nucleus after discectomy, and to repair annulus. It is suggested that is reduces lumbar pain and instability, which might reveal following discectomy.

It is applied following discectomy procedure, and injected into disc in place of the removed nucleus. It is also considered that it preserves the disc height of the system, the instability of the lumbar movement system, and reduces the rate of recurrent hernia. It is contraindicated for use in recurrent disc hernia surgery, hernia due to spondilolysthesis, infection, loss of height above 60%, and in large annular ruptures. BioDisc composed of protein-based hydrogel biopolymer is injected into a disc space, which is evacuated by a special application apparatus. Poly-

merization starting within 20-30 seconds ensures that the substance injected in place of nucleus integrates with the remaining disc tissue.

Patient group eligible for BioDisc nucleus replacement system include those of: diagnosed by neurological examination and CT or MRI, having predominant leg pain compared to lumbar pain, not benefited from medical treatment and physical therapy for at least 6 weeks. BioDisc is injected into the space, which emerges following the routine discectomy surgery performed without causing any damage




Figure 21: Nubac disc prosthesis.



in cartilage end plates and annulus, by preserving surrounding tissues and especially the neural tissue. After hardening, it is ensured that no pressure on root and dura is present, BioDisc fragments effusing from the annular rupture are cleaned, and the procedure is concluded. Its applicability makes BioDisc advantageous versus other systems<sup>(52)</sup>

---

## 6. Conclusion

A general criticism for dynamic systems is that the material endurance will diminish and composite material fatigue will reveal, because no fusion will occur in the long-term follow-ups of these systems. There are also concerns about that daily physical activities may cause complications such as screw loosening, implant breakage on these systems by generating cyclic loadings. In biomechanical studies, however,

it is demonstrated that these systems can resist to a 10-year stress at least in normal daily activity<sup>(23)</sup>.

It is also suggested as an other disadvantage that costs of dynamic systems are much more compared to fusion systems<sup>53</sup>. However, especially shorter surgery times of dynamic system implantation surgeries, which form posterior tension band, compared to fusion surgeries, no acquisition of fusion autograft and no usage of allograft in these surgeries, less frequently recorded complications such as pain at graft site in these surgeries, and shorter length of stay prove this criticism to be wrong.

To sum up, developments in fields of medicine and engineering change the balance between rigid-mobile systems in vertebral surgery in favor of mobile systems.

## References

- 1- Davis JR: Dynesys dynamic stabilisation system. In Yue JJ, Bertagnoli R, McAfee PC, An HS (eds): Motion preservation surgery of the spine saunders. Elsevier, 2008, pp 465-471.
- 2- Cakir B, Ulmar B, Koepp H, et al: Posterior dynamic stabilization as an alternative for instrumented fusion in the treatment of degenerative lumbar instability with spinal stenosis. *Z Orthop* 141:418-424, 2003.
- 3- Putzier M, Schneider SV, Funk J, Perka C: Application of a dynamic pedicle screw system for lumbar segmental degenerations comparison of clinical and radiological results for different indications. *Z Orthop Ihre Grenzgeb* 142:166-173, 2004.
- 4- Sengupta DK: Dynamic stabilization devices in the treatment of low back pain. *Neurology India* 53(4):466-474, 2005.
- 5- Bertagnoli R: Multilevel lumbar disc arthroplasty. In Yue JJ, Bertagnoli R, McAfee PC, An HS (eds): Motion preservation surgery of the spine saunders. Elsevier, 2008, pp 725-734.
- 6- Grob D, Benini A, Junge A, Mannion AF: Clinical experience with the Dynesys semirigid fixation system for the lumbar spine. *Spine* 30(3):324-331, 2005.
- 7- Mulholland RC, Sengupta DK: Rationale, principles and experimental evaluation of the concept of soft stabilisation. *Eur Spine J (Suppl 2)* 11:198-201, 2002.
- 8- Nockels RP: Dynamic stabilisation in the surgical management of painful lumbar spinal disorders. *Spine* 30(165):S68-S72, 2005.
- 9- McNally DS, Adams MA: Internal intervertebral disc mechanics as revealed by stress profilometry. *Spine* 17:66-73, 1992.
- 10- Gibson JN, et al: The Cochrane review of surgery for lumbar disc prolapse and degenerative lumbar spondylosis. *Spine* 24:1820-1832, 1999.
- 11- Fritzell P, et al: Chronic low back pain and fusion: a comparison of three surgical techniques: a prospective multicenter randomized study from the Swedish lumbar spine study group. *Spine* 27:1131-1142, 2002.
- 12- Boos N, et al: Pedicle screw fixation in spinal disorders: a European view. *Eur Spine J* 6:2-18, 1997.
- 13- Dipp JM, Flores R, Rodrigues G: The Percu Dyn system. In Yue JJ, Bertagnoli R, McAfee PC, An HS (eds): Motion preservation surgery of the spine saunders. Elsevier, 2008, pp 511-515.
- 14- Kothari MVL, Mehta L, Natarajan M, Kothari VM. Spine revisited: Principles and parlance redefined. *Neurol India* 53:397-398, 2005.
- 15- Cakir B, Richter M, Huch K, et al: Dynamic stabilisation of the lumbar spine. *Orthopedics* 29:716-722, 2006.
- 16- Wilke HJ, Heuer F, Schmidt H: Prospective design delineation and subsequent in vitro evaluation of a new posterior dynamic stabilization system. *Spine* 34(3):255-261, 2009.
- 17- Hilibrand AS, et al: Adjacent segment degeneration and adjacent segment disease: The consequences of spinal fusion? *Spine J* 4:190S-1904S, 2004.
- 18- Park P, et al: Adjacent segment disease after lumbar or lumbosacral fusion: Review of the literature. *Spine* 29:1938-1944, 2004.
- 19- Schnake KJ, et al: Dynamic stabilization in addition to decompression for lumbar spinal stenosis with degenerative spondylolisthesis. *Spine* 31:442-449, 2006.
- 20- Ghiselli G, et al: Adjacent segment degeneration in the lumbar spine. *J Bone Joint Surg Am* 86-A:1497-503, 2004.
- 21- Weinhoffer SL, et al: Intradiscal pressure measurements above an instrumented fusion: A cadaveric study. *Spine* 20:526-531, 1995.
- 22- Lee CK, et al: Lumbosacral spinal fusion: A biomechanical study. *Spine* 9:574-581, 1984.
- 23- Stempel A: Cosmic: Dynamic stabilization of the degenerated lumbar spine. In Yue JJ, Bertagnoli R, McAfee PC, An HS (eds): Motion preservation surgery of the spine saunders. Elsevier, 2008, pp 490-499.
- 24- McAfee PC: Interbody fusion cages in reconstructive operations on the spine. *J Bone Joint Surg Am* 81:859-880, 1999.
- 25- Whitecloud TS, Castro FP, Brinker MR, et al: Degenerative conditions of the lumbar spine treated with intervertebral titanium cages and posterior instrumentation for circumferential fusion. *J Spinal Disorders* 11:479-486, 1998.
- 26- Polikeit A, Ferguson SJ, Nolte LP: The importance of the endplate for interbody cages in the lumbar spine. *Eur Spine J* 12:556-561, 2003.
- 27- Graf H: Lumbar instability; surgical treatment without fusion. *Rachis* 412:123-137, 1992.
- 28- Gardner A, Pande KC: Graf ligamentoplasty: A 7 year follow up. *Eur Spine J* 11:157-163, 2002.
- 29- Konno S, Kikuchi S: Prospective study of surgical treatment of degenerative spondylolisthesis: com-

- parison between decompression alone and decompression with Graf system stabilisation. *Spine* 25:1533-1537, 2000.
- 30- Brechbuhler D, et al: Surgical results after soft system stabilization of the lumbar spine in degenerative disc disease-long-term results. *Acta Neurochir (Wien)* 140:521-525, 1998.
  - 31- Legaye J, et al: Supple intervertebral stabilization according to Graf. Evaluation of its use and technical approach. *Acta Orthop Belg* 60:393-401,1994.
  - 32- Grevitt MP, et al: The Graf stabilisation system: early results in 50 patients. *Eur Spine J* 4:169-175, 1995.
  - 33- Bono CM, Kadaba M, Vaccaro AR: Posterior pedicle fixation based dynamic stabilization devices for the treatment of degenerative diseases of the lumbar spine. *J Spinal Disord Tech* 22(5):376-383, 2009.
  - 34- Stoll TM, et al: The dynamic neutralization system for the spine: A multicenter study of a novel non-fusion system. *Eur Spine Journal* 11:170-178, 2002.
  - 35- Schmoelz W, et al: Dynamic stabilization of the lumbar spine and its effects on adjacent segments: An in vitro experiment. *J Spinal Disord Tech* 16(4):418-423, 2003.
  - 36- Mardjetko SM, Connolly PJ, Shott S: Degenerative lumbar spondylolisthesis. *Spine* 19:S2256-S2265, 1994.
  - 37- Turner JA, Ersek M, Herron L: Patient outcomes after lumbar spinal fusions. *JAMA* 268:907-911, 1992.
  - 38- Schmoelz W, et al: Nonfusion instrumentation of the lumbar spine with a hinged pedicle screw rod system: An in vitro experiment. *Eur Spine J* 18(10):1478-1485, 2009.
  - 39- Stempel A, Moosmann D, Stoss C, Martin A: Stabilisation of the degenerated lumbar spine in the nonfusion technique with cosmic posterior dynamic system. *WSJ* 1(1):40-47, 2006.
  - 40- Bozküflü H, Senoğlu M, Baek S, Sawa AG, Ozer AF, Sonntag VK, Crawford NR: Dynamic lumbar pedicle screw-rod stabilization: in vitro biomechanical comparison with standard rigid pedicle screw-rod stabilization. *J Neurosurg Spine* 12(2):183-189, February 2010.
  - 41- Blumenthal SL, McAfee PC, Guyer RD: A prospective multicenter FDA-IDE study of lumbar total disc replacement with the Charité artificial disc vs lumbar fusion: Part I: Evaluation of clinical outcomes. *Spine* 30:1565-1575, 2005.
  - 42- Putzier M, Funk JF, Schneider SV, et al: Charité total disc replacement-clinical and radiographical results after an average follow-up of 17 years. *Eur Spine J* 15:183-195, 2006.
  - 43- Blumenthal SL, Ohnmeiss DD: Charité artificial disc. In Yue JJ, Bertagnoli R, McAfee PC, An HS (eds): *Motion preservation surgery of the spine saunders*. Elsevier, 2008, pp 309-317.
  - 44- Huang RC, Wright TM, Panjabi MM, Lipman JD: Biomechanics of nonfusion implants. *Orthop Clin N Am* 36:271-280, 2005.
  - 45- Delamarter RB, Pradhan BB: ProDisc-L total disc replacement. In Yue JJ, Bertagnoli R, McAfee PC, An HS (eds): *Motion preservation surgery of the spine saunders*. Elsevier 2008, pp 318-325.
  - 46- Steib JP, Aubourg L, Beaurain J: MobiDisc disc prosthesis. In Yue JJ, Bertagnoli R, McAfee PC, An HS (eds): *Motion preservation surgery of the spine saunders*. Elsevier, 2008, pp 326-329.
  - 47- Jin D, Qu D, Zhao L, Chen J, Jiang J: Prosthetic disc nucleus (PDN) replacement for lumbar disc herniation: Preliminary report with six months follow-up. *J Spinal Disord Tech* 16(4):331-337, 2003.
  - 48- Davis RJ: PDN-Solo and hydraflex nucleus replacement system. In Yue JJ, Bertagnoli R, McAfee PC, An HS (eds): *Motion preservation surgery of the spine saunders*. Elsevier, 2008, pp 407-410.
  - 49- Brinkman P, Grootenbore H: Change of disc height, radial disc bulge, and intradiscal pressure from discectomy. *Spine* 16:641- 646,1991.
  - 50- Bao Q, Songer MN, Pimenta L: NUBAC Disc Arthroplasty. In Yue JJ, Bertagnoli R, McAfee PC, An HS (eds): *Motion preservation surgery of the spine saunders*. Elsevier 2008, pp 442-451
  - 51- Wardlaw D: BioDisc nucleus pulposus replacement. In Yue JJ, Bertagnoli R, McAfee PC, An HS (eds): *Motion preservation surgery of the spine saunders*. Elsevier 2008, pp 431-434.
  - 52- Würigler-Hauri, CC, Kalbarczyk A, Wiesli M, et al: Dynamic neutralisation of the lumbar spine after microsurgical decompression in acquired lumbar spinal stenosis and segmental instability. *Spine* 33(3):E66-E72, 2008.
  - 53- Yeung AT, Prewett A, Yue JJ: NeuDisc artificial lumbar nucleus replacement. In Yue JJ, Bertagnoli R, McAfee PC, An HS (eds): *Motion preservation surgery of the spine saunders*. Elsevier 2008, pp 411-416.