

22

CHRONIC INSTABILITY AND FUSION SURGERY IN LUMBAR DEGENERATIVE DISC DISEASE

Mehdi SASANI M.D., Bilgehan SOLMAZ M.D., Mustafa GUVEN M.D.

Discogenic pain is closely related to degenerative disc disease (DDD).

The source of low back pain is internal disruption of the lumbar intervertebral disc.

Chronic segmental instability, mechanical irritation of sensory nociceptive terminals and biochemically activation of inflammatory mediators are thought as causes of discogenic low back pain.

Acute and chronic spinal instability are known as important causes of low back pain.

Chronic instability is usually associated with degenerative disease or the long term sequale of trauma, tumor or infection. Chronic instability is accepted as the main problem in lumbar DDD but its clinical and radiological features are poorly defined.

The lumbar instability can be divided into two groups as a clinical (functional) and biomechanical (radiographic) instability.

Clinical instability is defined that the degeneration of disc is caused to pain depending on the instability. However there is no radiological findings as angulation or certain degree of listhesis. Degeneration is the disruption of the stable structure of disc which leads to the back pain.

The definition of **biomechanical instability** is used when the disc degeneration, translation and angulation are found on radiologic studies of patients.

If there is an intervertebral angulation greater than 15° and a vertebral translation greater than 4 mm on dynamic radiographs, an instability should be thought.

1) Clinical findings and differential diagnosis

The main clinical manifestation of lumbar degenerative disc disease is low back pain.

Pathologies that cause to low back pain must be known and similar clinical findings should be carefully assessed.

The correct diagnosis and choosing the right treatment can be made by this means.

Discogenic Pain

The discogenic low back pain is occurred or increased by flexion position. Discogenic pain is decreased by lying on the bed when spine is not compressed. Severe locked style low back pain occurs while transition from bending forward to standing position. There may be pain going into back of thighs or buttocks.

The differential diagnosis of low back pain; facet joint, hip and sacroiliac joints, muscle-ligament, gluteus medius muscle and intervertebral disc can be the source of pain.

2) Indications for spinal fusion in degenerative disc disease

If spontaneous fusion is not demonstrated on radiologic studies of patients with lumbar instability, fusion surgery may be considered for patients with biomechanically instability.

After the decompression is made for neural tissue in spondylolisthesis surgery, abnormal mobility is

increased by surgical trauma. For this reason spinal instrumentation and fusion should be performed.

If iatrogenic instability is made intraoperatively, fusion should be made.

If there is severe low back pain in any chronic degenerative disc disease, fusion must be considered for the prevention of abnormal mobility of the disc. Spinal instrumentation and fusion is known as a classical preventive method for recurrence disc herniation after the discectomy in the same motion segment that is slack.

Fusion may be applied to patient with severe mechanical back pain from one or more lumbar segment even if there is not radiculopathy findings.

When facetectomy is performed for severe facet hypertrophy resulting in spinal stenosis, degenerative disc disease or discectomy operation, spinal instrumentation and fusion are required.

Fusion is made for patients that has biomechanically instability accompanying the clinical findings. Pathological instability is clearly seen in these patient's radiologic studies.

It is difficult to choose of a patient for fusion surgery in the absence of obvious instability. For this reason diagnostic tests and studies should be made for patient selection as following;

- Character of pain should be examined (type, spreading and localization)

- Conservative treatment approaches should be used at least 6 months but no improvements with this measures.

- MR imaging should be used to determine of the presence of degeneration and to evaluate of the lumbar disc.

- If there is multiple segmental degenerative disc disease, discography should be performed to determine which disc is the pain generator.

3) Treatment options of degenerative disc disease

A treatment decision is made with considering the clinical and radiological findings of patient but treatment options may be contraversial for some patients.

Therefore advantages and disadvantages of treatment options should be clearly discussed with patient.

Treatment options are listed as following:

Conservative (nonsurgical) treatment options include physical therapy, nonsteroidal anti-inflammatory medications, limited activity and treating pain.

Surgical treatment options include fusion surgery and surgery without fusion.

3a) Fusion surgery

Initially fusion was performed without spinal instrumentation but pseudoarthrosis was higher, therefore surgical morbidity was seen often in operated patients.

Restoration of lumbar curve and the reduction of listhesis are not possible with fusion surgery without spinal instrumentation.

If fusion surgery is performed with spinal instrumentation, both fusion rates is increased and correction of lumbar anatomy is provided .

3b) Surgery without fusion

If stabilization surgeries are performed while in motion of waist, pseudoarthrosis is not seen.

Surgical morbidity and mortality rates is decreased because of these surgical operations takes less time, the risk of surgical bleeding is low and adjacent segment disease is observed more less.

In this chapter, fusion surgery from treatment options will be explained.

4) Fusion surgery in lumbar degenerative disc disease

4a) Fusion surgery types in lumbar disc disease

Type of the fusion surgery is denominated according to where the graft is inserted: Anterior interbody fusion (ALIF), posterior interbody fusion (PLIF), transforaminal interbody fusion (TLIF), posterior fusion (lamina, facet joint and transverse process) and combined as anterior and posterior.

4b) Fusion with anterior approach

Intervertebral graft can be inserted by anterior approach (ALIF) or posterior approach (PLIF, TLIF). Each of approaches has advantages and disadvantages according to its (Figure 1). Choice of surgical procedure should be decided according to qualification

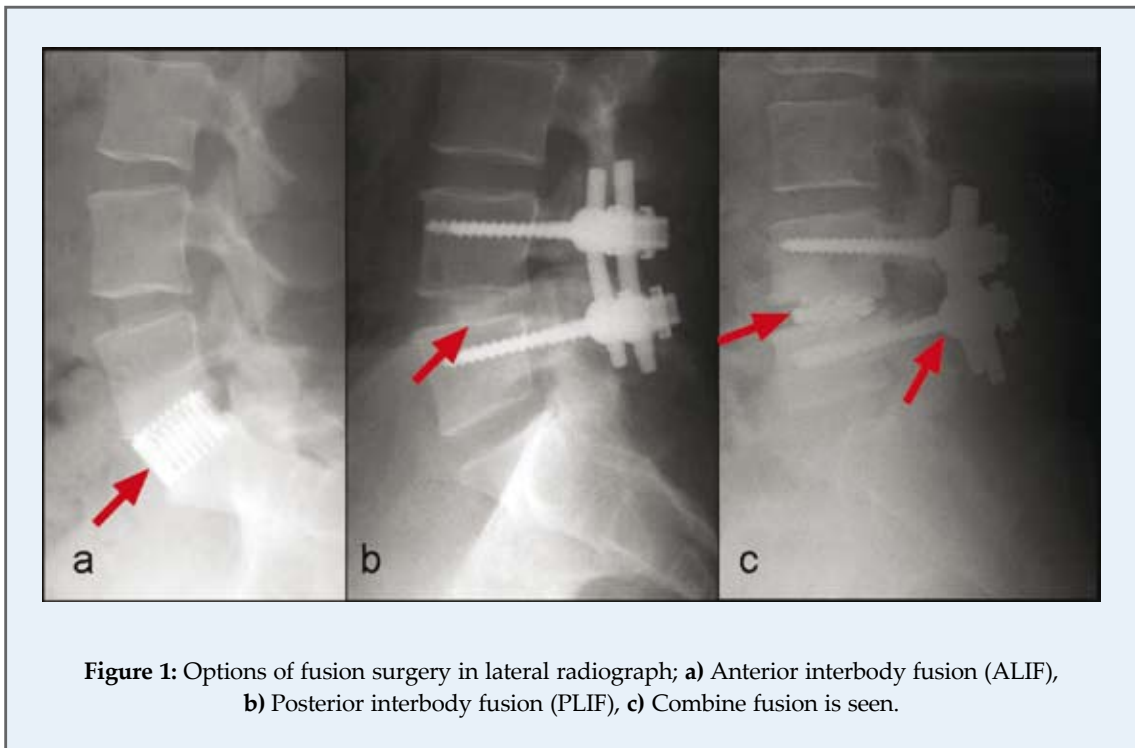


Figure 1: Options of fusion surgery in lateral radiograph; **a)** Anterior interbody fusion (ALIF), **b)** Posterior interbody fusion (PLIF), **c)** Combine fusion is seen.

of operation room, general status of patient and experience of surgeon.

Join with general surgeon can be prevented complications caused by an inexperienced surgeon for anterior approaches.

4c) Combined (anterior and posterior) approaches

The main disadvantage of combined approaches is that two different surgical region is created. Anterior fusion and posterior instrumentation (PLIF and TLIF) is usually possible with posterior approach therefore posterior approach is preferred.

Anterior lumbar interbody fusion provides a wide fusion area after discectomy, but it is must be supported by posterior instrumentation to increase the fusion rate ⁽³⁾.

In the anterior approach when transpedicular instrumentation is considered, a second surgical posterior approach is needed.

Anterior interbody fusion with posterior transpedicular instrumentation increases fusion rates whether the approach is anterior or posterior.

Intervertebral fusion is most appropriate technique as biomechanically for degenerative disc

disease since this is compatible for axial loading of spine and maximal compressive load.

Posterior approaches (PLIF, TLIF) should be preferred more than anterior approach because it gives the possibility of fusion of both anterior and posterior vertebral columns in the same session.

Posterior approach techniques known as PLIF and TLIF, have several advantages and disadvantages:

Technically TLIF requires less dural sac and nerve root retraction compared to PLIF,

and this decreases possible dural, neural and also anatomical damage because facet and lamina of the other side is protected.

However, the advantage of PLIF techniques is that a wide fusion area is created besides an effective compression ^(4,5).

In posterior approach; neural element damage, due to retraction endoneural fibrosis and chronic radiculopathy can occur. Also pseudoarthrosis may develop, and an excessive instability may be observed postoperatively after posterior element decompression.

5) Evaluation of lumbar fusion

Computerize tomography (CT), dynamic and direct radiography are used in the assessment of lumbar fusion (Figure 2a). The resorption of bone graft, hypodensity at the vertebral junction and excessive bone sclerosis are defined as pseudoarthrosis.

Detection of motion at the site of fusion with the dynamic radiography should be thought as failure of fusion and pseudoarthrosis. Because the formation of bone fusion takes at least three months and the radiological confirmation takes more long time, the control radiography should be taken at least within four months considering the age of the patient, antiinflammatory medications, smoking or accompanying systemic disease.

Additionally any hardware problems as screw breakage, relaxation and rod stripping are shown with CT and radiography.

In case of pseudoarthrosis development, the screws inside the bone tissue mobilize and begins to create a space around them. This is observed as a lucent sclerotic halo and a hypodens area on CT and an direct radiography (Figure 2b).

MRI is known as not to be good as CT for imaging of bone structures and especially fusion, also metal artifacts caused by screws and intervertebral cages significantly reduce image quality. Therefore MR images can not give detailed information about fusion.

The radiological evaluation of fusion is shown in table 1⁽¹⁾. According to these results, rate of misplacement

of pedicle screw is 2-5%, and the rate of screw breakage or relaxation is %2-6⁽¹⁾.

The rate of solid fusion in fusion operation with instrumentation is reported to be 90 %⁽⁵⁻⁶⁾.

Severe low back pain can be seen in patients with chronic instability caused by lumbar degenerative disc disease. In these patients, as previously mentioned, instability cannot be seen on dynamic

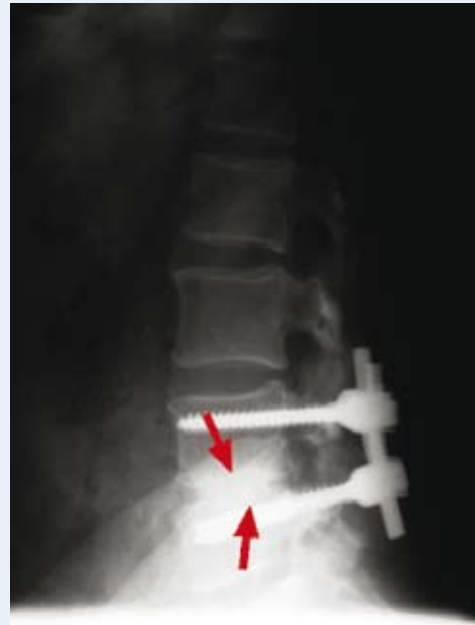

Figure 2: b) Quality and continuity of fusion are seen in direct lumbar radiography

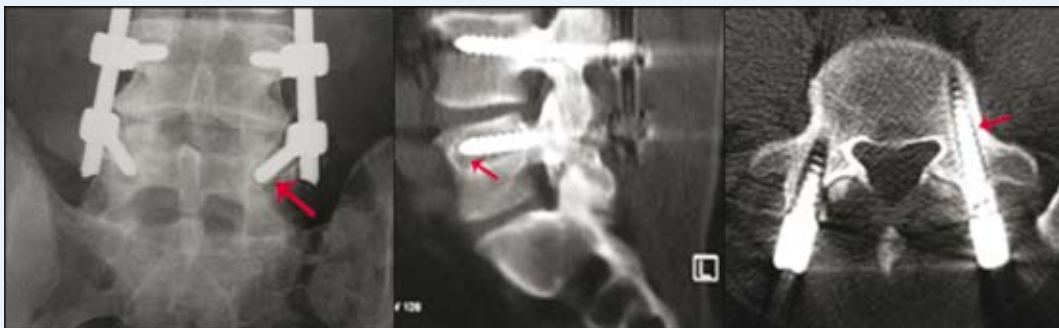


Figure 2: a) In direct radiograph, sagittal and axial CT radiolucent zones are seen around the screw that is depend on relaxation of screw.

Table 1: Evaluation of anterior and posterior fusion⁽¹⁾.

Grade	Fusion	Anterior	Posterior
1	Certain	Remodelling and transpedicular fusion	Bilateral solid trabeculated transverse processes and facet fusion
2	Probable	Graft is stable, no evidence of remodelling or fusion, radiolucency is absent in corpus.	A thick fusion mass on one side, demonstration of fusion is difficult on other side.
3	Unprobable	Graft is stable but radiolucency on the upper or lower side of graft.	The suspicions of lucency or defect in the fusion mass
4	No fusion	There is definitely no fusion, bone graft is reabsorbed and collapsed	-
5	can not be evaluated	-	-

radiography but the absence of this radiologic finding does not mean the absence of instability. This concept of “invisible instability” or previously stated “clinical instability”, was named by Tsuji⁽⁷⁾.

According to Bridwell⁽⁸⁾, vertebral translation is seen in nearly half of patients with the lumbar degenerative spondylolisthesis but it does not progress.

Whether only spinal fusion was sufficient or not for patients with slippage and especially the necessity of instrumentation in terms of pseudarthrosis was discussed in literature^(9,10). In these patients, pain is observed to diminish significantly, especially in vertical and standing position in the back and lower limbs⁽¹¹⁾. Some researchers reported, the fusion rate of patients with rigid transpedicular instrumentation was more than the fusion rate of patients with only intervertebral fusion⁽³⁾.

A lot of studies has shown that, if anterior fusion (TLIF, PLIF) is performed via posterior approach combined with transpedicular instrumentation, fusion rates and clinical success are increased.

According to one study, the clinical success rate of patients who underwent uninstrumented fusion is 72,4%, fusion rate is 82,8%; the clinical success rate for patients who underwent instrumented fusion is 82,1%, and fusion rate is 92,8 %⁽¹²⁾.

Since fusion surgeries are the oldest method that is still used for treatment of degenerative disc disease, many clinical and experimental studies was made. For this reason, spinal fusion is accepted as the “gold standard”.

Nowadays dynamic stabilization concept is emerged as a new approach for treatment of patients with chronic, especially clinical instability^(16,17).

As the clinical results of success and failures of dynamic stabilization are reported, both surgical technique is developed and more clinical experience is gained.

Graf ligament system are followed by Dynesys system and afterward hinged head pedicle screws have been used for dynamic stabilization^(17,18).

In our country, dynamic stabilization is started with utilization of hinged head screw, and clinical series have been reported⁽¹³⁻¹⁵⁾.

References

- 1- Zileli M: Dejeneratif disk hastalığı. Özer AF, Naderi S (ed): Lomber dejeneratif disk hastalığında füzyonun önemi. Meta Basım Matbaacılık, İzmir, 2003, Bölüm 15, ss 135-154.
- 2- Vaccaro A, Mirkvic S, Bauer RD, Grafin SR: Revision lumbar and cervical degenerative spine surgery: Indications and techniques. In Bridwell KH, Dewald RL (eds): The textbook of spinal surgery. Philadelphia, (2nd edition), Lippincott-Raven Publishers, 1997, pp 1457-1493.
- 3- Zdeblick TA: A prospective randomized study of lumbar fusion preliminary results. Spine 18:983-999, 1993.
- 4- Özkara E, Arslantafl A: Transforaminal lomber interbody füzyon (TLIF). Türk Nöroflirüji Dergisi 19:223-226, 2009.
- 5- Holly LT, Schwender JD, Rouben DP, Foley KT: Minimally invasive transforaminal lumbar interbody fusion: Indications, technique and complications. Neurosurg Focus 20 (3):E6, 2006.
- 6- McAfee PC, Weiland DJ, Carlow JJ: Survivorship analysis of pedicle spinal instrumentation. Spine 16:422-427,1991.
- 7- Tsuji A: Pathological condition and treatment of spinal dysfunction. Nihon Iji Spinho Japan Med J 32:26-41, 1986.
- 8- Bridwell KH, Sedgewick TA, O'Brien MF, et al: The role of fusion and instrumentation in the treatment of degenerative spondylolisthesis with spinal stenosis. J. Spinal Disord 6:461-472, 1993.
- 9- France JC, Yaszemski MJ, Lauerman WC, et al: A randomized prospective study of posterolateral lumbar fusion: Outcomes with and without pedicle screw instrumentation. Spine 24:553-560, 1999.
- 10- Mochida J, Suzuki K, Chiba M: How to stabilize a single level lesion of degenerative lumbar spondylolisthesis. Clin Orthop 368:126-134, 1999.
- 11- Herkowitz HN, Kurz LT: Degenerative lumbar spondylolisthesis with spinal stenosis: A prospective study comparing decompression with decompression and intertransverse process arthrosis. J Bone Joint Surg 73:802-808, 1991.
- 12- Kimura I, Shingu H, Murata M, Hashiguchi H: Lumbar posterolateral fusion alone or with transpedicular instrumentation in L4-L5 degenerative spondylolisthesis. J Spinal Disord 14:301-310, 2001.
- 13- Kaner T, Sasani M, Oktenoglu T, Aydin AL, Ozer AF: Minimum two-year follow-up of cases with recurrent disc herniation treated with microdiscectomy and posterior dynamic transpedicular stabilization. The Open Orthopedics 4:120-125, 2010.
- 14- Ozer AF, Crawford NR, Sasani M, Oktenoglu T, Bozkus H, Kaner T, Aydin S: Dynamic lumbar pedicle screw-rod stabilization: Two year follow-up and comparison with fusion. The Open Orthopedics 4:137-141, 2010.
- 15- Kaner T, Dalbayrak S, Oktenoglu T, Sasani M, Aydin AL, Ozer AF: Comparison of posterior dynamic transpedicular stabilization and posterior rigid transpedicular stabilization with fusion after decompression in the treatment of degenerative spondylolisthesis: A minimum two-year follow-up. Orthopedics 33 (5), May 2010.
- 16- Graf H: Lumbar instability: Surgical treatment without fusion. Rachis 412:123-37, 1992.
- 17- Stempel A, Neckritz A, Mualenaere P, du Toit G: Dynamic versus rigid spinal implants. In Gunzburg R, Szpalski M, (eds): Lumbar spinal stenosis. Philadelphia, Lippincott-Williams and Wilkins, 2000 pp 275-285.
- 18- Dubois G, De Gernay B, Schaerer NS, Fennema P: Dynamic neutralization: A new concept for restabilization of the spine. In Szpalski M, Gunzburg R, Pope MH, (eds). Lumbar segmental instability. Philadelphia, Lippincott Williams and Wilkins, 1999, pp 233-240.